

Cryoablation of Abdominal Wall Desmoid Tumor

Mahmoud A. Ali, MD and Steven Yevich, MD, MPH

ABSTRACT: A 30-year-old woman presented with right abdominal pain. Cross-sectional imaging revealed a 4 x 2-cm desmoid tumor, which increased in size to 5 x 4 cm over the next several months. The patient was subsequently treated with 2 sessions of cryoablation, which resulted in complete tumor response at 1 year. Her treatment course, as well as a review of the related literature, is presented herein.

IO Learning. 2022;10:E16-E19. Epub 2022 July 1.

KEY WORDS: aggressive fibromatosis, cryoablation, desmoid tumor

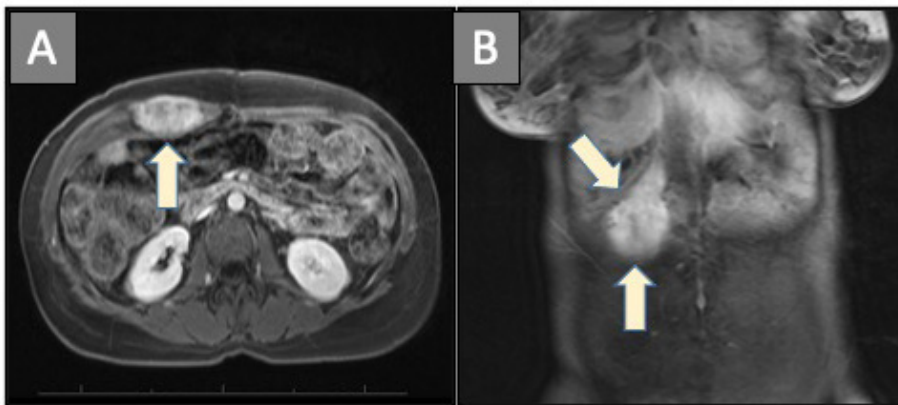


FIGURE 1. (A) Axial and (B) coronal delayed post contrast T1 magnetic resonance imaging demonstrates an irregularly shaped enhancing mass within the right upper rectus abdominis muscle (arrows).

Case Description

A 30-year-old woman presented with right abdominal pain. Cross-sectional imaging demonstrated a 4 x 2-cm enhancing soft-tissue lesion within the right rectus abdominis muscle (**Figure 1**). Core biopsy confirmed desmoid tumor. A multidisciplinary work-up was initiated. The patient was not on birth control or hormonal estrogen therapy. Polyps were not found on colonoscopy, excluding Gardner syndrome.

Given the size and extent of the lesion within the abdominal wall, concerns were raised about the prolonged recovery and potential risks of surgical resection and/or radiation. The patient was managed conservatively. Over the next several months, her abdominal pain worsened and follow-up imaging confirmed that the tumor had enlarged to 5 x 4 cm. Medical management was initiated with sorafenib 400 mg PO daily, which decreased the tumor size, returning it to 4 x 2 cm. After 1 year of treatment, sorafenib was discontinued due

to the development of multiple drug toxicities including abnormal uterine bleeding and fatigue.

Interventional radiology was consulted to evaluate for locoregional treatment. Given the size of the tumor, 2 sessions of percutaneous cryoablation were planned to cover the entire tumor while minimizing risks of abdominal muscle and skin damage.

In the first cryoablation session (**Figure 2**), 3 probes were positioned in the inferior portion of the mass under ultrasound guidance, with each probe spaced approximately 1.5 cm apart. An insufflation needle was advanced into the anterior peritoneal cavity and carbon dioxide gas was injected to separate the underlying bowel from the anterior abdominal wall. Three freeze-thaw cycles were performed under ultrasound and computed tomography guidance.

The patient returned 3 months later for a second cryoablation procedure using similar techniques (**Figure 3**). Treatment was performed on the untreated superior portion of the tumor and additional focused spot treatments were also performed on areas identified as

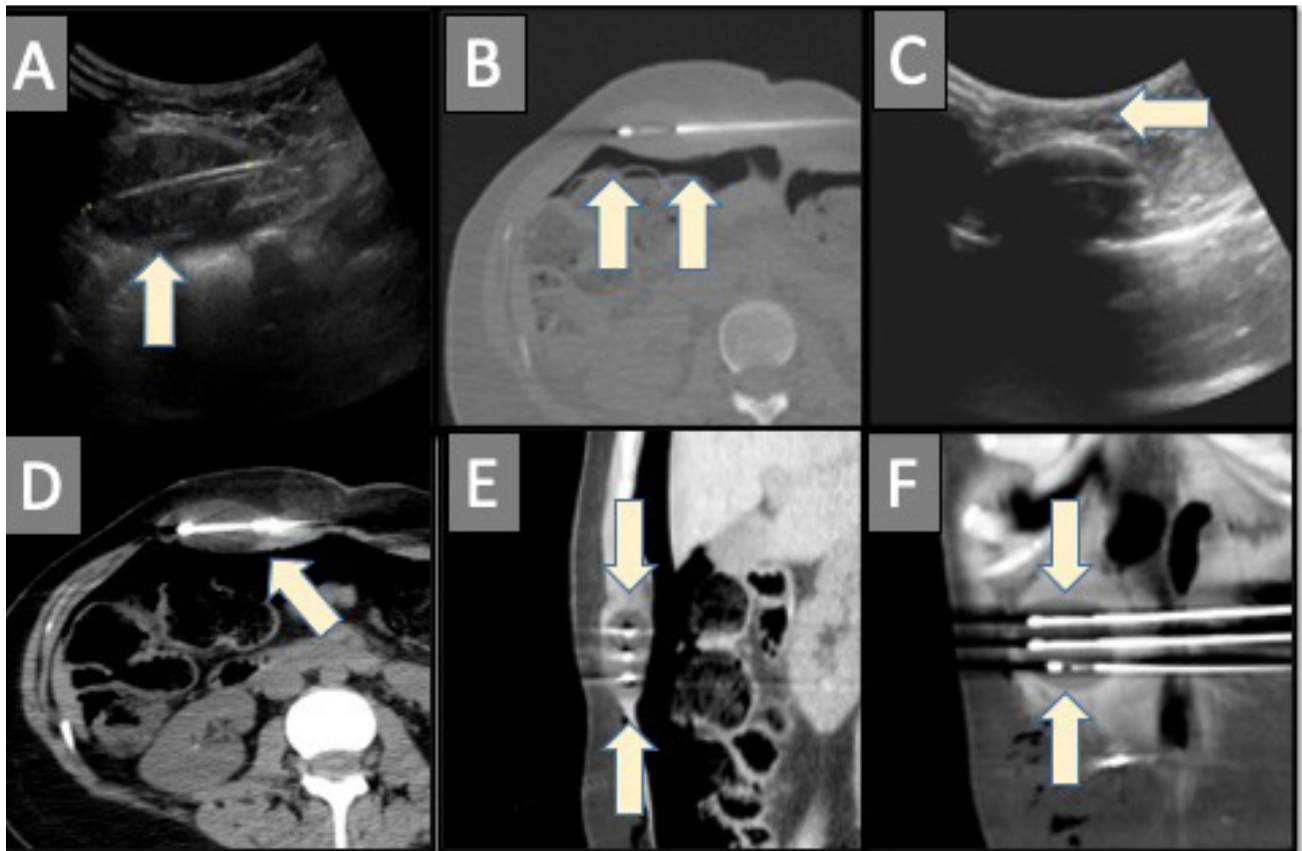


FIGURE 2. (A) First cryoablation of the inferior half of the desmoid with cryoablation probe placement under ultrasound guidance into the lesion (arrow). (B) Injection of carbon dioxide into the peritoneum displaced the underlying bowel (arrows). (C) Cryoablation was performed under frequent ultrasound monitoring to ensure coverage of the inferior portion of the tumor while maintaining adequate separation between the dermis and the most superficial portion of the therapeutic ice ball (arrow). (D, E, F) Computed tomography monitoring was done to confirm coverage of the tumor and persistent separation of underlying bowel by intermittent reinjection of carbon dioxide (arrows).

residual tumor along the inferior margin by intraoperative ultrasound.

After this second and final cryoablation treatment, follow-up abdominal magnetic resonance imaging was performed every 3 months. The 1-year follow-up imaging demonstrated complete tumor response with decreased tumor size without enhancement. The patient's pain had significantly improved and no longer affected her quality of life.

Discussion

Desmoid tumor, also known as aggressive fibromatosis, is a locally invasive, rare mesenchymal tumor that is categorized as an intermediate fibroblastic tumor by the World Health Organization.^{1,2} Desmoid tumors account for 3% of soft-tissue tumors.¹ They

are categorized clinicopathologically into 3 types, with abdominal-wall type the most common.² The development of a desmoid tumor and consequently its pharmacological treatment is dependent on multiple endocrine and hormonal factors (mainly estrogen receptors).³ Despite the local nonmalignant prognosis, desmoid growth can compress adjacent structures and impair quality of life.⁴

Management by National Comprehensive Cancer Network (NCCN) guidelines consists initial of conservative measures for asymptomatic patients.³⁻⁵ In some asymptomatic patients, spontaneous regression has been reported.⁶ For symptomatic patients, a multidisciplinary approach is recommended in order to consider multiple treatment options, including surgical resection, radiation, percutaneous thermal ablation, and chemotherapy.^{5,7}

Surgical resection with wide margin is still regarded the first-line treatment; however, local recurrence is common, with a rate of 8%-31% of cases, even with negative surgical margins.⁸ This high recurrence rate is likely a reflection of the difficulty to distinguish tumor extension along fascial planes.⁹ Radical resection is often not possible due to high morbidity from resection of surrounding structures. In particular locations, such as mesenchymal desmoids, the mortality rate and high recurrence rate can be as high as 78%.¹⁰ External radiation is usually reserved for patients with unresectable tumors or post resection in the event of positive margins or local recurrence.¹¹ Disadvantages of radiation have been reported, with high recurrence rates (mean rate, 25%)^{11,12} and complications including neuropathy and joint contracture.¹³ Chemotherapy agents, including tyrosine kinase inhibitors, vinblastine, and methotrexate, can be administered for unresectable or recurrent desmoids, or as an adjunct to surgery.¹⁴

More recently, new technologies have advanced innovative methods to achieve symptomatic relief and local tumor control. The most common radiology treatments are high-intensity focused ultrasound (HIFU) ablation and percutaneous thermal ablation.^{8,15-17} HIFU is a minimally invasive thermal-ablation technique that focuses ultrasound beams to cause coagulative necrosis. Multiple studies demonstrated the efficiency of HIFU in selected patients with desmoid tumors with curative and palliative intent.¹⁶ Percutaneous thermal ablation encompasses cryoablation, radiofrequency ablation, and microwave ablation. In one study evaluating efficacy of cryoablation after 1-year follow-up, 89% of patients reported improvement, with complete response rate in 36%, partial response rate in 36%, and stable disease in 28%.¹⁷

The minimally invasive nature of percutaneous thermal ablation coupled with advanced imaging techniques provide several advantages over surgical resection.

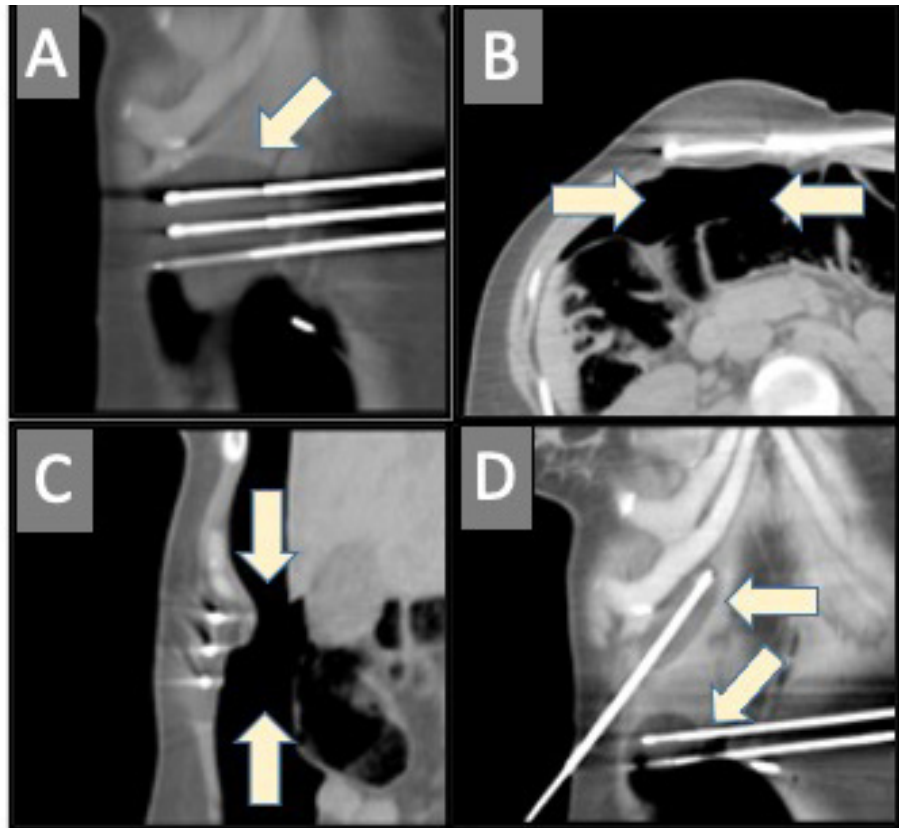


FIGURE 3. (A) Second cryoablation using similar techniques to treat the superior half of the desmoid (arrow). (B, C) Carbon dioxide was again used to displace the bowel from the anterior abdominal wall (arrows). (D) Cryoablation was also performed along the superior and inferior margins (arrows) to ensure complete coverage based on intraprocedural ultrasound evaluation.

Treatments are generally well tolerated. Procedures can be performed with moderate to deep sedation and can be performed as outpatient procedures or with only minimal (1- to 2-night) hospitalization stays. Postprocedure scarring is minimal compared with surgical resection. Complications of ablation are similar to surgery and radiation, and include collateral damage to adjacent structures and recurrence. While the treatment is very effective when performed technically well, evaluation for nearby functional nerves and hollow organs is critical during patient selection. Techniques to isolate the ablation zone from these critical structures, such as presented in the case herein, should be considered to minimize the risk of complications.

While the technology is relatively nascent, the growing body of literature for percutaneous thermal ablation is compelling and bolsters this treatment option in the multidisciplinary management of desmoid tumors.

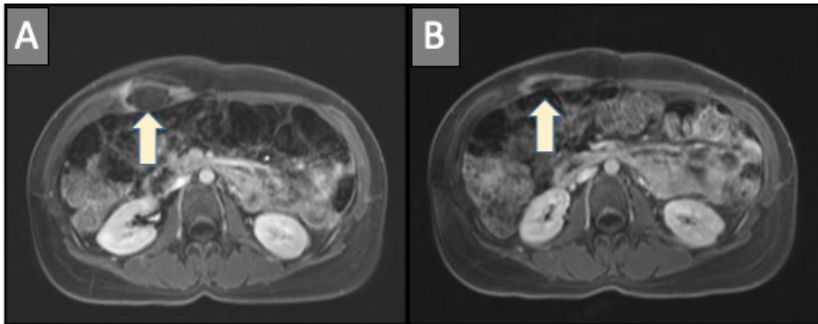


FIGURE 4. Axial delayed post contrast T1 magnetic resonance imaging images. (A) Initial imaging demonstrates peripheral enhancement consistent with post-treatment inflammation (arrow). (B) Final follow-up demonstrates decrease in tumor size and continued resolution of enhancement (arrow).

References

- Otero S, Moskovic EC, Strauss DC, et al. Desmoid-type fibromatosis. *Clin Radiol*. 2015;70(9):1038-1045. doi:10.1016/j.crad.2015.04.015
- Ng E, Tandon AA, Ho BC, Chong BK. Characterising benign fibrous soft-tissue tumours in adults: why is it so difficult and what do we need to know?. *Clin Radiol*. 2015;70(7):684-697. doi:10.1016/j.crad.2015.02.010
- Janinis J, Patriki M, Vini L, Aravantinos G, Whelan JS. The pharmacological treatment of aggressive fibromatosis: a systematic review. *Ann Oncol*. 2003;14(2):181-190. doi:10.1093/annonc/mdg064
- Smith K, Desai J, Lazarakis S, Gyorki D. Systematic review of clinical outcomes following various treatment options for patients with extraabdominal desmoid tumors. *Ann Surg Oncol*. 2018;25(6):1544-1554. doi:10.1245/s10434-018-6408-7
- Kasper B, Baumgarten C, Bonvalot S, et al. Management of sporadic desmoid-type fibromatosis: a European consensus approach based on patients' and professionals' expertise - a sarcoma patients EuroNet and European Organisation for Research and Treatment of Cancer/Soft Tissue and Bone Sarcoma Group initiative. *Eur J Cancer*. 2015;51(2):127-136. doi:10.1016/j.ejca.2014.11.005
- Bonvalot S, Ternès N, Fiore M, et al. Spontaneous regression of primary abdominal wall desmoid tumors: more common than previously thought. *Ann Surg Oncol*. 2013;20(13):4096-4102. doi:10.1245/s10434-013-3197-x
- Martínez Trufero J, Pajares Bernad I, Torres Ramón I, Hernando Cubero J, Pazo Cid R. Desmoid-type fibromatosis: who, when, and how to treat. *Curr Treat Options Oncol*. 2017;18(5):29. doi:10.1007/s11864-017-0474-0
- Peng PD, Hyder O, Mavros MN, et al. Management and recurrence patterns of desmoids tumors: a multi-institutional analysis of 211 patients. *Ann Surg Oncol*. 2012;19(13):4036-4042. doi:10.1245/s10434-012-2634-6
- Cobianchi L, Ravetta V, Viera FT, et al. The challenge of extraabdominal desmoid tumour management in patients with Gardner's syndrome: radiofrequency ablation, a promising option. *World J Surg Oncol*. 2014;12:361. doi:10.1186/1477-7819-12-361
- Knudsen AL, Bülow S. Desmoid tumour in familial adenomatous polyposis. A review of literature. *Fam Cancer*. 2001;1(2):111-119. doi:10.1023/a:1013841813544
- Kamath SS, Parsons JT, Marcus RB, Zlotecki RA, Scarborough MT. Radiotherapy for local control of aggressive fibromatosis. *Int J Radiat Oncol Biol Phys*. 1996;36(2):325-328. doi:10.1016/s0360-3016(96)00321-5
- Guadagnolo BA, Zagars GK, Ballo MT. Long-term outcomes for desmoid tumors treated with radiation therapy. *Int J Radiat Oncol Biol Phys*. 2008;71(2):441-447. doi:10.1016/j.ijrobp.2007.10.013
- Pritchard DJ, Nascimento AG, Petersen IA. Local control of extra-abdominal desmoid tumors. *J Bone Joint Surg Am*. 1996;78(6):848-854. doi:10.2106/00004623-199606000-00007
- Penel N, Le Cesne A, Bonvalot S, et al. Surgical versus non-surgical approach in primary desmoid-type fibromatosis patients: A nationwide prospective cohort from the French Sarcoma Group. *Eur J Cancer*. 2017;83:125-131. doi:10.1016/j.ejca.2017.06.017
- Cornelis F, Havez M, Lippa N, et al. Radiologically guided percutaneous cryotherapy for soft tissue tumours: A promising treatment. *Diagn Interv Imaging*. 2013;94(4):364-370. doi:10.1016/j.diii.2013.02.001
- Wang Y, Wang W, Tang J. Ultrasound-guided high intensity focused ultrasound treatment for extra-abdominal desmoid tumours: preliminary results. *Int J Hyperthermia*. 2011;27(7):648-653. doi:10.3109/02656736.2011.597047
- Schmitz JJ, Schmit GD, Atwell TD, et al. Percutaneous Cryoablation of Extraabdominal Desmoid Tumors: A 10-Year Experience. *AJR Am J Roentgenol*. 2016;207(1):190-195. doi:10.2214/AJR.15.14391

From The University of Texas MD Anderson Cancer Center, Houston, Texas.

Disclosure: The authors have completed and returned the ICMJE Form for Disclosure of Potential Conflicts of Interest. Dr Yevich reports consultant fees from Varian and Boston Scientific; stipend and travel expenses from HMP Global (Editor-in Chief, *IO Learning*). Dr Ali reports no conflicts of interest regarding the content herein.

Address for Correspondence: Steven Yevich, MD, MPH, Associate Professor, Department of Interventional Radiology, Division of Diagnostic Imaging, The University of Texas MD Anderson Cancer Center, Houston, TX. Email: syevich@mdanderson.org