VDM VASCULAR DISEASE MANAGEMENT
OFFICIAL MEDIA PARTNER OF iSET | AMP

CASE REPORT

PEER REVIEWED

Successful Recanalization of a Superficial Femoral Artery Chronic Total Occlusion Using the Santreva-ATK Endovascular Revascularization Catheter

Angelo Caputi Zuniga, MD
Sudhir Mungee, MD

Keywords
Chronic Total Occlusion
Superficial Femoral Artery
Peripheral Arterial Disease
Endovascular Revascularization
Intraplaque Crossing
Atheroplasty

October 2026
ISSN 2152-4343

Key Summary

- This case report describes a 67-year-old man with lifestyle-limiting claudication, ankle-brachial index 0.52, and a 60-mm, moderately-to-severely calcified superficial femoral artery chronic total occlusion.
- The Santreva-ATK Endovascular Revascularization Catheter (AngioSafe) crossed the lesion in 3 minutes 10 seconds, creating a channel without apparent distal embolization. Balloon angioplasty and 2 overlapping nitinol stents restored brisk flow and preserved 3-vessel runoff; no procedural complications were reported.
- At 7 months, the patient remained claudication-free; ankle-brachial index rose from 0.52 to 1.06 and toe pressure from 99 to 192 mm Hg. This case demonstrates the feasibility of Santreva-ATK–facilitated intraplaque crossing and channel creation as an adjunct to definitive endovascular treatment of femoropopliteal chronic total occlusions.

© 2026 HMP Global. All Rights Reserved.

Any views and opinions expressed are those of the author(s) and/or participants and do not necessarily reflect the views, policy, or position of Vascular Disease Management or HMP Global, their employees, and affiliates.

Abstract

Femoropopliteal chronic total occlusions (CTOs) remain challenging for endovascular intervention because successful revascularization requires reliable lesion crossing and distal true-lumen access. This case report discusses a 67-year-old man with lifestyle-limiting claudication and a resting left ankle-brachial index of 0.52 secondary to a 60-mm, moderately-to-severely calcified superficial femoral artery CTO. The lesion was successfully traversed using the Santreva-ATK Endovascular Revascularization Catheter (AngioSafe), with a crossing time of 3 minutes 10 seconds and angiographic channel formation without apparent distal embolization. Definitive treatment with balloon angioplasty and self-expanding stent implantation restored brisk antegrade flow with preserved 3-vessel runoff. At 7-month follow-up, the patient remained free of claudication, with normalization of the ankle-brachial index to 1.06. This case demonstrates the feasibility of Santreva-ATK–facilitated intraplaque crossing and channel creation as an adjunct to definitive endovascular treatment of femoropopliteal CTOs.

Introduction

Femoropopliteal chronic total occlusions (CTOs) remain among the most challenging lesions encountered during endovascular treatment of peripheral arterial disease. Although contemporary endovascular therapies provide multiple options for definitive treatment, successful revascularization first requires traversal of the occluded segment and establishment of guidewire access within the distal true lumen. Long occlusions, resistant proximal caps, calcification, and loss of an intraplaque trajectory may complicate conventional wire-based crossing strategies.[1-4]

Dedicated CTO crossing devices have therefore been developed to facilitate lesion traversal while limiting uncontrolled subintimal passage. The Santreva-ATK Endovascular Revascularization Catheter (AngioSafe) employs a rotating distal tip and a centering mechanism to achieve intraplaque atheroplasty, simultaneously puncturing, displacing, and compressing atherosclerotic plaque to create a controlled intraplaque channel that facilitates guidewire advancement into the distal true lumen.[5] We report successful recanalization of a superficial femoral artery (SFA) CTO using the Santreva-ATK catheter followed by balloon angioplasty and self-expanding stent implantation, with sustained symptomatic and hemodynamic improvement at 7-month follow-up.

Case Presentation

A 67-year-old man with a history of hypertension, hyperlipidemia, nonobstructive coronary artery disease, and a more than 20-year history of tobacco use was referred for progressive bilateral lower extremity claudication, significantly worse on the left leg and limiting his daily activities. Noninvasive vascular testing demonstrated a resting ankle-brachial index (ABI) of 0.91 on the right and 0.52 on the left, with duplex ultrasound demonstrating occlusion of the left SFA. The left great toe pressure was 99 mm Hg. Given his lifestyle-limiting symptoms and significant left lower extremity arterial disease, peripheral angiography and endovascular revascularization were performed.

Right common femoral arterial access was obtained with a 5F sheath. Abdominal aortography demonstrated a patent infrarenal aorta and bilateral iliac arteries without significant obstructive disease. Selective left lower extremity angiography demonstrated patent common femoral and profunda femoris arteries and a 100% CTO of the proximal-to-mid SFA, with distal SFA reconstitution through profunda collaterals and preserved 3-vessel infrapopliteal runoff (**Figure 1A,B**).

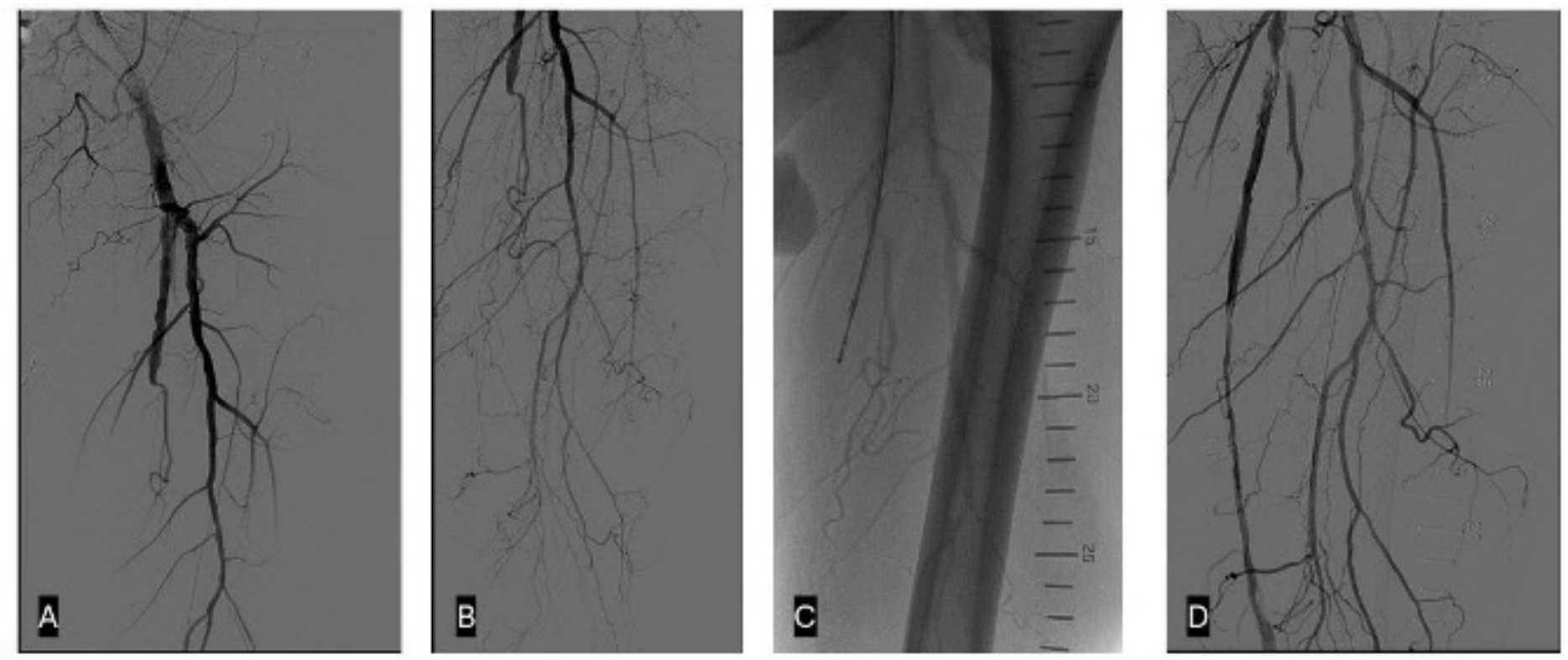

Figure 1. (A, B) Baseline angiography demonstrating a chronic total occlusion of the superficial femoral artery. **(C)** The Santreva-ATK Endovascular Revascularization Catheter (AngioSafe) in use to cross the chronic total occlusion. **(D)** Angiography after device removal showing a patent channel through the occlusion before stent implantation.

The 5F system was exchanged for a 7F Flexor Ansel guiding sheath (Cook Medical), and systemic unfractionated heparin was administered. A Grand Slam 0.014-inch guidewire (Asahi Intecc) was positioned at the proximal cap of the CTO with support from a 6F multipurpose-1 guide catheter. The lesion was a 60-mm CTO with moderate to severe calcification. The Santreva-ATK Endovascular Revascularization Catheter was advanced to the proximal cap and activated. With controlled rotation and forward advancement, the catheter penetrated the proximal cap and was progressively advanced through the occluded SFA segment (**Figure 1C**). The crossing time was 3 minutes and 10 seconds.

After traversal of the occlusion, 2 mL of contrast was injected through the Santreva-ATK catheter, confirming intraluminal position within the distal vessel. The Grand Slam guidewire was then advanced distally through the catheter, establishing wire access across the CTO and into the distal true lumen. Following removal of the Santreva-ATK catheter, angiography demonstrated formation of a channel through the previously occluded SFA (**Figure 1D**).

Definitive revascularization was subsequently performed with a 5 x 60-mm Sterling balloon (Boston Scientific) followed by implantation of 2 overlapping Innova self-expanding nitinol stents (Boston Scientific) across the treated SFA segment. The stents were postdilated with a 6 x 100-mm Sterling balloon. Final angiography demonstrated restoration of brisk antegrade flow through the SFA with an excellent angiographic result and preserved 3-vessel runoff below the knee (**Figure 2**). The procedure was completed without complications, and the patient was discharged on dual antiplatelet therapy.

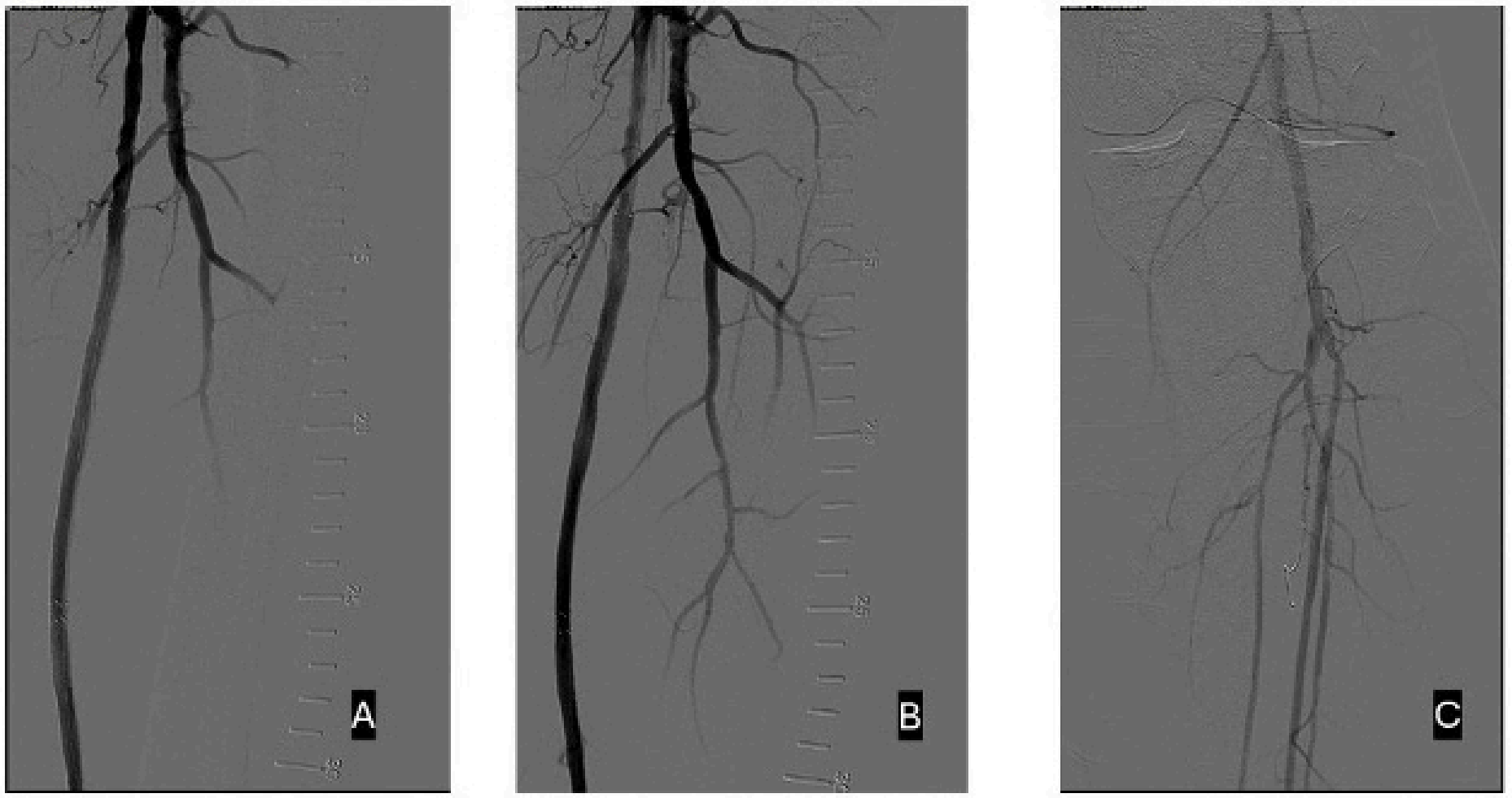

Figure 2. (A, B) Final angiography following balloon angioplasty and self-expanding stent implantation demonstrating restoration of brisk antegrade flow through the previously occluded superficial femoral artery. **(C)** Final, below-the-knee angiography demonstrating preserved 3-vessel runoff.

At approximately 7 months after intervention, the patient remained free of claudication. Repeat noninvasive vascular testing demonstrated normalization of the resting left ABI from 0.52 before intervention to 1.06, with an increase in left great toe pressure from 99 mm Hg to 192 mm Hg, supporting sustained clinical and hemodynamic improvement following revascularization.

Discussion

Successful crossing remains a fundamental challenge in the endovascular treatment of femoropopliteal CTOs. Conventional guidewire and catheter techniques are generally attempted first; however, resistant caps, long lesion length, calcification, and deviation into the subintimal space may prevent successful distal true-lumen access. Intentional subintimal angioplasty, first described for femoropopliteal occlusions decades ago, provides an alternative strategy but may introduce the additional challenge and cost of distal true-lumen re-entry.[2,3] Dedicated crossing and re-entry technologies have subsequently expanded the options available for complex CTOs.[4,6-8]

The Santreva-ATK catheter differs mechanistically from conventional wire escalation and purely subintimal crossing techniques. Its rotating distal cutting loop is designed to puncture the CTO cap while simultaneously displacing and laterally compressing plaque. The expandable centering system is intended to maintain an intraplaque trajectory as the catheter advances.[5] Importantly, the device not only creates an angiographically visible channel but allows the interventionalist to proceed to definitive therapy with established endovascular modalities.

In this case, the Santreva-ATK catheter successfully crossed the proximal SFA CTO, with contrast confirming distal intraluminal position and allowing guidewire passage. Post-removal angiography showed a patent channel through the occlusion prior to balloon angioplasty, highlighting the key advantage of simultaneous lesion crossing and channel creation to facilitate definitive treatment.

The importance of dedicated CTO technology is also supported by prior experience with other crossing systems. In an analysis of 438 infrainguinal CTO interventions from the XLPAD registry, an initial specialized CTO-device strategy achieved greater primary crossing success than a conventional guidewire-microcatheter strategy (72.1% vs 51.9%), although overall procedural success after crossover and bailout strategies was similar.[7] Similarly, the CONNECT II study demonstrated successful crossing in 97% of targeted femoropopliteal CTOs using an optical coherence tomography-guided crossing system alone or with adjunctive crossing/re-entry devices.[6] Collectively, these data highlight that device-assisted strategies may be particularly valuable when conventional wire-based techniques are technically difficult, while emphasizing that crossing technology represents one component of a broader lesion-specific revascularization strategy.[1,4]

These findings are consistent with the recently published RESTOR-1 pivotal study, which prospectively evaluated Santreva-ATK for femoropopliteal CTO crossing.[9] Among 74 patients included in the effectiveness analysis, clinical success was achieved in 87.8%, despite more than 70% of lesions having moderate or severe calcification and a mean CTO length of 131.6 ± 90.4 mm. From a safety perspective, no device-related major adverse events were reported through 30 days in RESTOR-1.[9] Notably, the prespecified safety outcomes included distal embolization requiring additional treatment, an

important consideration during mechanical traversal and modification of atherosclerotic CTOs.[5,9] Similarly, in our case, channel creation and subsequent revascularization were achieved without angiographically apparent distal embolization, with preservation of brisk 3-vessel runoff.

A major potential benefit of dedicated intraplaque crossing systems, particularly in long femoropopliteal CTOs, is the potential reduction in crossing time compared with traditional wire escalation or subintimal techniques. Contemporary studies of conventional strategies report mean crossing times that frequently exceed 20 to 40 minutes in long or heavily calcified SFA occlusions, with a substantial proportion of cases requiring multiple wire and catheter exchanges or bailout re-entry devices.[7,10] In contrast, RESTOR-1 demonstrated a median crossing time of approximately 9 minutes with Santreva-ATK, even in lesions with a mean CTO length of approximately 132 mm and high calcific burden.[9] In our case, the crossing time was approximately 3 minutes for a 60-mm lesion, aligning with the rapid crossing performance observed in this study. This reduction in crossing time has important downstream implications for procedural efficiency, including shorter fluoroscopy time, reduced contrast volume, and decreased radiation exposure for both patient and operator. From a health system perspective, faster and more predictable lesion traversal may translate into improved cath lab workflow efficiency and lower per-case resource utilization.[4,11]

Following successful crossing in our patient, balloon angioplasty and overlapping self-expanding nitinol stents restored brisk antegrade SFA flow while preserving 3-vessel runoff. Self-expanding nitinol stents have established efficacy for femoropopliteal disease, particularly when angioplasty alone results in an inadequate result or when lesion characteristics favor scaffolding.[1,10-12] The most clinically meaningful finding in this case, however, was the durability of symptomatic and hemodynamic improvement: approximately 7 months after intervention, the patient remained free of claudication, with normalization of the left ABI from 0.52 to 1.06 and an increase in toe pressure from 99 to 192 mm Hg.

This case illustrates the feasibility of using the Santreva-ATK catheter to facilitate intraluminal crossing and channel formation in an SFA CTO, enabling subsequent conventional endovascular revascularization. While a single case cannot establish comparative efficacy or long-term durability, the procedural result, reduced crossing time implications, and sustained clinical improvement are concordant with the early multicenter experience reported in RESTOR-1. Further studies comparing device-assisted intraplaque crossing with conventional wire escalation and subintimal strategies will help define the optimal role of this technology in contemporary femoropopliteal CTO intervention.

Conclusion

The Santreva-ATK Endovascular Revascularization Catheter facilitated successful intraluminal crossing and channel creation in a challenging SFA CTO, enabling subsequent balloon angioplasty and stent implantation. The procedure resulted in successful revascularization with sustained symptomatic and hemodynamic improvement at 7-month follow-up. This case highlights atheroplasty as a promising adjunctive strategy for femoropopliteal CTO crossing, particularly when maintaining an intraplaque trajectory is desired. ■

Affiliations and Disclosures

From the Division of Cardiology, University of Illinois College of Medicine at Peoria – OSF Saint Francis Medical Center, Peoria, Illinois.

Dr Zuniga reports no financial relationships or conflicts of interest regarding the content herein. Dr Mungee is an investor in AngioSafe.

Manuscript accepted August 24, 2026.

Address for correspondence: Angelo Caputi Zuniga, MD, Division of Cardiology, University of Illinois College of Medicine at Peoria – OSF Saint Francis Medical Center, 530 NE Glen Oak Ave, Peoria, IL 61637. Email: dr.caputi.z@gmail.com

References

1. Gornik HL, Aronow HD, Goodney PP, et al; Peer Review Committee Members. 2024 ACC/AHA/AACVPR/APMA/ABC/SCAI/SVM/SVN/SVS/SIR/VESS guideline for the management of lower extremity peripheral artery disease: a report of the American College of Cardiology/American Heart Association Joint Committee on Clinical Practice Guidelines. *Circulation*. 2024;149(24):e1313-e1410. doi:10.1161/CIR.0000000000001251

2. Bolia A, Miles KA, Brennan J, Bell PR. Percutaneous transluminal angioplasty of occlusions of the femoral and popliteal arteries by subintimal dissection. *Cardiovasc Intervent Radiol.* 1990;13(6):357-363. doi:10.1007/BF02578675

3. Ishihara T, Takahara M, Iida O, et al; ZEPHYR Investigators. Comparable 2-year restenosis rates following subintimal and intraluminal drug-eluting stent implantation for femoropopliteal chronic total occlusion. *J Endovasc Ther.* 2016;23(6):889-895. doi:10.1177/1526602816666261

4. Korosoglou G, Schmidt A, Lichtenberg M, et al. Global algorithm for the endovascular treatment of chronic femoropopliteal lesions: an interdisciplinary expert opinion statement. *JACC Cardiovasc Interv.* 2025;18(5):545-557. doi:10.1016/j.jcin.2024.11.038

5. U.S. Food & Drug Administration. Santreva-ATK Endovascular Revascularization Catheter: 510(k) Premarket Notification K252315; 2025. https://www.accessdata.fda.gov/scripts/cdrh/cfdocs/cfpmn/pmn.cfm?ID=K252315

6. Selmon MR, Schwindt AG, Cawich IM, et al. Final results of the Chronic Total Occlusion Crossing With the Ocelot System II (CONNECT II) study. *J Endovasc Ther.* 2013;20(6):770-781. doi:10.1583/13-4380MR.1

7. Banerjee S, Sarode K, Patel A, et al. Comparative assessment of guidewire and microcatheter vs a crossing device-based strategy to traverse infrainguinal peripheral artery chronic total occlusions. *J Endovasc Ther.* 2015;22(4):525-534. doi:10.1177/1526602815587707

8. Bosiers M, Diaz-Cartelle J, Scheinert D, Peeters P, Dawkins KD. Revascularization of lower extremity chronic total occlusions with a novel intraluminal recanalization device: results of the ReOpen study. *J Endovasc Ther.* 2014;21(1):61-70. doi:10.1583/12-4083R.1

9. Banerjee S, Metzger C, Thatipelli M, et al. Safety and effectiveness of the Santreva™-ATK endovascular revascularization catheter in the RESTOR-1 peripheral CTO crossing pivotal study. *Am J Cardiol.* 2026;263:33-42. doi:10.1016/j.amjcard.2026.01.007

10. Schillinger M, Sabeti S, Loewe C, et al. Balloon angioplasty versus implantation of nitinol stents in the superficial femoral artery. *N Engl J Med*. 2006;354(18):1879-1888. doi:10.1056/NEJMoa051303

11. Laird JR, Katzen BT, Scheinert D, et al; RESILIENT Investigators. Nitinol stent implantation versus balloon angioplasty for lesions in the superficial femoral artery and proximal popliteal artery: twelve-month results from the RESILIENT randomized trial. *Circ Cardiovasc Interv.* 2010;3(3):267-276. doi:10.1161/CIRCINTERVENTIONS.109.903468

12. Laird JR, Katzen BT, Scheinert D, et al; RESILIENT Investigators. Nitinol stent implantation vs. balloon angioplasty for lesions in the superficial femoral and proximal popliteal arteries of patients with claudication: three-year follow-up from the RESILIENT randomized trial. *J Endovasc Ther.* 2012;19(1):1-9. doi:10.1583/11-3627.1

13. Tepe G, Laird J, Schneider P, et al; IN.PACT SFA Trial Investigators. Drug-coated balloon versus standard percutaneous transluminal angioplasty for the treatment of superficial femoral and popliteal peripheral artery disease: 12-month results from the IN.PACT SFA randomized trial. *Circulation*. 2015;131(5):495-502. doi:10.1161/CIRCULATIONAHA.114.011004

14. Fakhry F, Spronk S, van der Laan L, et al. Endovascular revascularization and supervised exercise for peripheral artery disease and intermittent claudication: a randomized clinical trial. *JAMA*. 2015;314(18):1936-1944. doi:10.1001/jama.2015.14851

HMP Education

HMP Omnimedia

HMP Europe

© 2026 HMP Global. All Rights Reserved.