the dermatologist

Navigating Advanced Basal Cell Carcinoma and Advanced Cutaneous Squamous Cell Carcinoma Care

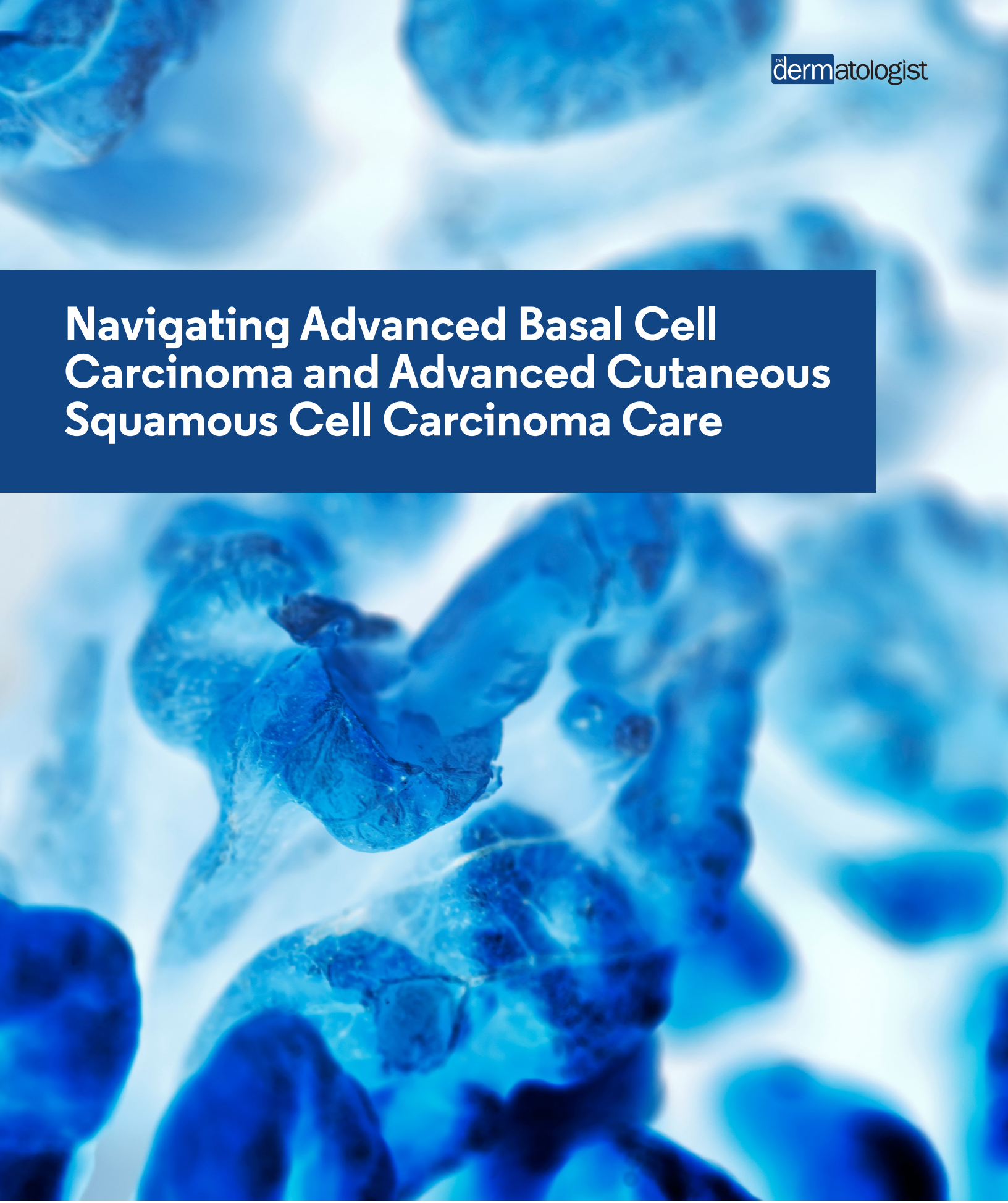

Sponsored by: REGENERON®

INTRODUCTION

Basal cell carcinoma (BCC) and cutaneous squamous cell carcinoma (CSCC) comprise the two most common non-melanoma skin cancers, with BCC being the most common of all cancers overall.[1,2] While these carcinomas are often surgically removed and not fatal, advanced stages of disease can cause serious impacts due to the aggressive nature of the disease, negative effects on quality of life, and mortality if not properly treated.[2,3] Treatment options for advanced BCC (aBCC) and advanced CSCC (aCSCC) have evolved in recent years, providing hope for those afflicted.[2,3]

OVERVIEW OF aBCC AND aCSCC

aBCC and aCSCC Disease Burden

aBCC comprises locally advanced BCC (laBCC) and metastatic BCC (mBCC), with up to 10% of BCC cases progressing to the advanced stage.[3] laBCC lesions are generally large and aggressive.[3] Surgery is often not possible, as it is considered disfiguring or associated with a loss of function (eg, proximity to the eye, ear, or nasal passage).[3] mBCC cases are uncommon, with an estimated incidence of 0.55%.[3] However, mBCC is typically aggressive and spreads primarily to the lymph nodes, followed by the bones and lungs.[3] Despite the current first line treatment options, such as hedgehog pathway inhibitors, some patients are not candidates or may have been previously treated with the outcomes of failure to respond or progressive disease.[3] Cases of laBCC and mBCC require a multidisciplinary approach and specialized care for diagnosis and treatment because surgery is often insufficient.[3]

aCSCC encompasses both locally advanced CSCC (laCSCC) and metastatic CSCC (mCSCC), which are associated with a poor long-term prognosis and a relative 5-year survival rate of 51% to 64%.[4] laCSCC may not be amenable to surgery or radiation therapy and therefore may require alternative treatment strategies.[4] mCSCC typically spreads to the lymph nodes but can spread to the lungs, liver, brain, bones, and skin.[5] With nearly 5% of CSCC cases progressing to advanced disease and a low 5-year survival rate, cases of aCSCC must be treated carefully and rigorously.[5]

Risk Factors and Mutational Landscape

Risk factors for both BCC and CSCC include exposure to ultraviolet (UV) radiation; UVB is primarily indicated as the most common risk factor for BCC, and both UVA and UVB cause CSCC.[3,6] Along with UV exposure, sporadic somatic mutations, inherited mutations, and other environmental factors can contribute to the development of aBCC and aCSCC.[3,6] BCC and CSCC are more prevalent in the elderly population; more than 80% of CSCC cases occur in those 60 years or older, and the median age of BCC patients is 68 years old.[1,2] Cases of BCC and CSCC are more frequent among men than women, and an immunocompromised state can increase the risk of developing these diseases.[1,2] Elderly age and immunocompromised state greatly increase the risk of metastasis in BCC and CSCC and require careful attention when treating.[1,2]

Hedgehog pathway genes are the most commonly implicated genes in BCC, including the patched/hedgehog protein family (HH), patched receptor (PTCH1), and smoothened (SMO) protein.[3] Mutations in the Hippo-Yap pathway, as well as genetic alterations of TP53, have also been implicated in BCC development.[3] Furthermore, the TERT gene, which maintains the length of the telomere, is commonly mutated in BCC.[3] In mBCC, mutations associated with YAP inhibition and mutations in phosphatidylinositol 3-kinase (PI3K)/protein kinase B (AKT) were enriched when compared to matched cases of low-clinical-risk BCC, making these pathways potential indicators for metastatic potential.[7]

TP53 and NOTCH1 are among the most frequently mutated genes in CSCC, but they do not drive progression on their own.[6] It has been shown that up to 85% of mCSCC cases had genetic mutations in TP53 and KMT2D, and mutations in RAS proto-oncogene and CDKN2A have also been found in mCSCC tumors, providing potential biomarkers for advanced disease.[5]

DISEASE EVALUATION

Clinical Evaluation

Patient history is an important factor to consider for risk assessment, as previous cases of BCC or CSCC increase the risk of developing subsequent BCC or CSCC.[8] Clinical features of aBCC include the presence of a flesh- or pink-colored, pearly lesion(s); poorly defined borders; the involvement of vital structures such as the temple, ear, eye, or nose; and the inability to resect surgically and reconstruct without unacceptable functional or aesthetic deficit.[1,9] These features suggest that a lesion may be high risk for advanced disease and require special care and management to prevent progression.[9]

Important clinical features of high-risk or advanced CSCC include a tumor diameter greater than 2 cm; a location on the head, neck, hands, feet, pretibial, and anogenital regions; palpable regional lymph nodes; immunosuppression; perineural invasion; and the presence of multiple co-existing lesions.[6,10] Tumors with undefined borders or those considered unresectable pose an increased risk of advanced disease.[6] Lesions with such features should be biopsied and assessed for the risk of advanced-stage disease.[10]

Histopathological Approaches

Biopsy and histopathological evaluation is recommended when aBCC or aCSCC are suspected.[3,5,6] Tumors pose an increased risk of metastasis if they show signs of deep skin invasion, bone invasion, or perineural invasion in the histopathological analysis.[3,5,6] Utilizing histopathological analysis is important to help guide treatment and provide the careful diagnosis and advanced care required to properly treat these tumors.[9,10]

Molecular Biological Approaches

Gene expression profiling (GEP)

In addition to histopathological analysis, gene expression profiling (GEP) can be used to assess biomarkers and the risk of disease progression more precisely than histopathology would alone.[6] Gene expression in a tumor can be quantified by DNA microarray, real-time PCR, or through RNA from histology samples.[6] Differentially expressed genes may be correlated with clinical parameters, including the likelihood of treatment response or aggressiveness of the tumor.[6] Potential biomarkers for aBCC progression include sex determining region Y (SRY)-box 2 (SOX2) and matrix metalloproteinases (MMPs), including MMP-1, MMP-2, MMP-3, MMP-8, and MMP-9.[11] While some potential biomarkers have surfaced, current research about biomarkers of aBCC in predicting prognosis is limited. There are no definitive results regarding the clinical use of biomarkers.[11]

A 40-gene expression profile test has been developed to predict metastatic risk in high-risk CSCC.[6,12] This test examines potential biomarkers to facilitate risk assessment, which can help inform treatment decisions.[6,12] When combined with clinical staging systems, the 40-GEP test has been shown to define high-risk patients and guide risk-aligned treatment strategies for aCSCC.[12]

Tumor mutational burden (TMB)

In addition to histopathology and GEP analysis, another way to guide therapeutic decisions is through the assessment of tumor mutational burden (TMB).[3,6] TMB is a biomarker that measures mutations per megabase of the tumor genome.[3,6] High TMB is correlated to a favorable outcome with immunotherapy in skin cancers and is associated with a high neoantigen load, increasing T cell activity and anti-tumor response in both aBCC and aCSCC.[3,6] As aBCC and aCSCC require specialized treatment—and often through the use of immunotherapeutics—TMB is an emerging biomarker that may be useful in guiding treatment decisions in high-risk or advanced diseases.[3,6]

Programmed Death-Ligand 1 (PD-L1) expression

The expression of programmed death-ligand 1 (PD-L1) has been found on aBCC and aCSCC tumor cells and is associated with poor prognosis.[6,13,14] PD-L1 expressed on tumor cells binds to PD-1 on T cells.[15] This interaction can inhibit T cell activation, trigger apoptosis, decrease cytokine production, promote the tolerance of antigens, and increase T cell lysis, ultimately creating an immunosuppressive tumor microenvironment.[15] BCC genetic assessments have shown frequent amplification in regions of chromosome 9, which include the gene encoding PD-L1.[13] While some studies have found that PD-L1 expression in CSCC is associated with an increased risk of metastasis, others have found contradicting results, indicating PD-L1 testing should not be solely relied upon for diagnosis.[6,16,17,18] PD-L1 testing is recommended only when combined with other tests, such as histopathology or GEP.[6]

What Are Your Key Considerations During Diagnosis and Pre-Treatment?

The complexity of the aBCC case often is not apparent until treatment of the lesion begins and the extent of the tumor is determined during surgery (eg, depth, perineural invasion, size). Thus, decisions are made sequentially based on the extent of the tumor.

Aggressive tumors require additional therapy, including radiation and/or systemic therapy. Special circumstances may require pre-treatment with systemic agents, such as periorbital lesions with tethering to the orbital rim, which require pre-treatment prior to surgery.

The extent of an aCSCC tumor is typically not apparent until the patient presents for surgery. Histological features and size by themselves do not allow one to determine the aggressiveness of the tumor, which will be immediately borne out once the tumor is debulked and initial Mohs stages are visualized.

Aggressive tumors can be sent for gene expression profiling (GEP)—class 2A lesions have a 20% chance of local recurrence, and Class 2B lesions have a 50% chance of local recurrence. Imaging studies aid in delineating extent of local disease and possible metastases. Referral to radiation oncology may be used to decrease local recurrence. Unresectable and metastatic lesions can be treated with systemic medications, including cemiplimab.

Staging of aCSCC is delineated once the tumor is excised. I use the Brigham and Women's staging rather than the American Joint Committee on Cancer (AJCC) staging because it is more practical. Brigham and Women's class II SCCs are often more ambiguous to manage; once the tumor is excised, does it require additional treatment without clinical disease (ie, radiation therapy)? These patients require closer follow-up.

– George Murakawa, MD, PhD

AVAILABLE MODES OF THERAPY FOR aBCC AND aCSCC

Surgery

Surgery is considered the front-line treatment for BCC and CSCC when the tumor can be completely resected.[1,19] Mohs micrographic surgery (MMS) is considered standard of care for both CSCC and BCC to ensure complete removal of the tumor while avoiding unnecessary excision of healthy tissue.[1,19] The goal of aCSCC and aBCC treatment, including surgery, is to remove the tumor in its entirety and to correct any functional defect resulting from the tumor, while taking into consideration the patient's quality of life, including cosmetic concerns.[1,19] aBCC and aCSCC may not able to be resected entirely, whether due to undefined borders, location near vital structures, perineural involvement, bone invasion, or metastasis.[3,4,6,9,10] Therefore, surgery is not sufficient as a sole treatment to completely cure aBCC and aCSCC.[3,4,6,9,10]

Radiation

Radiation therapy is recommended when surgical resection is not sufficient or possible for BCC and CSCC tumors, including aBCC and aCSCC.[20] This includes cases of aBCC or aCSCC with perineural invasion, lymphovascular invasion, ill-defined borders, a diameter larger than 2 cm, or deep tumor invasion.[20] In these circumstances of advanced disease, radiation therapy can be used with curative intent, as a salvage therapy following recurrence from surgery, or as an adjuvant therapy immediately following surgery to prevent recurrence.[20] Radiation therapy has been shown to be efficacious in both aBCC and aCSCC; however, it frequently requires combination treatment with surgery or another treatment for complete ablation of the tumor.[20]

Chemotherapy

Chemotherapy treatments for CSCC and BCC can include topical application of 5-fluorouracil or, less commonly, intralesional or systemic applications of doxorubicin, cisplatin, and bleomycin, particularly for CSCC.[21] Topical chemotherapy, including 5-fluorouracil, has demonstrated efficacy in laCSCC cases when combined with radiation therapy.[21] However, chemotherapy regimens for CSCC and BCC are not commonly used, as they present with significant toxicities such as neutropenia, thrombocytopenia, and anemia as well as other side effects including nausea and emesis.[21]

Targeted Therapy

Hedgehog inhibitors for aBCC

In aBCC, SMO, a transmembrane protein involved in hedgehog pathway signal transduction, acquires mutations which result in overactivation of downstream hedgehog pathway molecules.[22] Hedgehog Inhibitors (HHIs) work by inhibiting SMO, restoring normal cell regulation and proliferation (Figure 1).[22] Systemic therapy such as Hedgehog inhibitors (HHIs) may be considered for laBCC in those who have primary or recurrent extensive disease in which surgery and/or radiation therapy may not result in a cure or would possibly produce a significant functional limitation.[23] HHIs are recommended as other regimens that can be considered in locally advanced, nodal, or distant metastatic disease per National Comprehensive Cancer Network (NCCN) guidelines.[23]

Two HHIs are FDA-approved for the treatment of aBCC: sonidegib and vismodegib.[24,25] Sonidegib was FDA approved in 2015 for the treatment of adult patients with locally advanced basal cell carci-

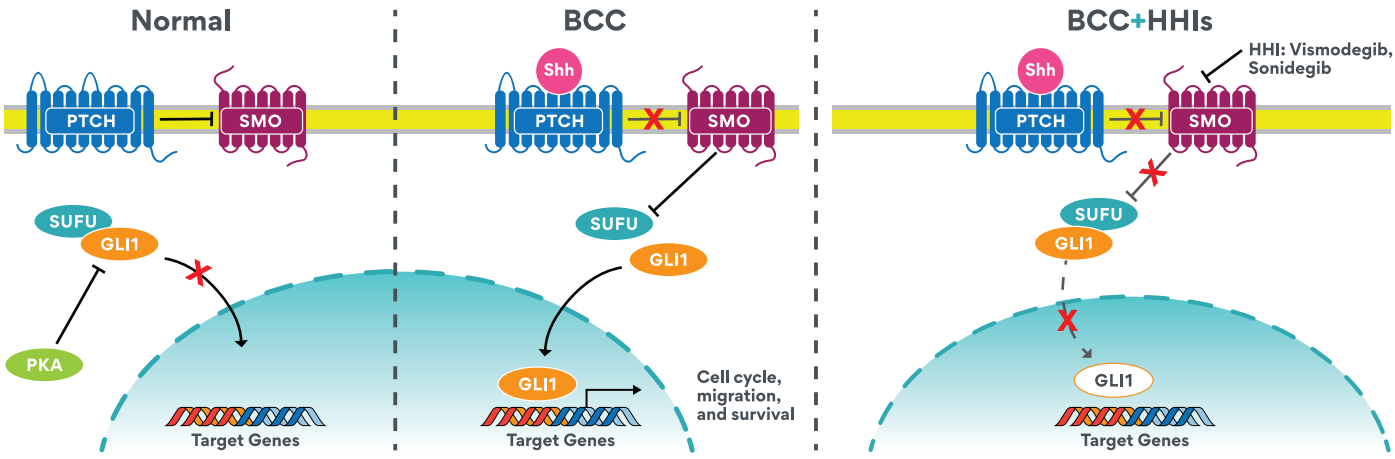

Figure 1. Hedgehog pathway under normal conditions, in basal cell carcinoma (BCC), and when hedgehog inhibitors (HHIs) are used.
Abbreviations: BCC, basal cell carcinoma; GLI1, glioma-associated oncogene homolog 1; HHIs, hedgehog inhibitors; PKA, protein kinase A; PTCH, Patched; Shh, Sonic hedgehog; SMO, Smoothened; SUFU, Suppressor of fused.
Source: Modified from Alkassis S, et al. *Cancers.* 2024;16(17):3075

noma that has recurred following surgery or radiation therapy or for those who are not candidates for surgery or radiation therapy.[24] Vismodegib was FDA approved in 2012 for the treatment of adults with metastatic basal cell carcinoma or with locally advanced basal cell carcinoma that has recurred following surgery or who are not candidates for surgery and who are not candidates for radiation.[25] For patients receiving HHIs, the most common adverse reactions as a class include muscle spasms, alopecia, dysgeusia, weight loss, fatigue, nausea, diarrhea, decreased appetite, constipation, myalgia, abdominal pain, headache, pain, arthralgias, vomiting, pruritus, and ageusia.[24,25]

PD-1 inhibitors for aBCC and aCSCC

PD-L1 expression on tumor cells is recognized by PD-1 on T cells, resulting in immunosuppression.[15] Blocking the PD-L1/PD-1 pathway prevents the immunosuppressive microenvironment and restores the immune system's anti-tumor activity (Figure 2).[15] Systemic therapies such as PD-1 inhibitors may be considered for laBCC in those who have primary or recurrent extensive disease in which surgery and/or radiation therapy may not result in a cure, in which surgery or radiation would possibly produce a significant functional limitation, or in those previously treated with an HHI or for whom an HHI is not appropriate in patients with laBCC or mBCC.[23] For patients with aBCC, PD-1 inhibitors are recommended as useful in certain circumstances in laBCC including neoadjuvant, nodal, and metastatic disease per NCCN guidelines.[23] For patients with aCSCC, PD-1 inhibitors are recommended as neoadjuvant therapy for those with very high-risk disease and as a preferred regimen as systemic therapy alone in those with primary and recurrent laCSCC or unresectable disease, specifically if curative radiation therapy or surgery is not feasible for locally advanced, recurrent, or metastatic disease per NCCN guidelines.[26]

One PD-1 inhibitor, cemiplimab, is FDA-approved for the treatment of aBCC, and two PD-1 inhibitors, cemiplimab and pembrolizumab, are approved for the treatment of aCSCC.[27,28] Cemiplimab was FDA approved in 2021 for the treatment of patients with locally advanced or metastatic basal cell carcinoma who have been previously treated with a hedgehog pathway inhibitor or for whom a hedgehog pathway inhibitor is not appropriate.[27] Cemiplimab was also

What Are Your Key Considerations During Active Treatment?

It's imperative to be meticulous in charting/documentation and billing procedures due to the narrow margins involved in infusion therapy.

Surgery is not always the best option for aCSCC and aBCC skin cancers

The familiarity and comfort in offering targeted immune therapies for advanced BCC and CSCC increases the treatment armamentarium of providers managing skin cancer patients.

– Jason Hawkes, MD, MS

For aBCC patients, obtain imaging studies where appropriate. Consider adjuvant radiation therapy. Consider referral to an oncologist. These patients are typically started on oral hedgehog inhibitors; however, they typically have significant side effects from these medications, including muscle cramps, severe thirst, taste alterations or loss, hair loss, and fatigue and are unable to tolerate the medication, even with pulse therapy. These patients are excellent candidates for cemiplimab.

We have had poor experiences in the past when using hospital-based infusion centers—our office still completes the preauthorization paperwork; no physician is on-site at the infusion center, and we are still responsible for our patients; our patients are low priority for infusion medications (we have been triaged for our patients to be denied access to medications or infusion times).

Our office has considerable experience with performing in-office infusions; we have successfully infused infliximab (and its bioequivalents), rituximab (and its bioequivalents), and mogamulizumab in addition to cemiplimab in our office.

Advantages of infusing directly in-office rather than referring patients to an infusion center include ease and continuity of care for the patient; convenience for the patient; easy extension of our current practice; circumvention of difficulties in communication channels with outside infusion centers; utilization of minimal office resources—no additional staff is required, supplies are minimal.

Tips for infusions: Once IV access is obtained, to maintain the IV line and ensure the patient is adequately hydrated as well as provide time to prepare the medication, begin saline hydration. To minimize infusion reactions, give patients acetaminophen, diphenhydramine, and solumedrol (except for infliximab for psoriasis and cemiplimab for aCSCC and aBCC).

– George Murakawa, MD, PhD

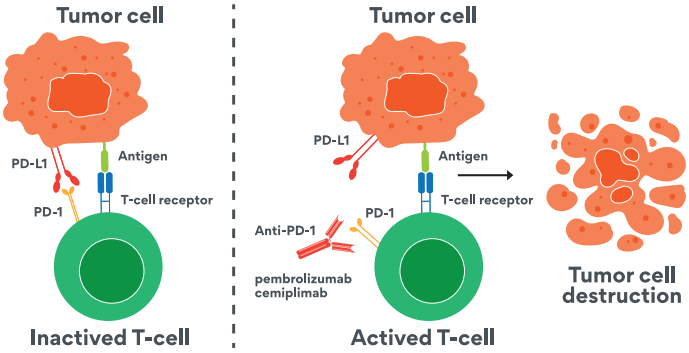

Figure 2. Representation of the mechanism of action for anti-PD-1 antibodies. The tumor antigen is detected by the T-cell receptor, while simultaneously, the programmed cell death ligand 1 (PD-L1) on the tumor surface is detected by programmed cell death protein 1 (PD-1) on the T-cell. This PD-L1/PD-1 signaling results in T-cell inactivation and tumor cell survival. When an anti-PD-1 antibody is introduced, anti-PD-1 blocks the PD-1 receptor on the T-cell, preventing PD-L1/PD-1 signaling and allowing T-cell activation and tumor cell destruction.
Abbreviations: PD-1, programmed cell death protein 1; PD-L1, programmed cell death ligand 1.
Source: Modified from Wang S, et al. *Int J Mol Sci.* 2023;24(13):10684

FDA approved in 2018 for the treatment of patients with metastatic cutaneous squamous cell carcinoma or locally advanced CSCC who are not candidates for curative surgery or curative radiation.[27] Pembrolizumab was FDA-approved in 2020 for the treatment of patients with recurrent or metastatic CSCC or locally advanced CSCC that is not curable by surgery or radiation.[28] For patients receiving PD-1 inhibitors, the most common adverse reactions as a class include fatigue, musculoskeletal pain, nausea, rash, pruritus, diarrhea, and decreased appetite.[27,28] Additional adverse reactions include immune-mediated reactions, such as hyperthyroidism, hypothyroidism, immune-mediated dermatitis, and immune-mediated pneumonitis.[27,28] Early recognition, intervention, and close monitoring, in the setting of adverse effects are important for optimizing the clinical outcome.[29]

Epidermal growth factor receptor (EGFR) inhibitors for aCSCC

Epidermal growth factor receptor (EGFR) is a tyrosine kinase that signals the growth, proliferation, and migration of cancer cells.[30] EGFR is overexpressed in approximately 35% of high-risk CSCC cases and in approximately 80% of mCSCC cases.[31] Due to this overexpression, EGFR inhibitors have been investigated as a consideration for patients with aCSCC in whom PD-1 inhibitors are contraindicated or who have progressed on immunotherapy.[31] There are currently no FDA-approved EGFR inhibitors for the treatment of aCSCC.[31]

What Are Your Key Considerations During Post-Treatment and Monitoring?

Dermatologists are essential to the medical management of targeted immune therapies, including the appropriate selection of eligible patients, safety monitoring during treatment administration, and management of any immune-related cutaneous toxicities relating to therapy.

[Multidisciplinary consultations] can be helpful in providing aCSCC and/or aBCC treatment recommendations for difficult-to-complex cases as well as with coordinating medication administration, drug-related safety monitoring, and medical management of drug-related toxicities such as those involving the skin.

Also consider the role of the primary care physician in the long-term care coordination of patients who have a history of difficult or complex skin cancers. The PCP has more frequent contact with these patients than [dermatologists] might have.

– Jason Hawkes, MD, MS

UNMET NEEDS IN THE aBCC AND aCSCC LANDSCAPE

Despite several promising treatment options for aBCC and aCSCC, there remain unmet needs such as addressing resistance to systemic therapy and effectively managing treatment-related toxicities.[32] Associated side effects from treatment can greatly impact a patient's quality of life.[32] Particularly, many patients with advanced disease such as aBCC have reported frequent symptoms including impaired emotional well-being and restrictions to daily activities.[32] Patients with aBCC have reported bothersome impacts to their well-being such as anxiety, worry, fear, fatigue, and tiredness, emphasizing the necessity for treatment options that can help address patients' needs and improve health-related quality of life.[33] Additionally, the development of drug resistance or tolerance to treatment can be commonly seen in patients, highlighting the need for active research into identifying resistance mechanisms and methods to overcome resistance.[32]



A B C

Figure 3. (**A**) 49-year-old patient presenting with BCC. (**B**) The patient underwent Mohs surgical excision to remove the BCC. (**C**) The excision was repaired with a combination of a Rhomboid transposition flap, a Webster transposition flap, and a full-thickness skin graft.

Case Vignette 1

A 49-year-old Caucasian male presented in September 2021 with a lesion on the right nasal sidewall (Figure 3A). The lesion was biopsied and revealed BCC with an infiltrative pattern. Six years prior, the patient had received 3 excisions for BCC, with incomplete excisions each time. In 2021, the patient underwent Mohs surgery to resect the BCC lesion, with a pre-operative site spanning 30x25 mm. The patient underwent 5 stages of Mohs, with the depth reaching the muscle (Figure 3B). The final defect measured 57x47 mm and was repaired with a combination of a Rhomboid transposition flap, a Webster transposition flap, and a full-thickness skin graft (Figure 3C).

This patient had multiple recurrences of his BCC, and at the time of his initial Mohs resection it was noted that he would likely have recurrence despite clearance. Given that the patient is at high risk of recurrence, he was considered for currently approved HHIs and PD-1 inhibitors.

An MRI showed questionable mild prominence of leptomeningeal enhancement. The patient was started on the HHI vismodegib and experienced loss of taste, hair loss, and cramps. He was ultimately unable to continue treatment with vismodegib due to side effects, including severe thirst, muscle cramps, fatigue, and taste alteration. The patient then presented with a lesion on the right medial canthus suggestive of recurrence (Figure 4A), with the biopsy revealing a BCC lesion. Mohs was performed in September 2022; however, it was stopped after 2 stages and deemed unresectable due to perineural invasion (Figure 4B).



A B

Figure 4. (**A**) The patient presented with a recurrence of BCC on the right medial canthus. (**B**) The patient underwent Mohs. However, the surgery was halted, and the carcinoma was deemed unresectable due to perineural invasion.



Figure 5. The patient has received PD-1 inhibitor therapy every 3 weeks for 63 weeks for the treatment of aBCC and shown marked softening and thickening of the periorbital and nasal sidewall area.

The patient developed recurrence at the site 1 year later; at that time, insurance coverage was investigated and he was preauthorized for treatment with the PD-1 inhibitor cemiplimab. The patient was started on cemiplimab in July 2023; he has received infusions every 3 weeks, with 21 infusions to date. He has not reported any adverse effects while on this PD-1 inhibitor and has shown marked softening and thickening of the periorbital and nasal sidewall area (Figure 5).

Infusion of cemiplimab is straightforward and relatively short, and the most essential component in starting a patient on an infusion medication is obtaining insurance authorization. Appropriate documentation and billing of the infusions are mandatory so that reimbursement can be obtained with off-label utilization not being an option.



A B C D

Figure 6. Upon presentation, the patient underwent 4 biopsies. (**A**) The first was diagnosed as nodular and infiltrative BCC on the left superior posterior neck. (**B**) The second biopsy was diagnosed as nodular BCC on the left superior postauricular skin arising from a previous surgical scar. (**C**) The third biopsy was diagnosed as nodular and infiltrative BCC on the right superior lateral buccal cheek. (**D**) The fourth biopsy was diagnosed as nodular and infiltrative BCC on the right scapha.

Case Vignette 2

A 70-year-old male presented with 29 skin lesions throughout the body. The patient had a history of BCC 3 years prior. The patient currently uses a tanning salon but reports no tobacco or alcohol use. Upon presentation, the patient underwent 4 biopsies that were diagnosed as nodular and infiltrative BCC on the left superior posterior neck (Figure 6A), nodular BCC on the left superior postauricular skin arising from a previous surgical scar (Figure 6B), nodular and infiltrative BCC on the right superior lateral buccal cheek (Figure 6C), and nodular and infiltrative BCC on the right scapha (Figure 6D).

Mohs surgery was performed on the infiltrative BCC on the left superior posterior neck (Figure 7).

The patient deferred biopsies on the remaining 25 lesions and was scheduled for Mohs surgery on the 3-remaining biopsied BCCs. He was considered for treatment with the HHI sonidegib for frequent BCCs and was ordered a complete metabolic panel (CMP), complete blood count (CBC) with differentials, and total creatine kinase (CK) as well as L-carnitine 1500 mg daily to prevent muscle cramps. The various treatment options were reviewed with the patient, including Mohs surgery, excision, electro-dissection and curettage, radiation therapy, HHIs, various topical therapies, and PD-1 inhibitors. The patient ultimately declined treatment and has been resistant to continue screenings and assessments due to surgery fatigue and difficulty of treatment.

Patients with aBCC or aCSCC may be faced with multiple biopsies and surgeries to support their treatment. "Surgery fatigue," as illustrated with this patient, results in a patient being unwilling to continue treatment, even when less-invasive, promising options are presented. When a patient is at risk of developing surgery fatigue, whether due to a large number of lesions or the potential that the surgery will not cure the disease, targeted therapies are an alternative that should be considered before surgery fatigue occurs. ■

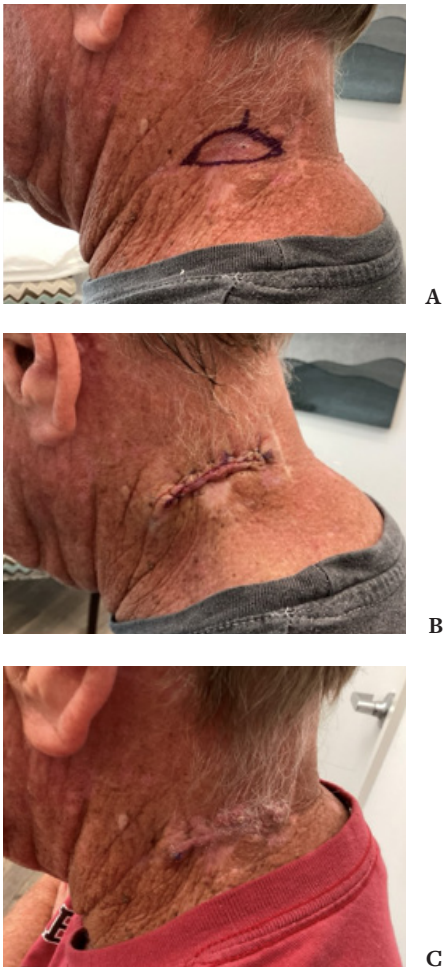

A B C

Figure 7. (**A**) The nodular and infiltrative BCC on the left superior posterior neck was assessed and biopsied. (**B**) Mohs surgery was performed to excise the lesion. (**C**) The patient returned for a follow-up visit after the excision healed.

Practical Considerations When Managing Patients With aBCC and aCSCC

1

The risk of metastasis of BCC is 0.55%, with a lymph node biopsy recommended when metastasis is suspected.[3] Despite the higher prevalence of BCC compared to CSCC, metastatic risk for CSCC patients is reported in approximately 5% of patients, and of those that metastasize, up to 80% spread to the regional lymph nodes.[5] Therefore, lymph node dissection is recommended when metastasis is suspected.[5]

2

Immunosuppressed individuals must be carefully considered, as these patients are at high risk for aBCC and aCSCC.[1,2,34] Individuals who have received a solid organ transplant, those with human immunodeficiency virus (HIV) infection, or those with a hematopoietic stem cell transplant are examples of high-risk individuals.[2] The majority of BCC-related deaths are due to elderly age and immunocompromised state, lending to the high risk associated with these features.[34] The duration of immunosuppression may also contribute to CSCC carcinogenesis and should be considered during risk assessment.[2]

3

Multidisciplinary consultations are recommended with patients who are at high risk for disease progression or recurrence.[1,35,36] aBCC and aCSCC are best managed with a multidisciplinary team (MDT), which may include a dermatologist, Mohs surgeon, oncologist, radiologist, plastic surgeon, nurse practitioner, and primary care provider, among others.[1,35,36]

4

Regular follow-up examinations are recommended for patients diagnosed with aBCC or aCSCC. The risk of developing CSCC or BCC is increased in patients with a history of skin cancer, including previous BCC or CSCC.[1,2] Therefore, regular routine examinations to screen for newly developed lesions are recommended to reduce disease pathology.[1,2]

Key Takeaways and Conclusions

aBCC and aCSCC require specialized treatment to properly manage and cure.[3,5] These cancers can result in permanent disfiguration, loss of function, metastasis, or death if improperly managed.[3,5]

Surgery is not always the best option for patients who may be considered advanced or complicated cases.[3,5]

Alternative treatments to surgery and radiation should be considered particularly when surgery fatigue is a possibility with a patient.[3,5] Alternative treatments can include systemic therapies, such as HHIs or immunotherapies for aBCC and immunotherapies for aCSCC.[3,5]

A multidisciplinary approach when managing patients with aBCC and aCSCC is pivotal.[1,35,36] This MDT may include a dermatologist, Mohs surgeon, medical oncologist, radiologist, plastic surgeon, nurse practitioner, primary care provider, and other health care providers.[1] Side effects may occur with targeted therapies, and thus an MDT is critical to address all side effects that a patient may experience.[37,38] Therefore, it is important for dermatologists to be prepared to appropriately manage any potential treatment-associated side effects that may occur with targeted therapies, including infusion therapies.[37,38]

References

1. McDaniel B, Badri T, Steele RB. Basal Cell Carcinoma. In: StatPearls. Treasure Island (FL): StatPearls Publishing; March 13, 2024. https://www.ncbi.nlm.nih.gov/books/NBK482439/
2. Fania L, Didona D, Di Pietro FR, et al. Cutaneous squamous cell carcinoma: From pathophysiology to novel therapeutic approaches. *Biomedicines*. 2021;9(2):171. Published 2021 Feb 9. doi:10.3390/biomedicines9020171
3. Alkassis S, Shatta M, Wong DJ. Therapeutic advances in advanced basal cell carcinoma. *Cancers* (*Basel*). 2024;16(17):3075. Published 2024 Sep 4. doi:10.3390/cancers16173075
4. Verkerk K, Geurts BS, Zeverijn LJ, et al. Cemiplimab in locally advanced or metastatic cutaneous squamous cell carcinoma: prospective real-world data from the DRUG Access Protocol. *Lancet Reg Health Eur*. 2024;39:100875. Published 2024 Mar 5. doi:10.1016/j.lanepe.2024.100875
5. Caudill J, Thomas JE, Burkhart CG. The risk of metastases from squamous cell carcinoma of the skin. *Int J Dermatol*. 2023;62(4):483-486. doi:10.1111/ijd.16164
6. Geidel G, Heidrich I, Kött J. et al. Emerging precision diagnostics in advanced cutaneous squamous cell carcinoma. *NPJ Precis Oncol*. 2022;6(1):17. Published 2022 Mar 23. doi:10.1038/s41698-022-00261-z
7. Vergara IA, Aivazian K, Carlino MS, et al. Genomic profiling of metastatic basal cell carcinoma reveals candidate drivers of disease and therapeutic targets. *Mod Pathol*. 2023;36(4):100099. doi:10.1016/j.modpat.2023.100099
8. Duarte AF, Sousa-Pinto B, Haneke E, Correia O. Risk factors for development of new skin neoplasms in patients with past history of skin cancer: A survival analysis. *Sci Rep*. 2018;8(1):15744. Published 2018 Oct 24. doi:10.1038/s41598-018-33763-7
9. Niebel D, Sirokay J, Hoffmann F, Fröhlich A, Bieber T, Landsberg J. Clinical management of locally advanced basal-cell carcinomas and future therapeutic directions. *Dermatol Ther* (*Heidelb*). 2020;10(4):835-846. doi:10.1007/s13555-020-00382-y
10. Brancaccio G, Briatico G, Pellegrini C, Rocco T, Moscarella E, Fargnoli MC. Risk factors and diagnosis of advanced cutaneous squamous cell carcinoma. *Dermatol Pract Concept*. 2021;11(Suppl 2):e2021166S. doi:10.5826/dpc.11S2a166S
11. Li X, Wang H, Lu Q. Immunotherapy for locally advanced and metastatic basal cell carcinoma: a narrative review. *Transl Cancer Res*. 2024;13(11):6565-6575. doi:10.21037/tcr-24-742
12. Singh G, Tolkachjov SN, Farberg AS. Incorporation of the 40-gene expression profile (40-GEP) test to improve treatment decisions in high-risk cutaneous squamous cell carcinoma (cSCC) patients: case series and algorithm. *Clin Cosmet Investig Dermatol*. 2023;16:925-935. doi:10.2147/CCID.S403330
13. Nawrocka PM, Galka-Marciniak P, Urbanek-Trzeciak MO, et al. Profile of basal cell carcinoma mutations and copy number alterations - focus on gene-associated non-coding variants. *Front Oncol*. 2021;11:752579. Published 2021 Nov 25. doi:10.3389/fonc.2021.752579
14. Lipson EJ, Lilo MT, Ogurtsova A, et al. Basal cell carcinoma: PD-L1/PD-1 checkpoint expression and tumor regression after PD-1 blockade. *J Immunother Cancer*. 2017;5:23. Published 2017 Mar 21. doi:10.1186/s40425-017-0228-3
15. Tang Q, Chen Y, Li X, et al. The role of PD-1/PD-L1 and application of immune-checkpoint inhibitors in human cancers. *Front Immunol*. 2022;13:964442. Published 2022 Sep 13. doi:10.3389/fimmu.2022.964442
16. Slater NA, Googe PB. PD-L1 expression in cutaneous squamous cell carcinoma correlates with risk of metastasis. *J Cutan Pathol*. 2016;43(8):663-670. doi:10.1111/cup.12728
17. García-Díez I, Hernández-Ruiz E, Andrades E, et al. PD-L1 expression is increased in metastasizing squamous cell carcinomas and their metastases. *Am J Dermatopathol*. 2018;40(9):647-654. doi:10.1097/DAD.0000000000001164
18. Schaper K, Köther B, Hesse K, Satzger I, Gutzmer R. The pattern and clinicopathological correlates of programmed death-ligand 1 expression in cutaneous squamous cell carcinoma. *Br J Dermatol*. 2017;176(5):1354-1356. doi:10.1111/bjd.14955
19. Moreno-Ramírez D, Silva-Clavería F, Fernández-Orland A, Eiris N, Ruiz de Casas A, Férrandiz L. Surgery for cutaneous squamous cell carcinoma and its limits in advanced disease. *Dermatol Pract Concept*. 2021;11(Suppl 2):e2021167S. doi:10.5826/dpc.11S2a167S
20. Yosefof E, Kurman N, Yaniv D. The role of radiation therapy in the treatment of non-melanoma skin cancer. *Cancers* (*Basel*). 2023;15(9):2408. doi:10.3390/cancers15092408
21. Aboul-Fettouh N, Morse D, Patel J, Migden MR. Immunotherapy and systemic treatment of cutaneous squamous cell carcinoma. *Dermatol Pract Concept*. 2021;11(Suppl 2):e2021169S. doi:10.5826/dpc.11S2a169S
22. Habashy S, Jafri A, Osman HO, et al. Hedgehog pathway inhibitors: Clinical implications and resistance in the treatment of basal cell carcinoma. *Cureus*. 2021;13(3):e13859. doi:10.7759/cureus.13859
23. Referenced with permission from the NCCN Clinical Practice Guidelines in Oncology (NCCN Guidelines®) for Basal Cell Skin Cancer V.3.2024. © National Comprehensive Cancer Network, Inc. 2024. All rights reserved. Accessed December 12, 2024. To view the most recent and complete version of the guidelines, go online to NCCN.org.
24. ODOMZO. Prescribing information. Sun Pharmaceutical Industries; March 2023.
25. Erivedge. Prescribing information. Genentech; August 2023.
26. Referenced with permission from the NCCN Clinical Practice Guidelines in Oncology (NCCN Guidelines®) for Squamous Cell Skin Cancer V.1.2024. © National Comprehensive Cancer Network, Inc. 2024. All rights reserved. Accessed December 12, 2024. To view the most recent and complete version of the guidelines, go online to NCCN.org.
27. LIBTAYO. Prescribing information. Regeneron; April 2024.
28. KEYTRUDA. Prescribing information. Merck; November 2024.
29. Yin Q, Wu L, Han L, et al. Immune-related adverse events of immune checkpoint inhibitors: a review. *Front Immunol*. 2023;14:1167975. doi:10.3389/fimmu.2023.1167975.
30. Abourehab MAS, Alqahtani AM, Youssif BGM, Gouda AM. Globally approved EGFR inhibitors: Insights into their syntheses, target kinases, biological activities, receptor interactions, and metabolism. *Molecules*. 2021;26(21):6677. doi:10.3390/molecules26216677
31. Pham JP, Rodrigues A, Goldinger SM, Sim HW, Liu J. Epidermal growth factor receptor inhibitors in advanced cutaneous squamous cell carcinoma: A systematic review and meta-analysis. *Exp Dermatol*. 2024;33(1):e14978. doi:10.1111/exd.14978
32. Wilson M, Johnson RP, Senft SC, Pan EY, Krakowski AC. Advanced basal cell carcinoma: What dermatologists need to know about treatment. *J Am Acad Dermatol*. 2022;86(6S):S14-S24. doi:10.1016/j.jaad.2022.03.022
33. Konidaris G, Rofail D, Randall J, et al. Qualitative patient interviews to characterize the human burden of advanced basal cell carcinoma following hedgehog pathway inhibitor treatment. *Dermatol Ther* (*Heidelb*). 2023;13(8):1747-1761. doi:10.1007/s13555-023-00945-9
34. Krakowski AC, Hafeez F, Westheim A, Pan EY, Wilson M. Advanced basal cell carcinoma: What dermatologists need to know about diagnosis. *J Am Acad Dermatol*. 2022;86(6S):S1-S13. doi:10.1016/j.jaad.2022.03.023
35. Work Group; Invited Reviewers; Kim JYS, et al. Guidelines of care for the management of cutaneous squamous cell carcinoma. *J Am Acad Dermatol*. 2018;78(3):560-578. doi:10.1016/j.jaad.2017.10.007
36. Stanganelli I, Spagnolo F, Argenziano G, et al. The multidisciplinary management of cutaneous squamous cell carcinoma: A comprehensive review and clinical recommendations by a panel of experts. *Cancers* (*Basel*). 2022;14(2):377. doi:10.3390/cancers14020377
37. Fecher LA, Sharfman WH. Advanced basal cell carcinoma, the hedgehog pathway, and treatment options - role of smoothened inhibitors. *Biologics*. 2015;9:129-140. Published 2015 Nov 6. doi:10.2147/BTT.S54179
38. Potestio L, Scalvenzi M, Lallas A, et al. Efficacy and Safety of Cemiplimab for the Management of Non-Melanoma Skin Cancer: A Drug Safety Evaluation. *Cancers* (*Basel*). 2024;16(9):1732. Published 2024 Apr 29. doi:10.3390/cancers16091732