

# Extreme IO

Dr Thierry de Baère

Dr Frédéric Deschamps

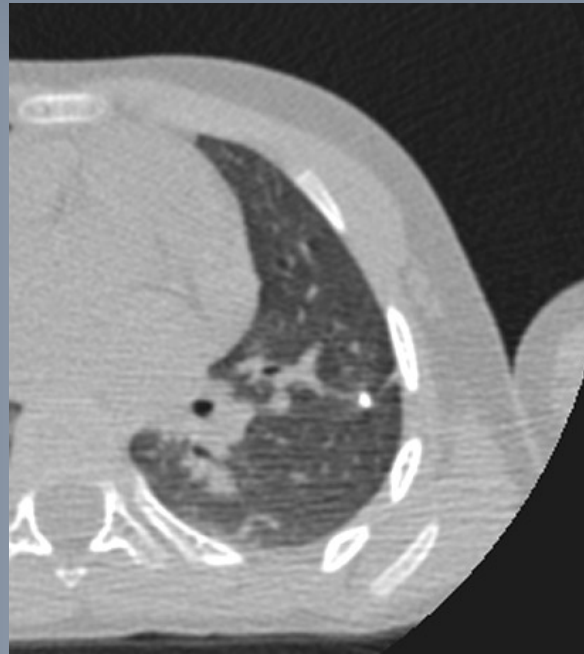
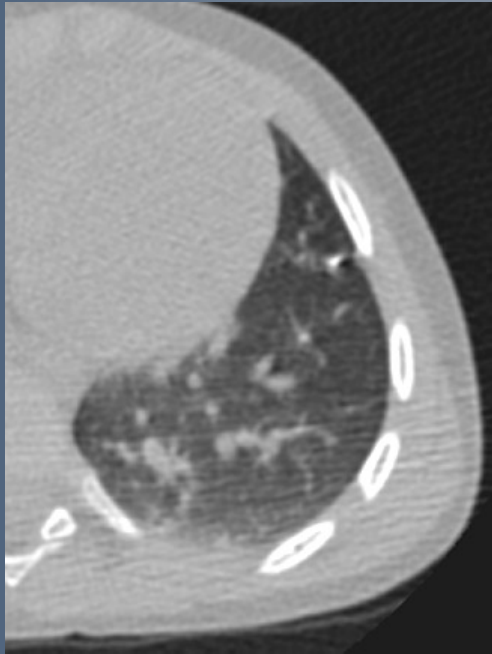


- 4 year old , 16 kg
- Hepatoblastoma Stage IV + 2 lung metastases

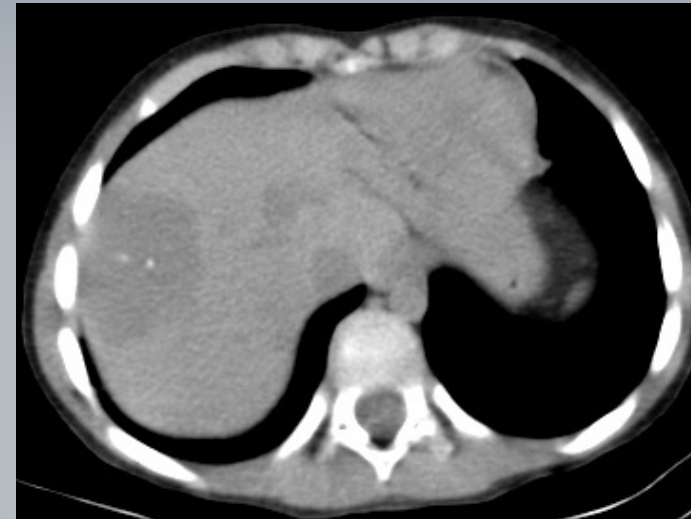# Beyond the evidence

with 4 year old.....

- 4 year old , 16 kg
- Hepatoblastoma Stage IV + 2 lung metastases
- Received chemotherapy + Surgery for lung metastases



Lung metastases from hepatoblastoma at pathology



CT before liver resection + **12 new lung metastases**

- 4 year old , 16 kg
  - Hepatoblastoma Stage IV + 2 lung metastases
  - Received chemotherapy + Surgery for lung metastases
  - **+ 12 new lung metastases**
  - carboplatin –doxorubicin, changed for Vincristin-Cisplatin-CPT11
- >>>>> Stable Disease at 6 months

- Multidisciplinary staff:
  - Resection liver tumour
  - After complete resection of lung mets

Secretion of Hepatic Growth Factors after surgery  
increases size of the metastases ?



von Schweinitz D. Eur J Pediatr Surg. 1998

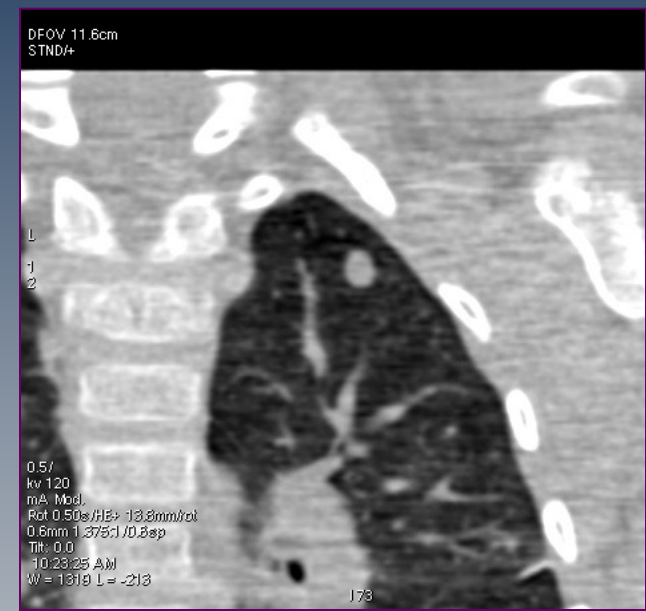
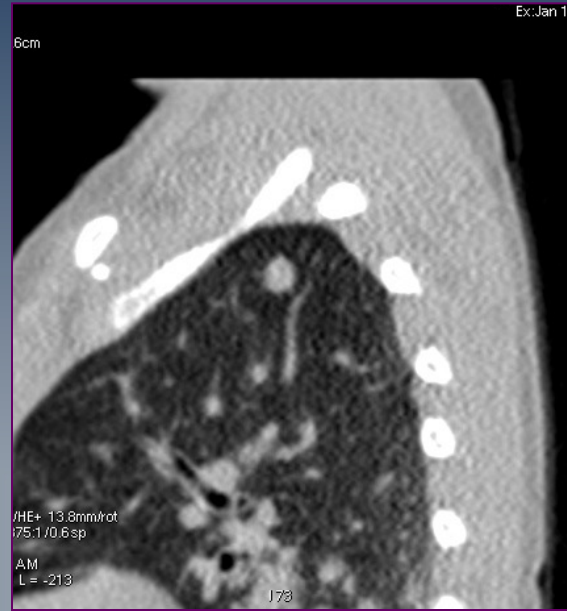
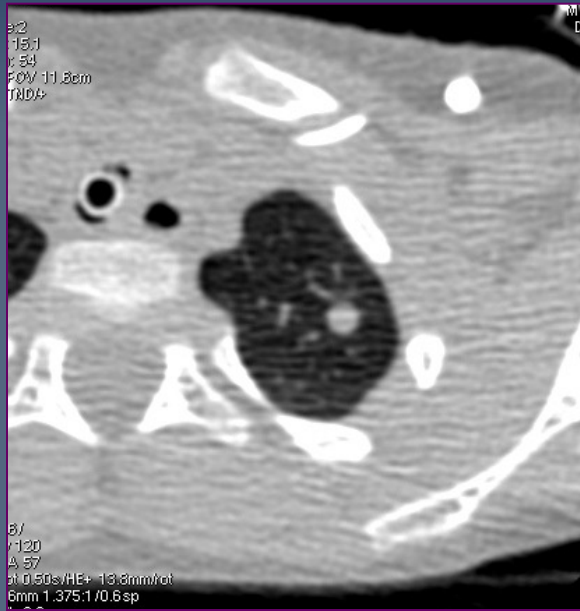von Schweinitz D. Int J Cancer. 2000

- 4 year old , 16 kg
- Hepatoblastoma Stage IV + 2 lung metastases
- Received chemotherapy + Surgery for lung metastases
- **+ 12 new lung metastases**
  - 4 mets in right lung
  - 8 mets left lung


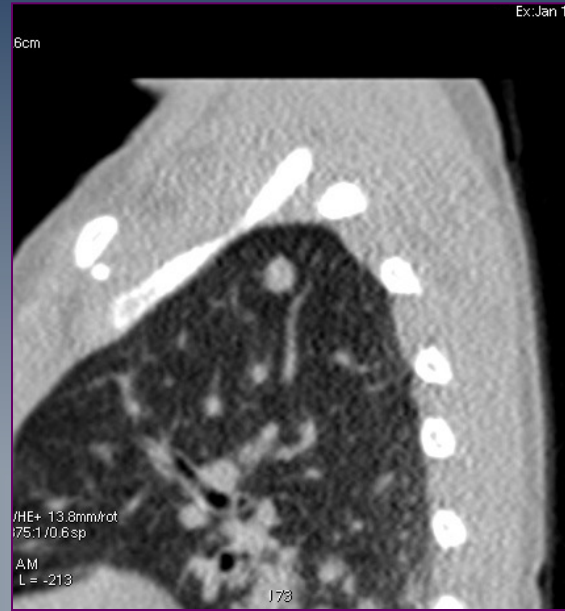
RFA preferred to surgery

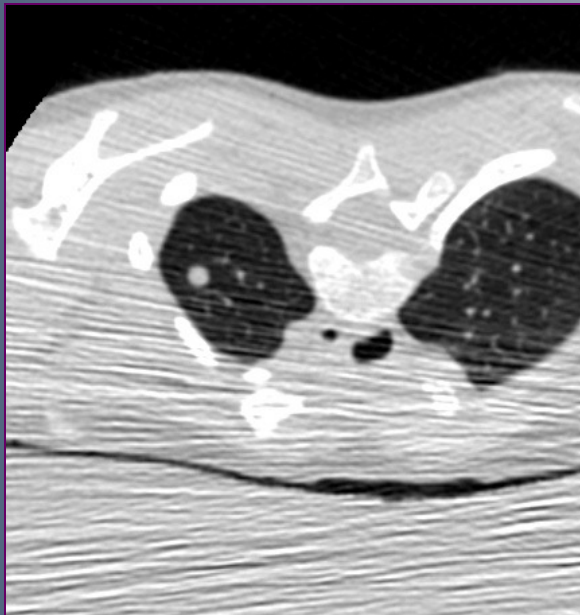
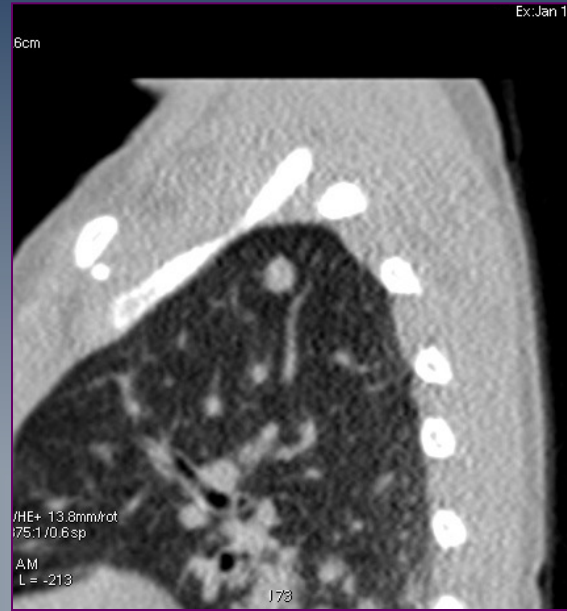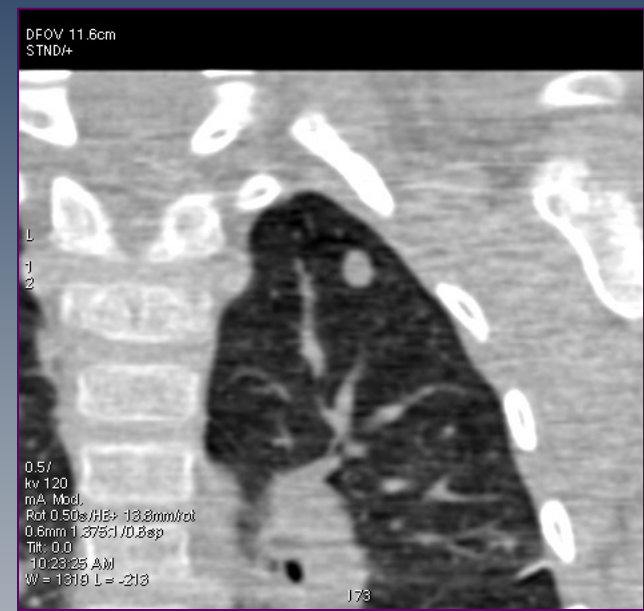


- Minimal invasive technique >>> short delay to liver resection
- 3-8 mm in diameter (high efficacy)

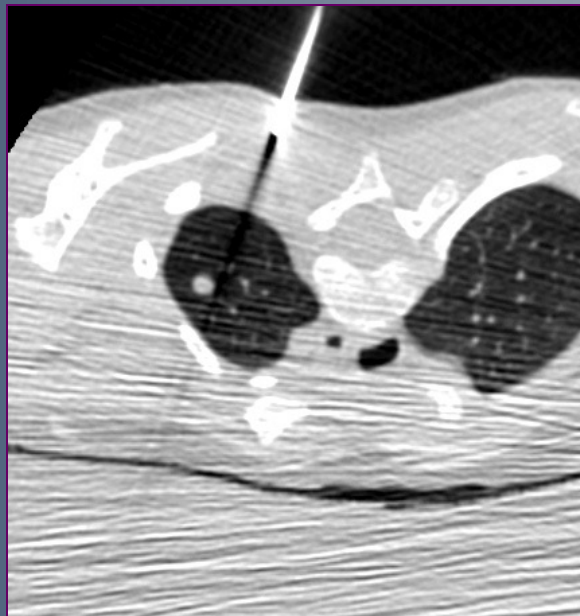
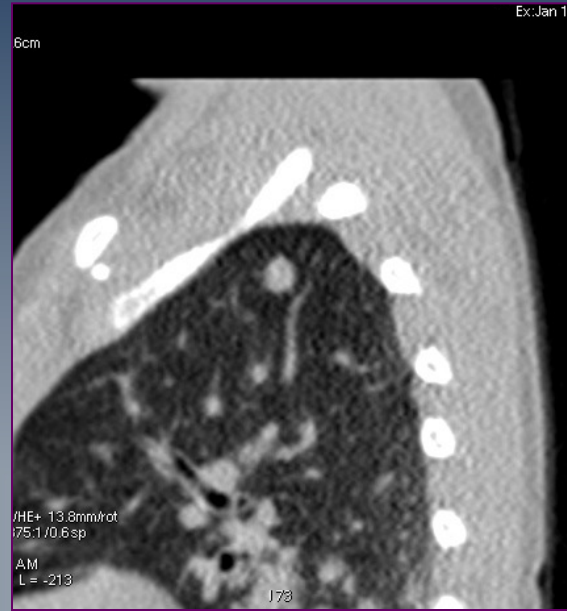


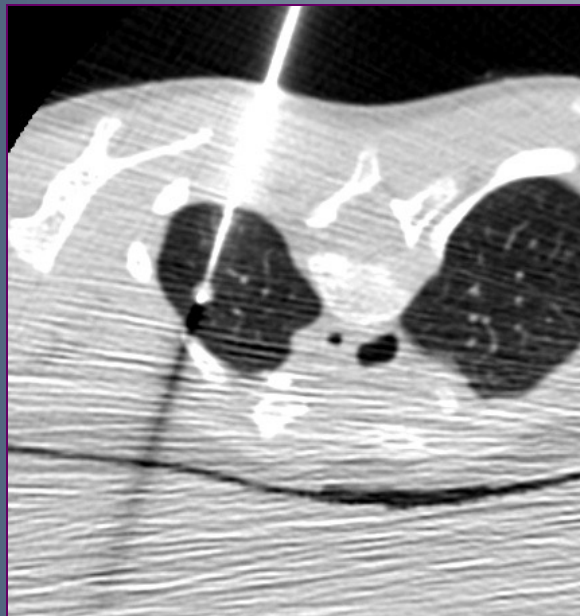
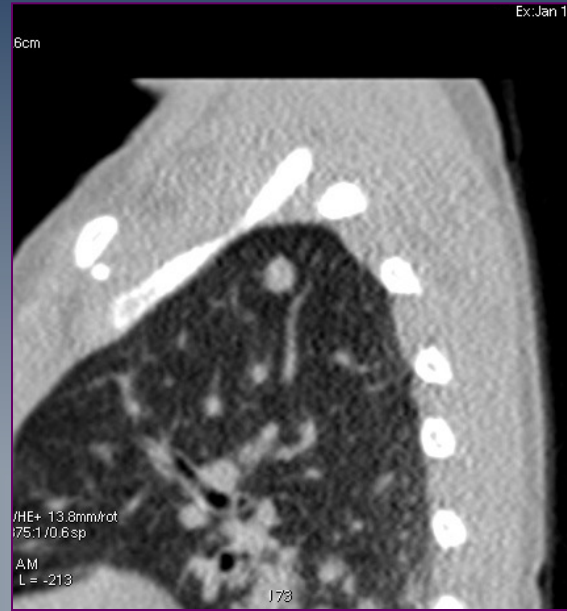


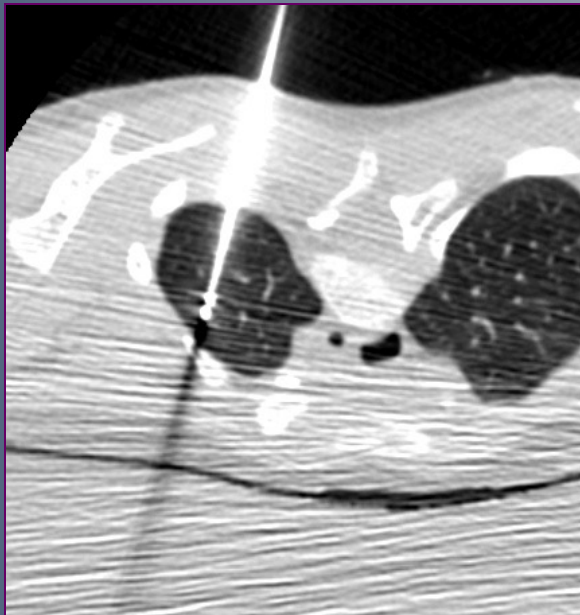
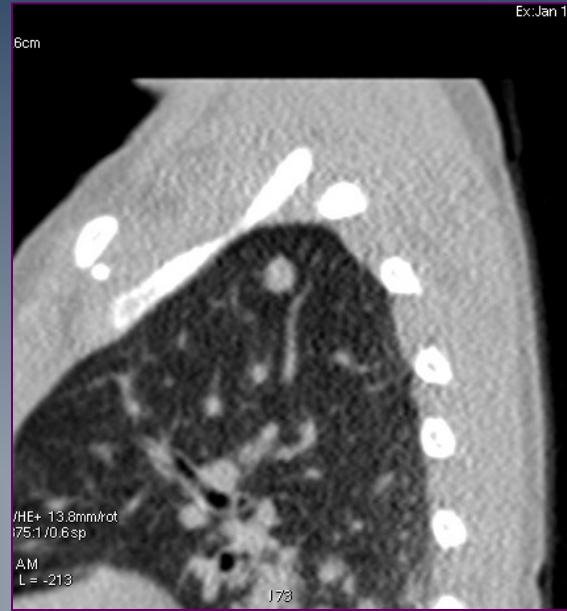




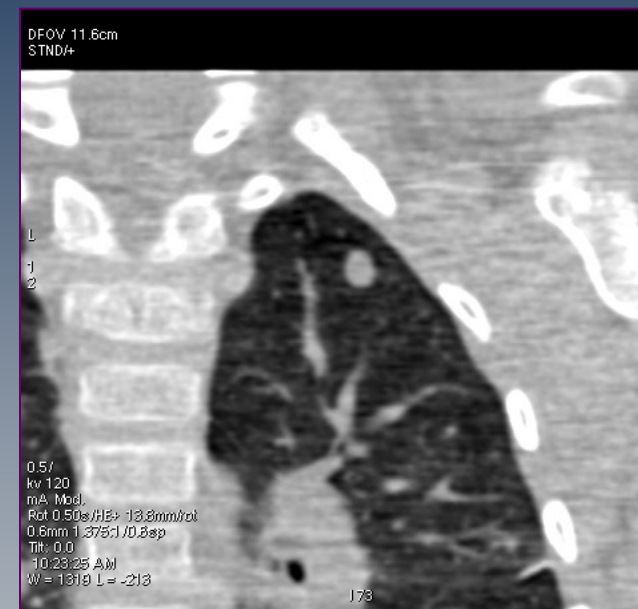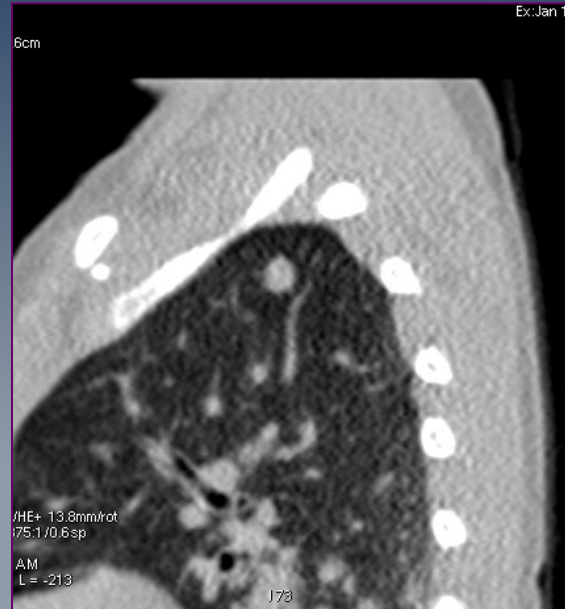
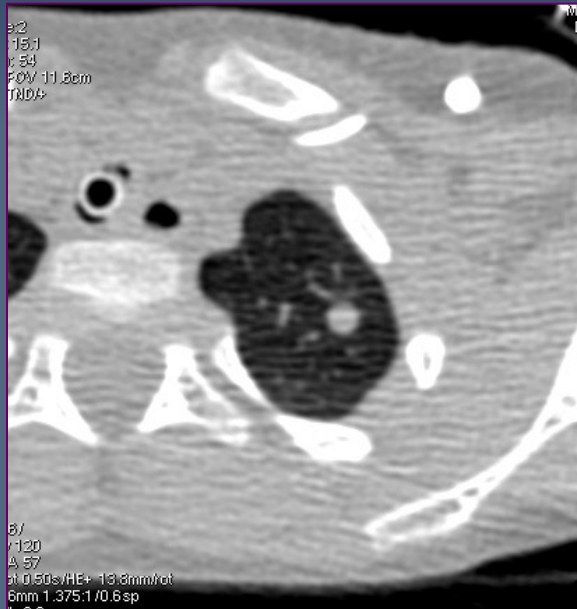




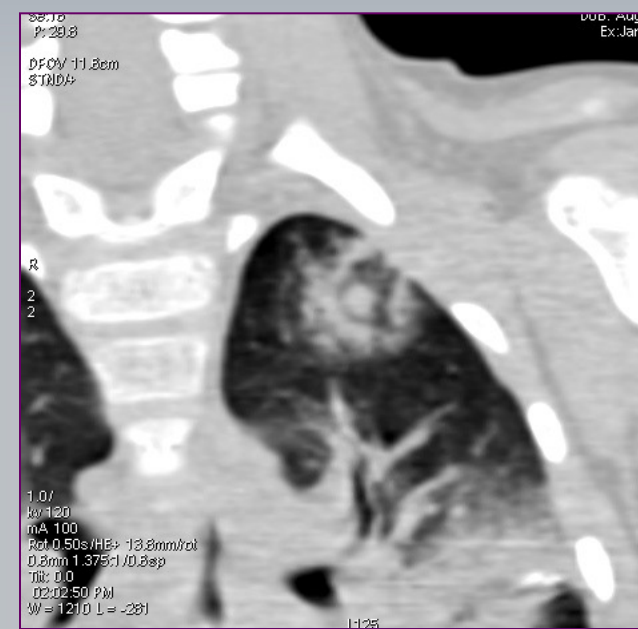




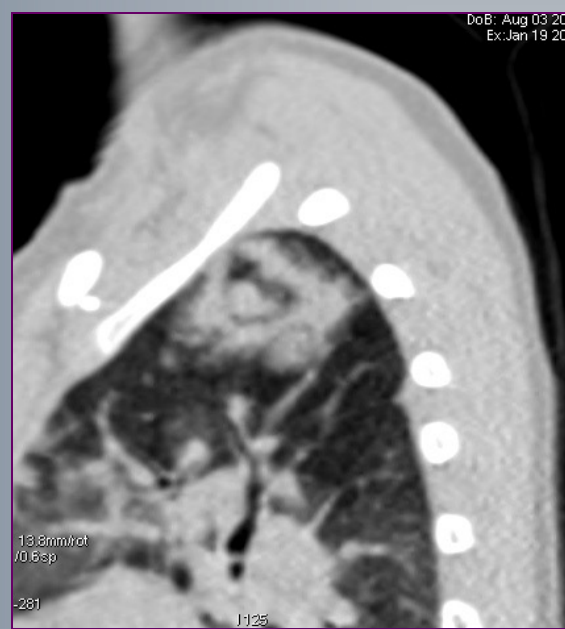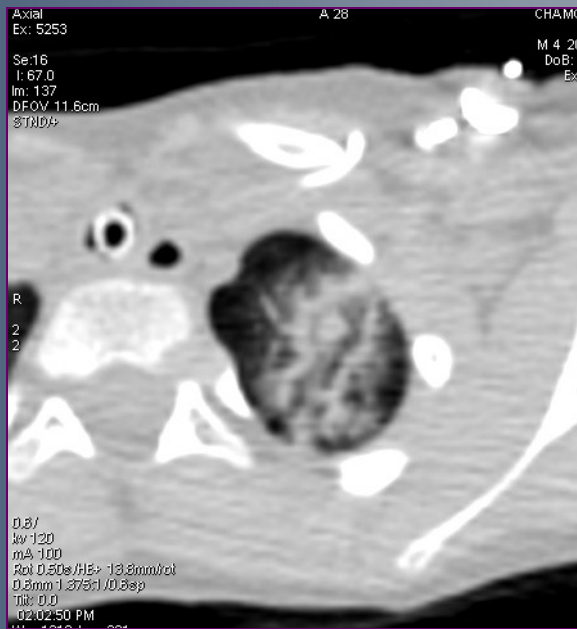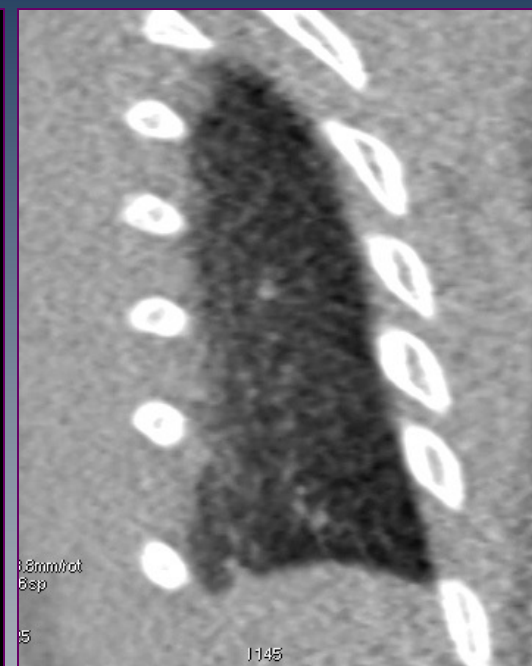
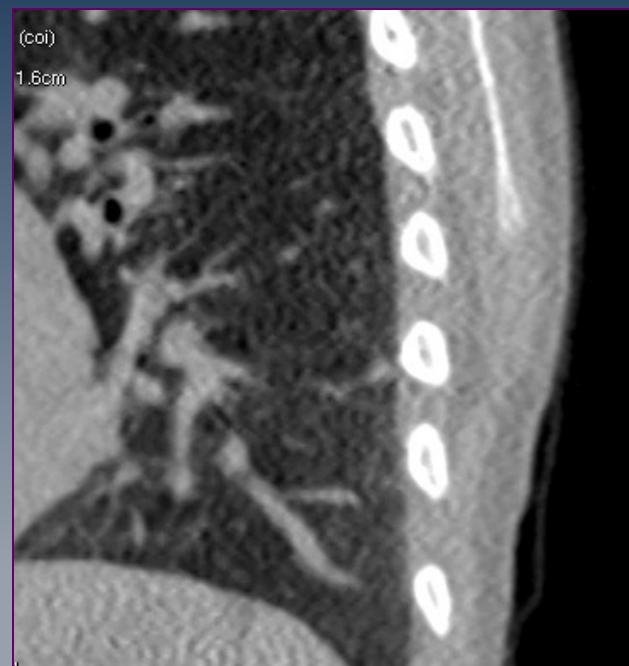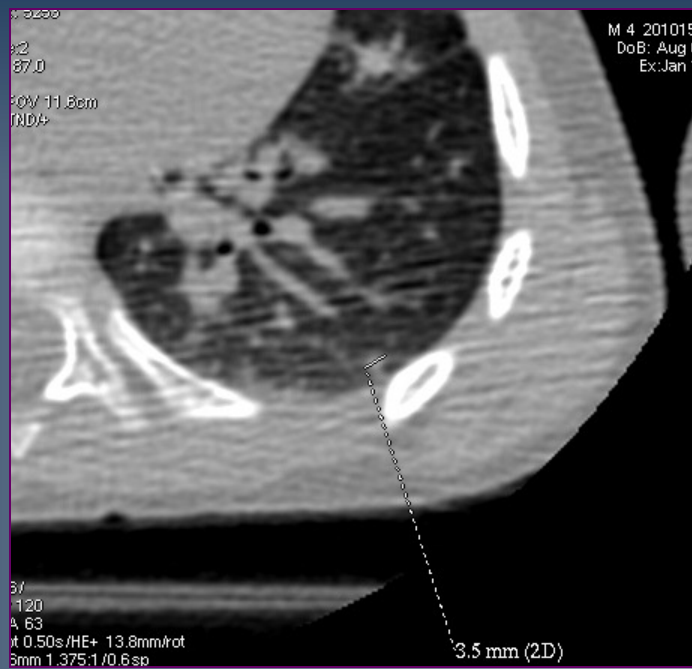




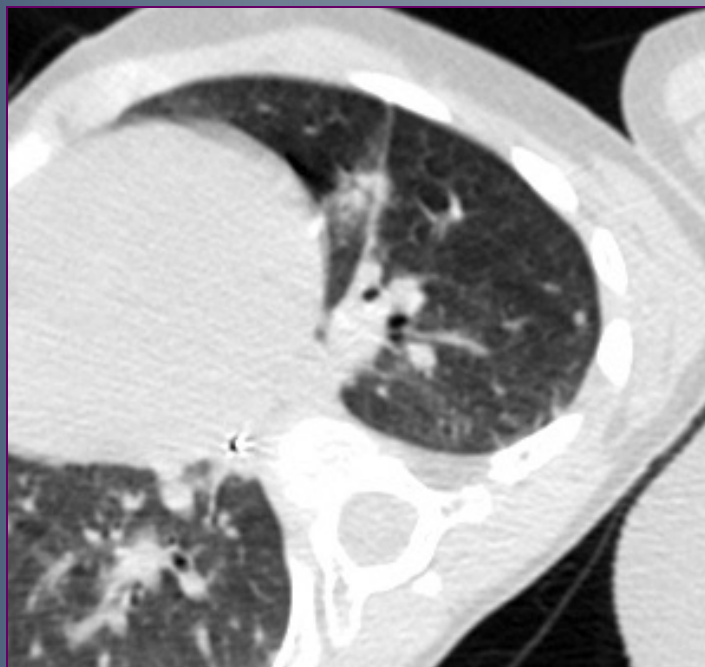
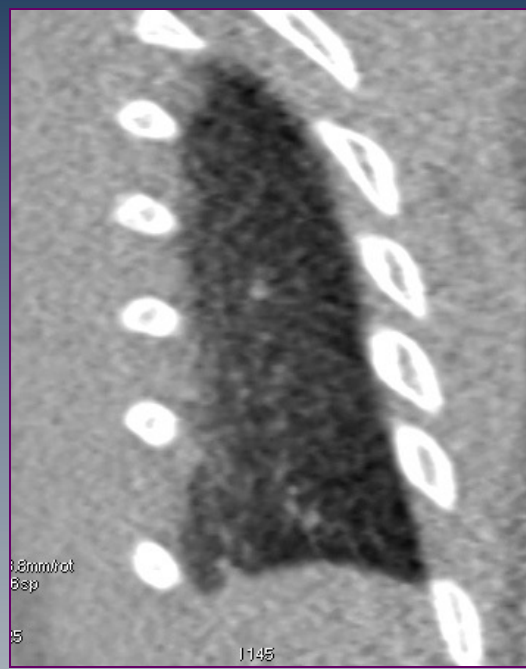
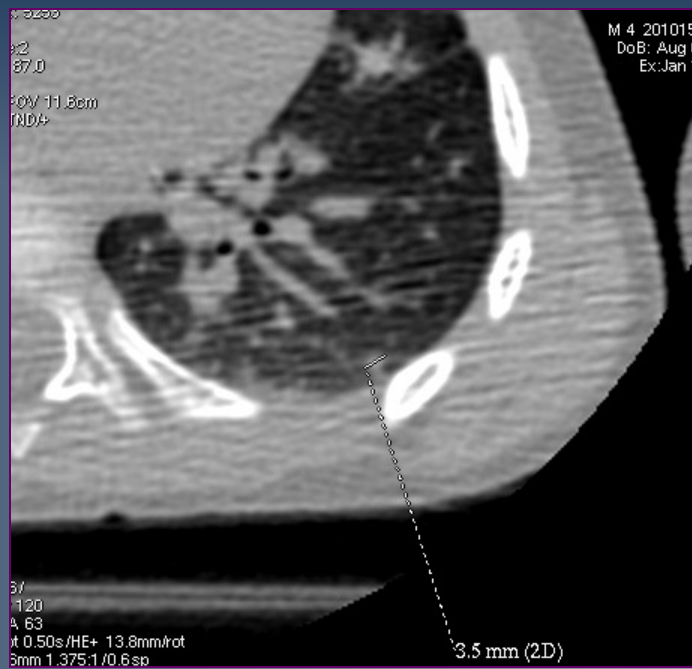
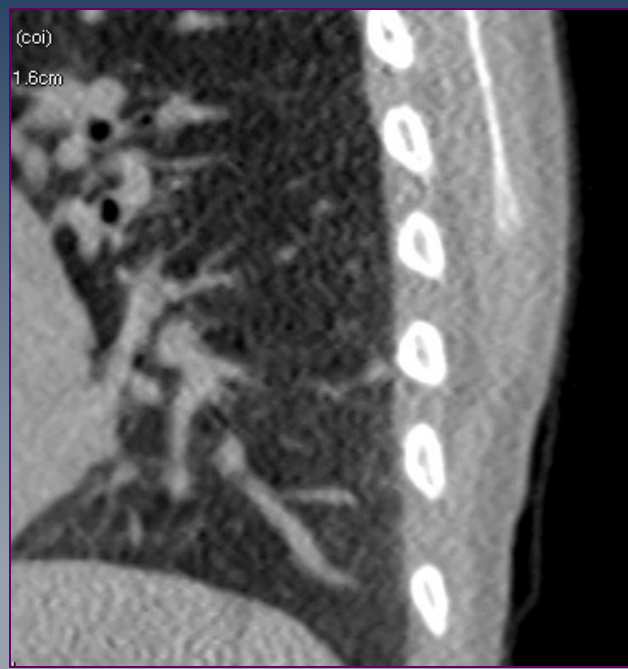6 minutes (2' 20W, 2' 40 W, 2' 60W)

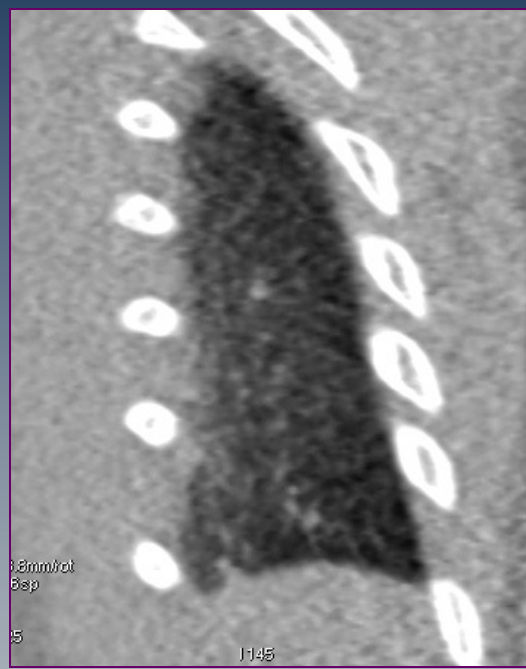
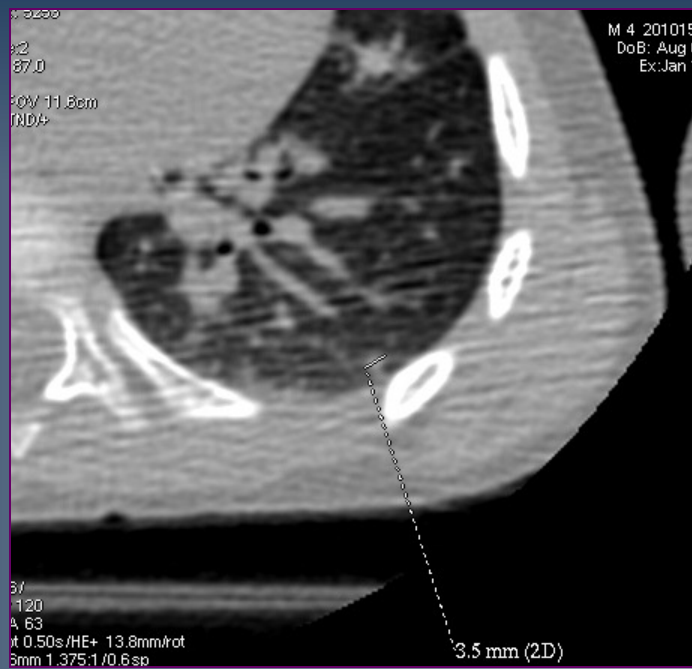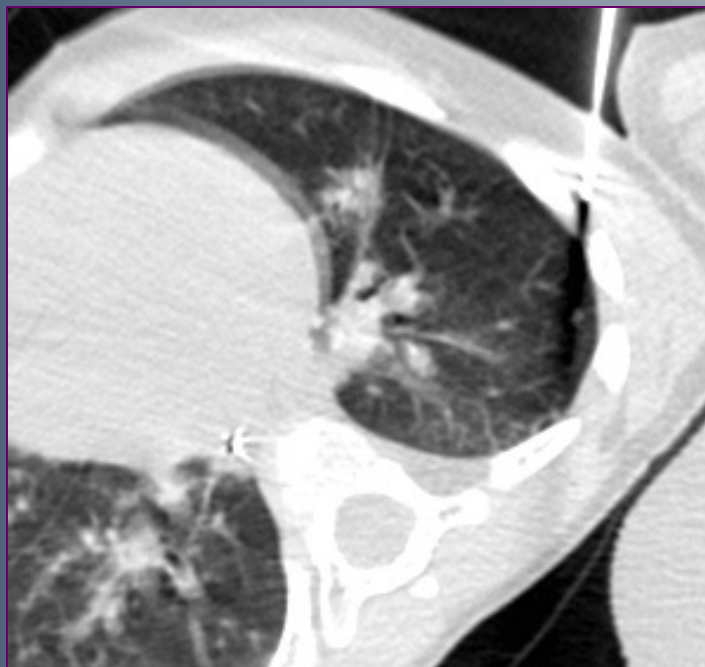


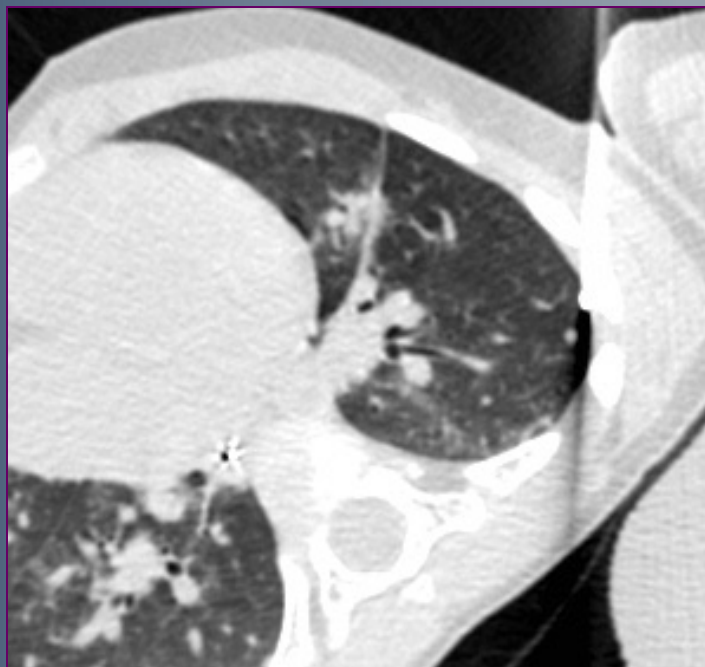
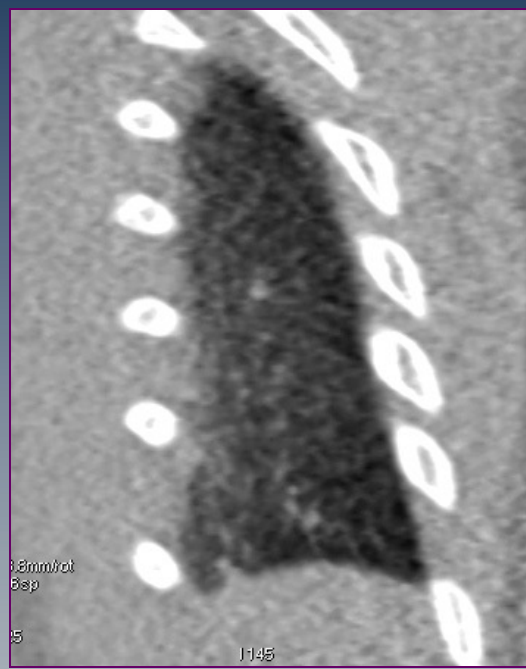
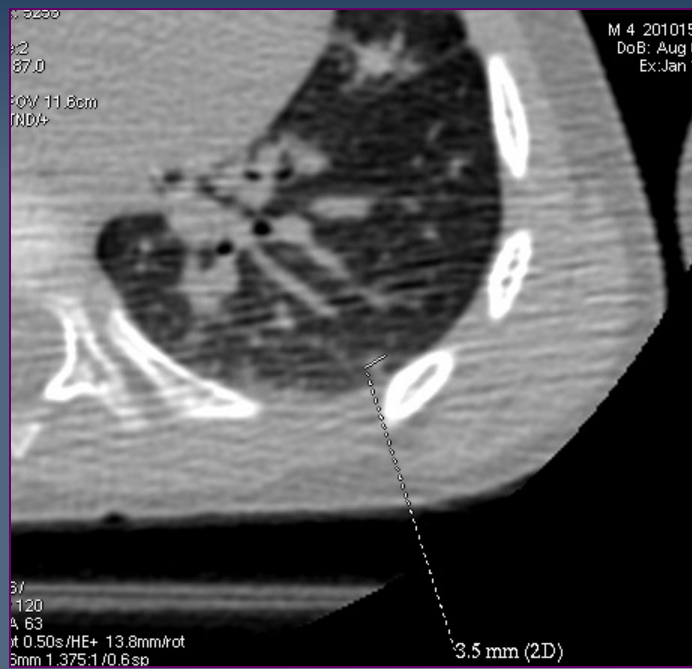
Penumbra of ground glass opacification around the tumour

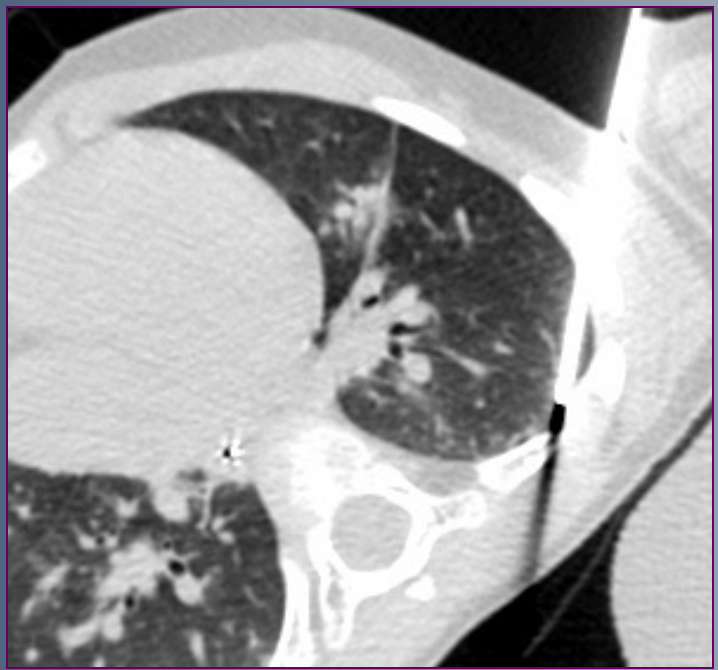
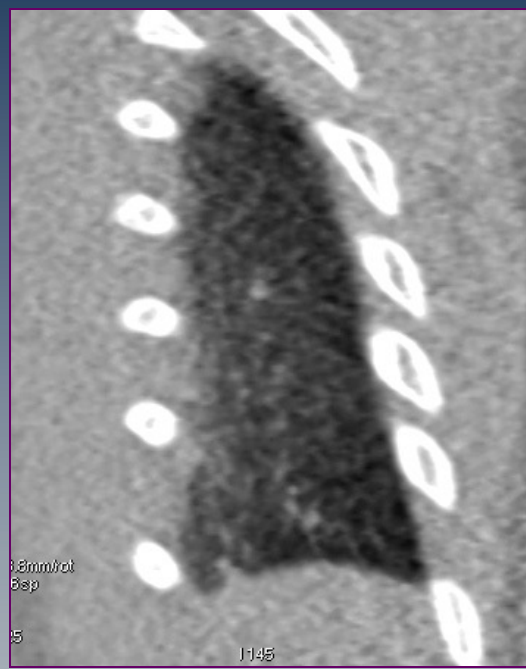
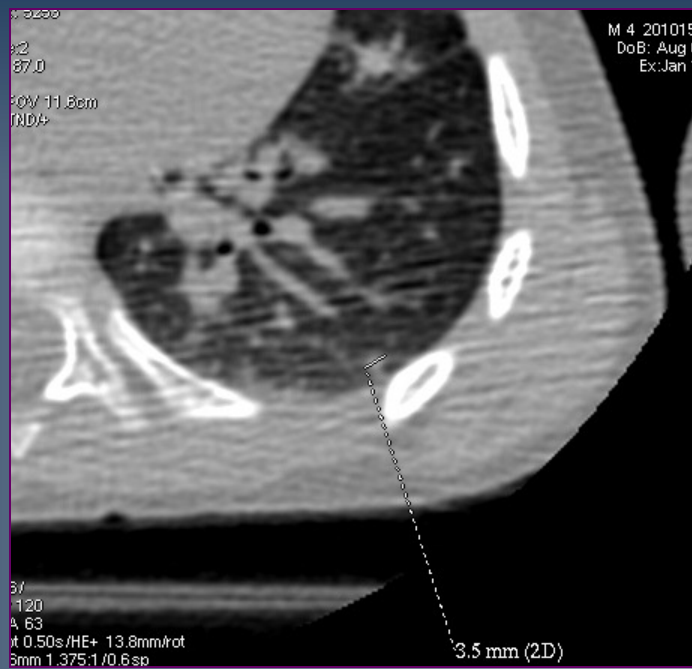




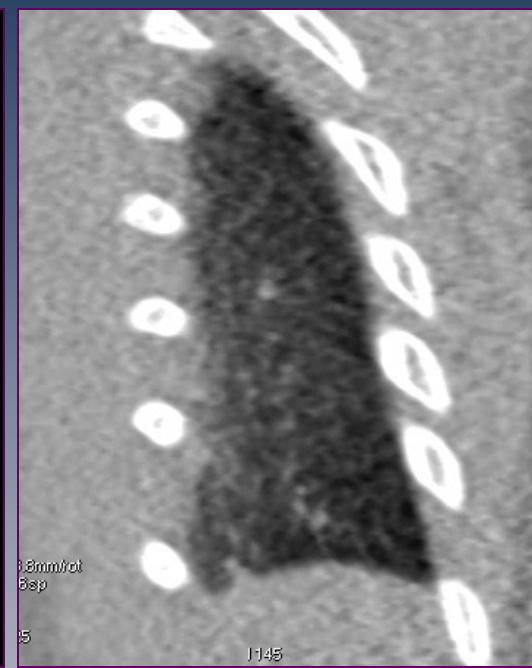
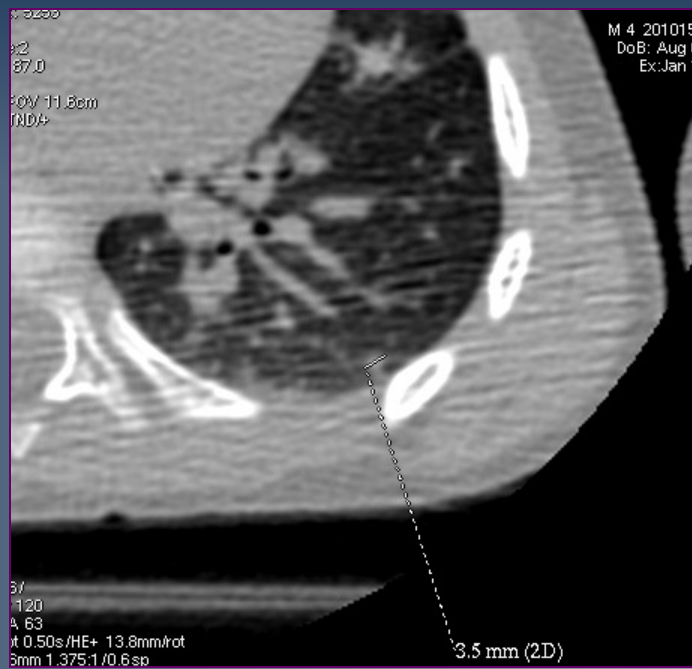
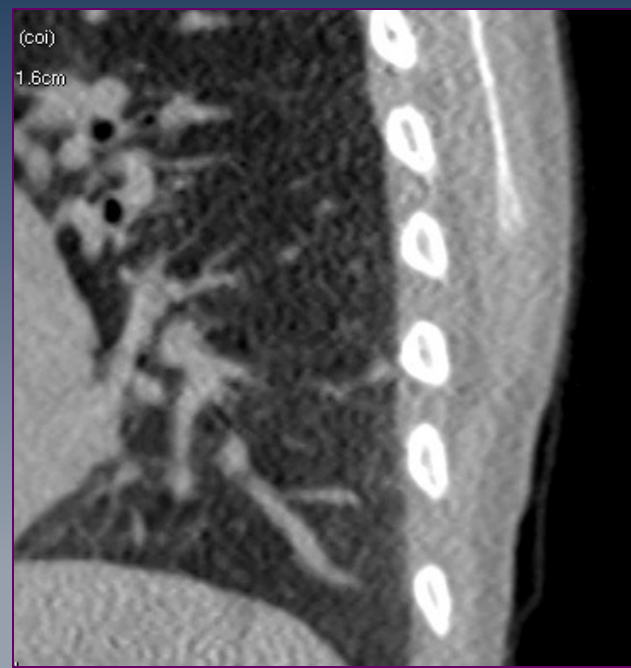



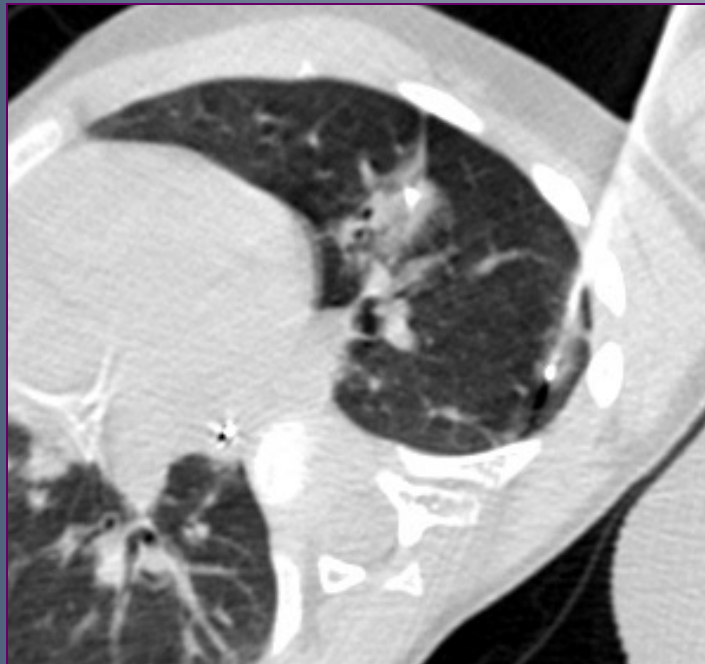




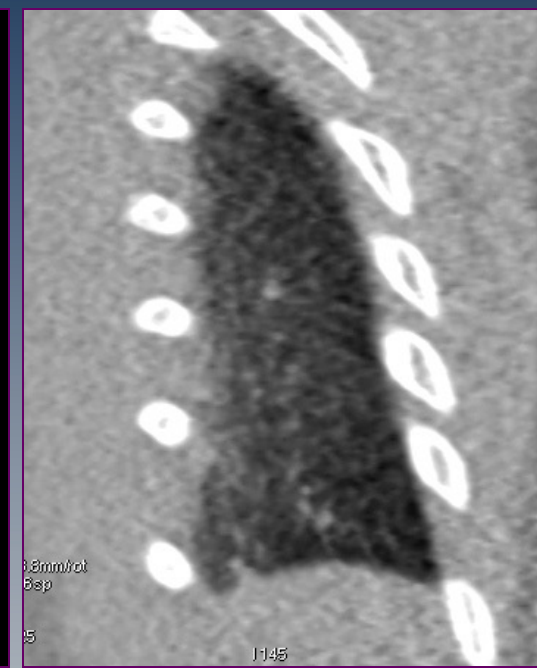
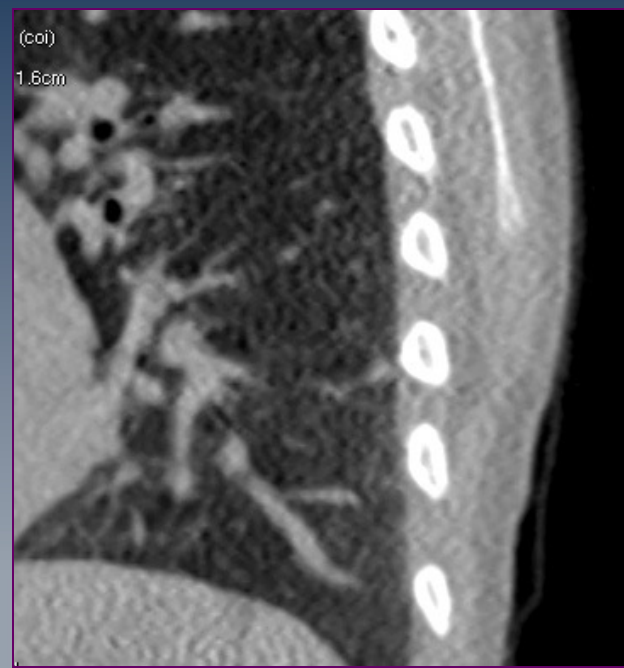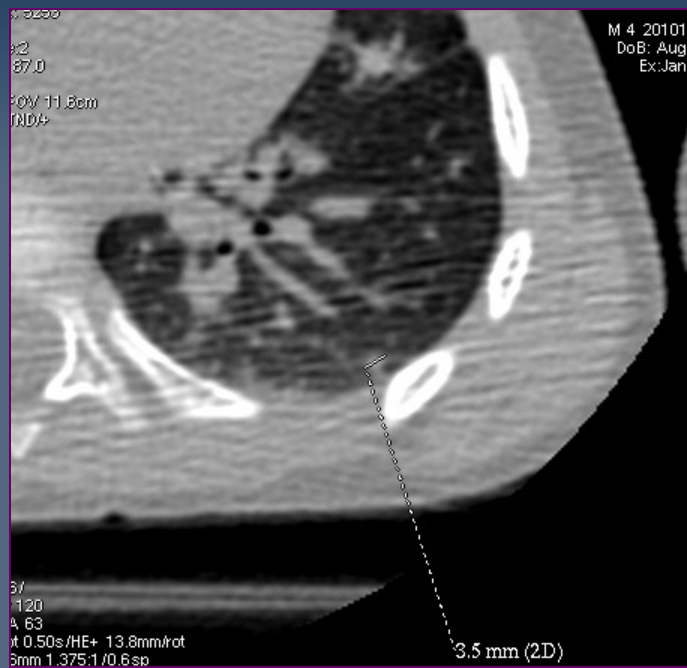




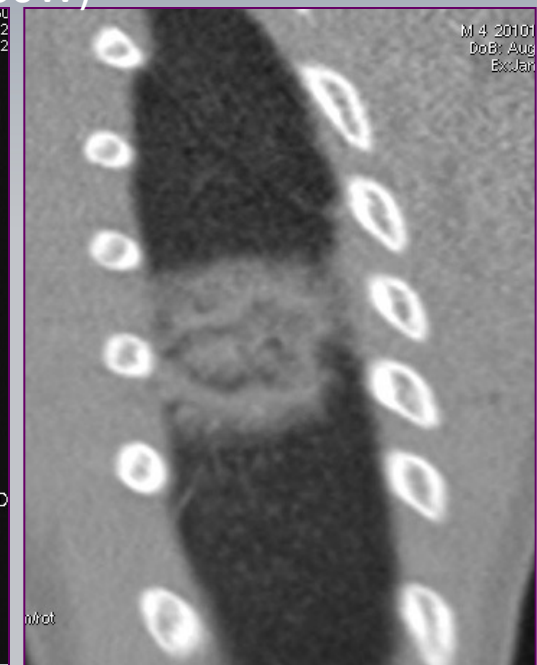
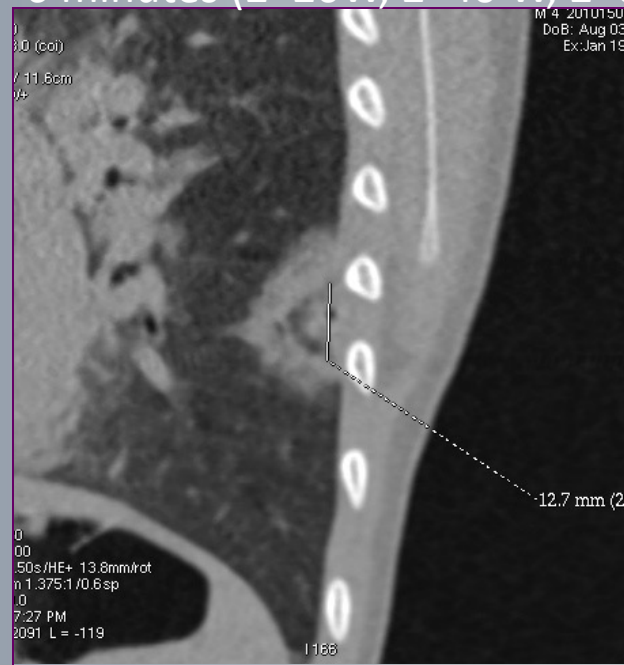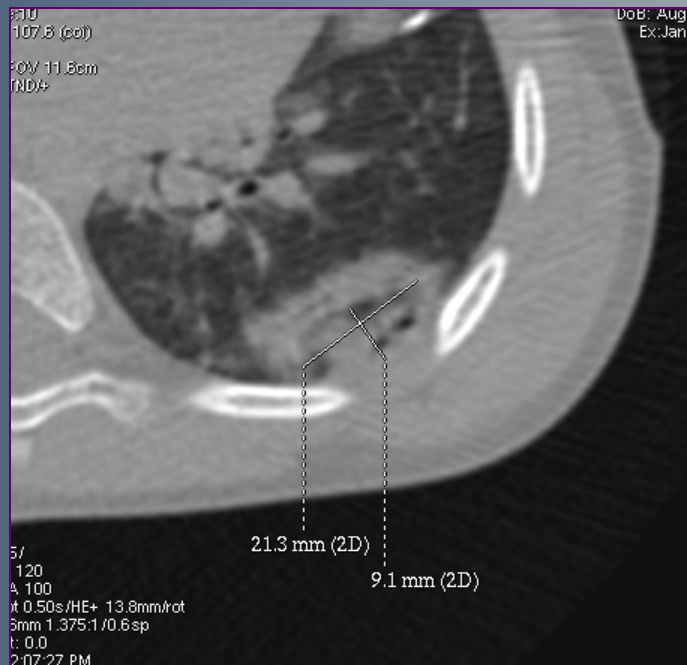6 minutes (2' 20W, 2' 40 W, 2' 60W)



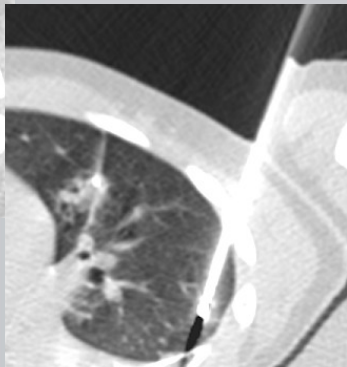
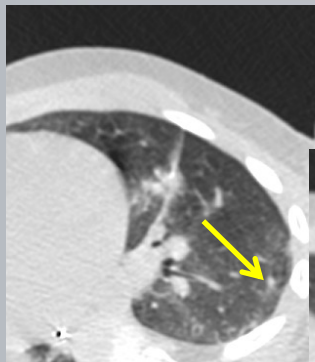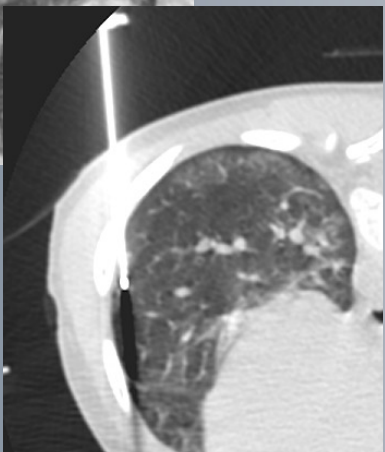
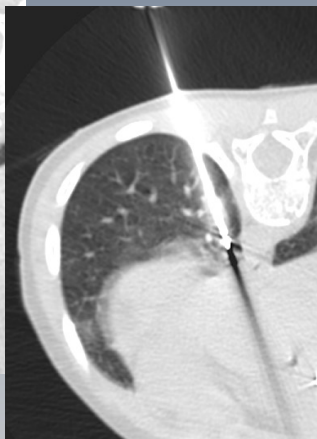
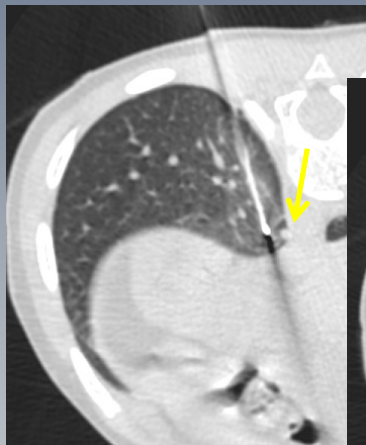
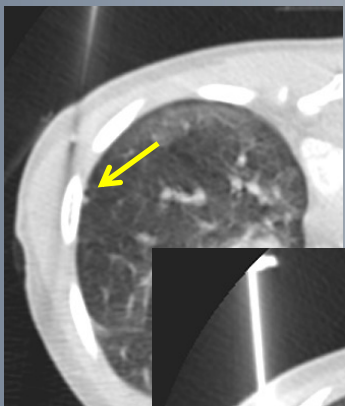
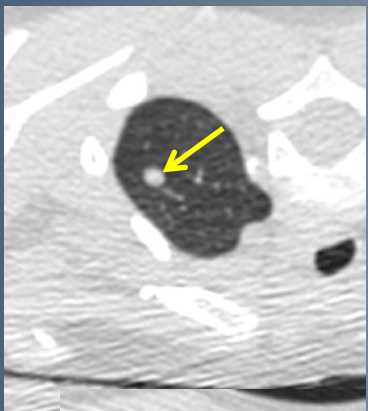
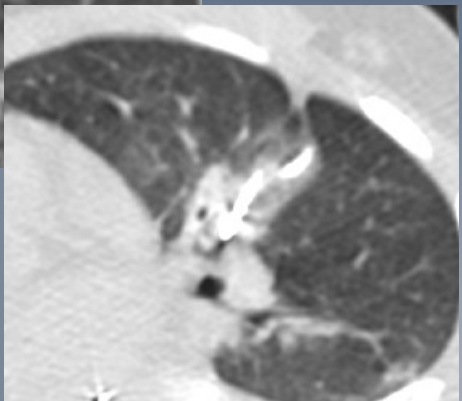
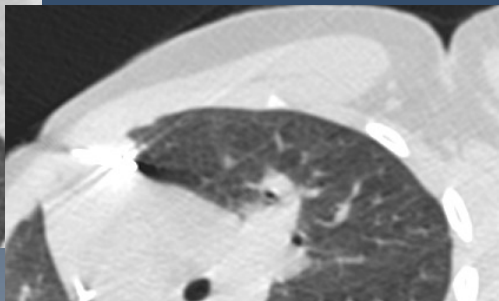
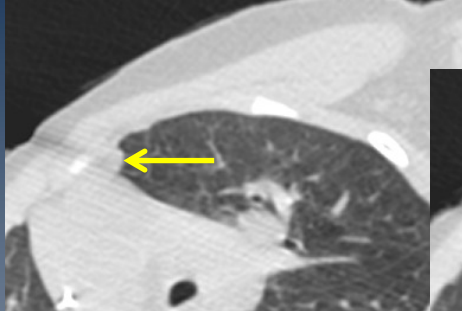
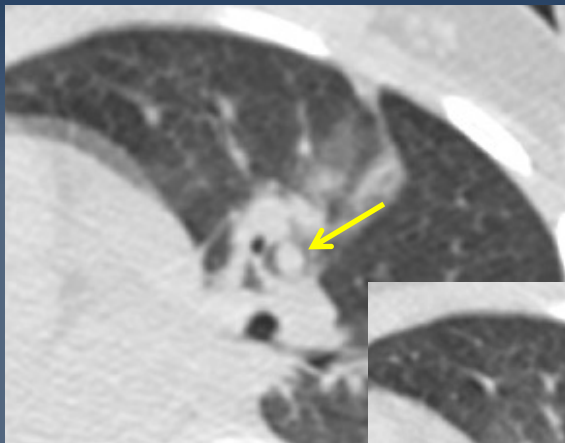




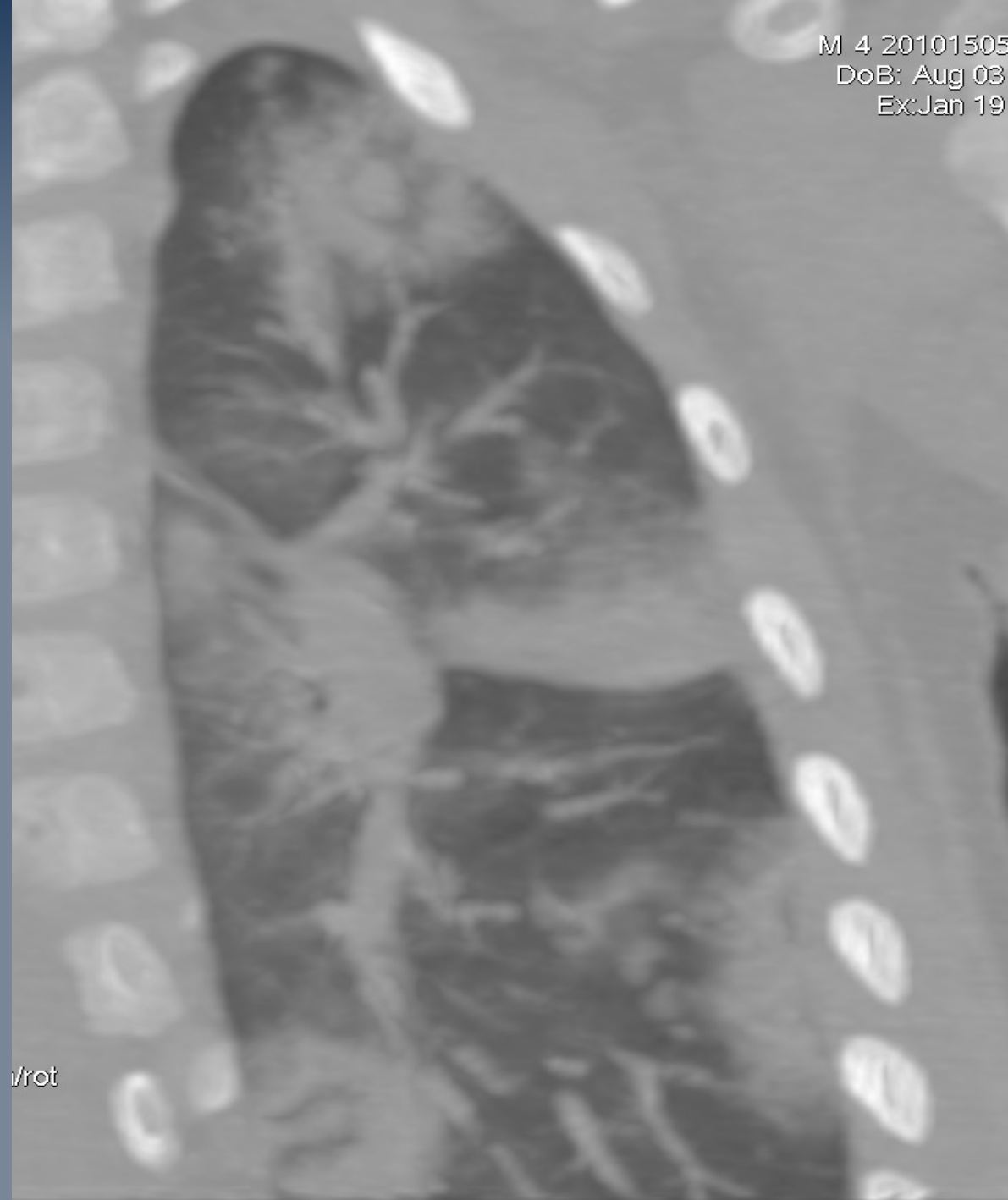
6 minutes (2' 20W, 2' 40 W, 2' 60W)



Penumbra of ground glass opacification around the tumour

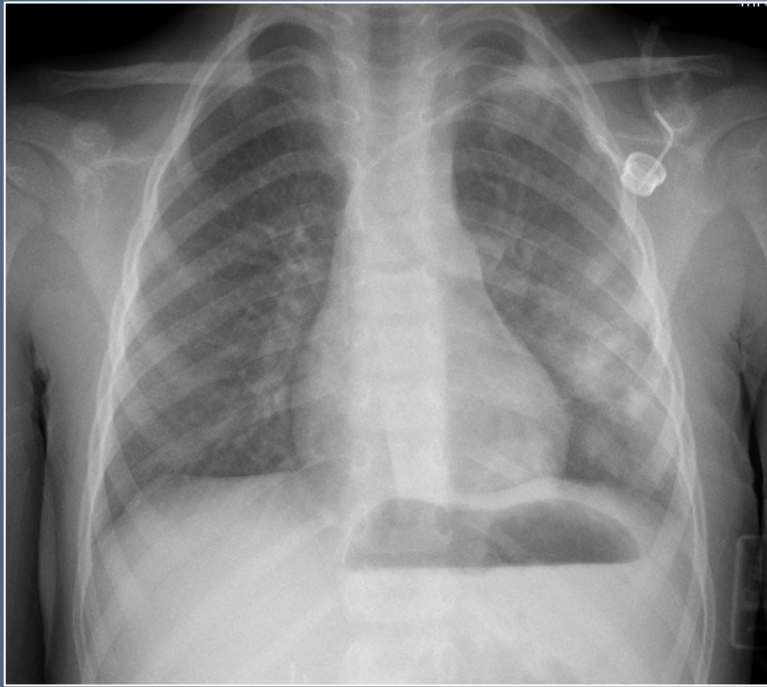


M 4 20101505  
DoB: Aug 03  
Ex: Jan 19

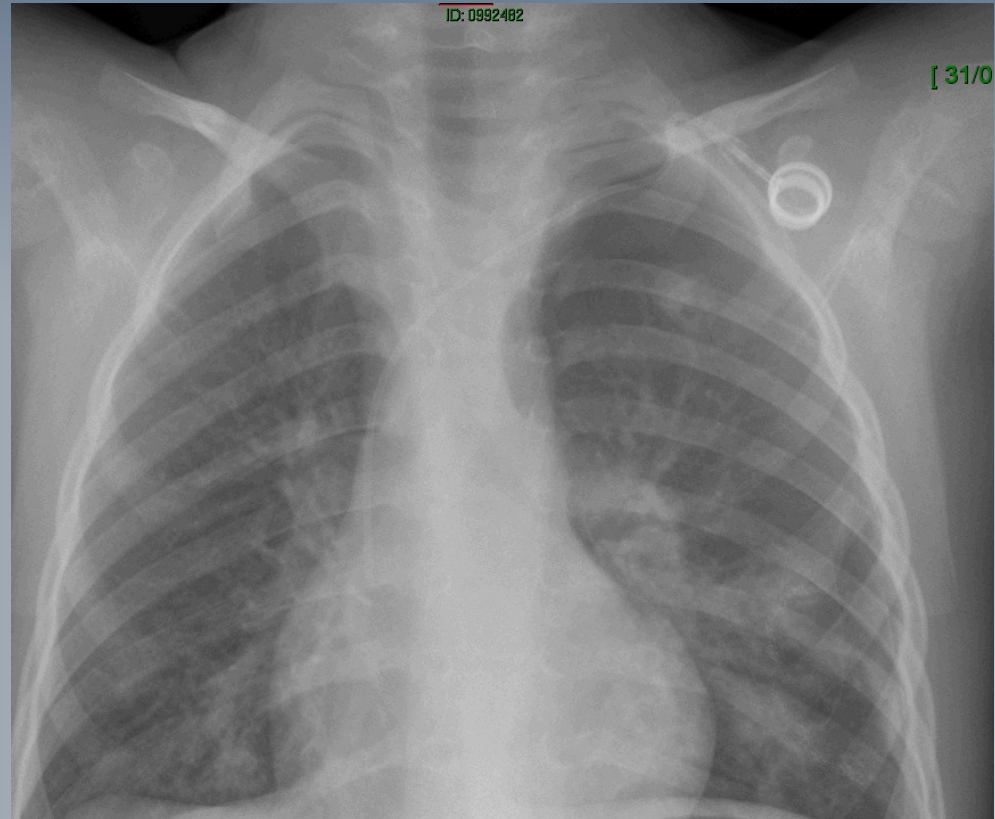


rot

First session: 8 mets treated in the left lung (2h30)



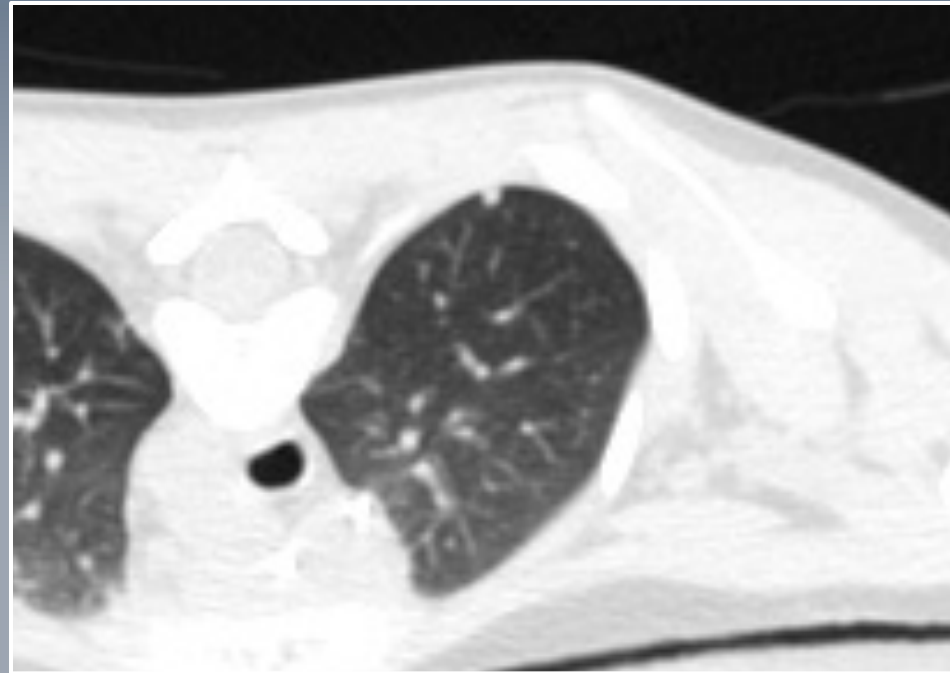D1



Delayed pneumothorax D12: asymptomatic/ no treatment

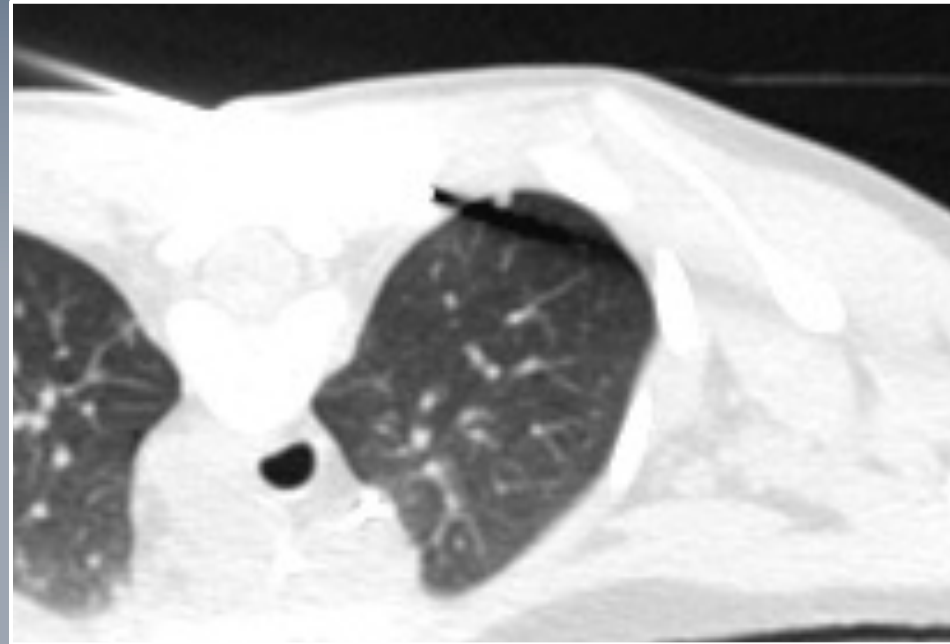


Second session (4 weeks): 4 mets treated in the right lung

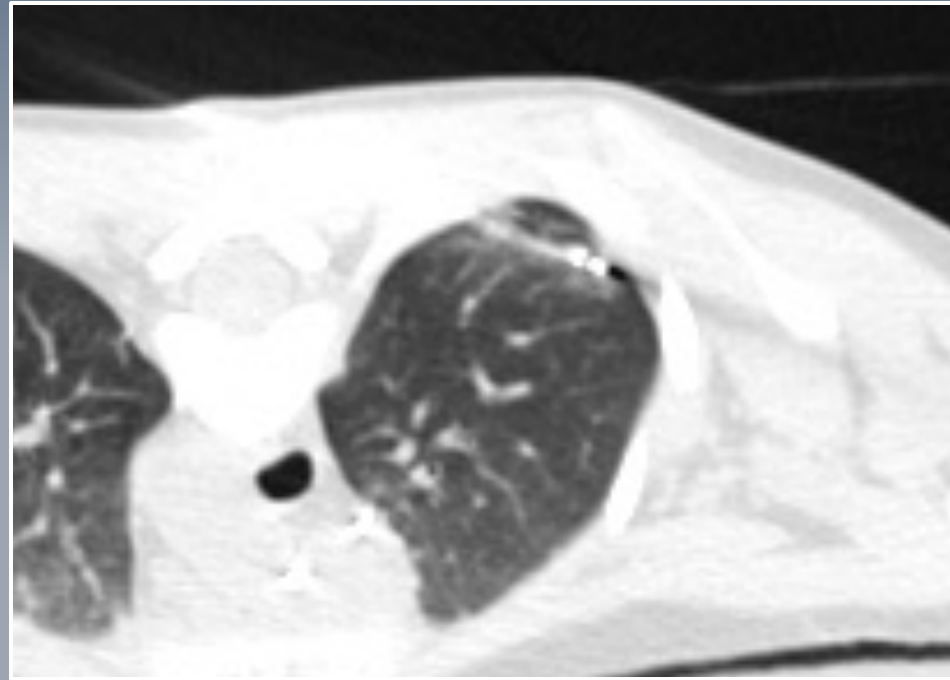




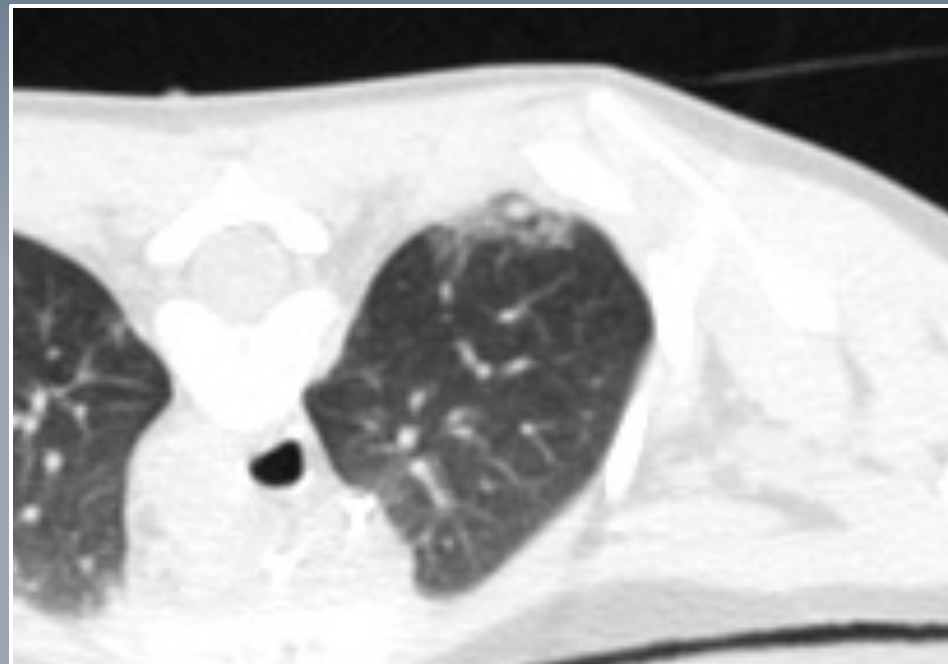Second session (4 weeks): 4 mets treated in the right lung



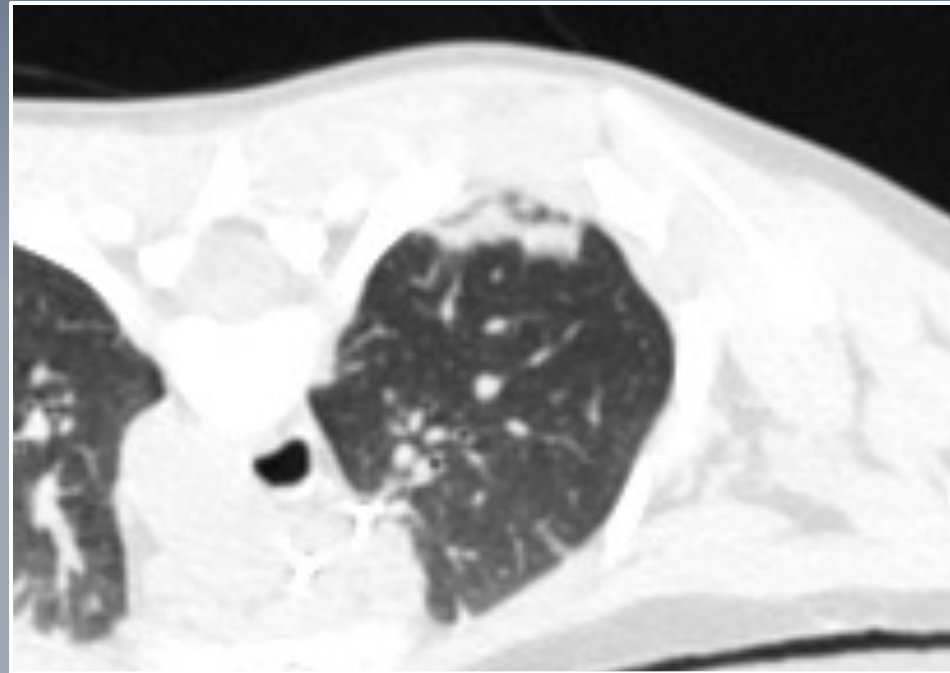
Second session (4 weeks): 4 mets treated in the right lung

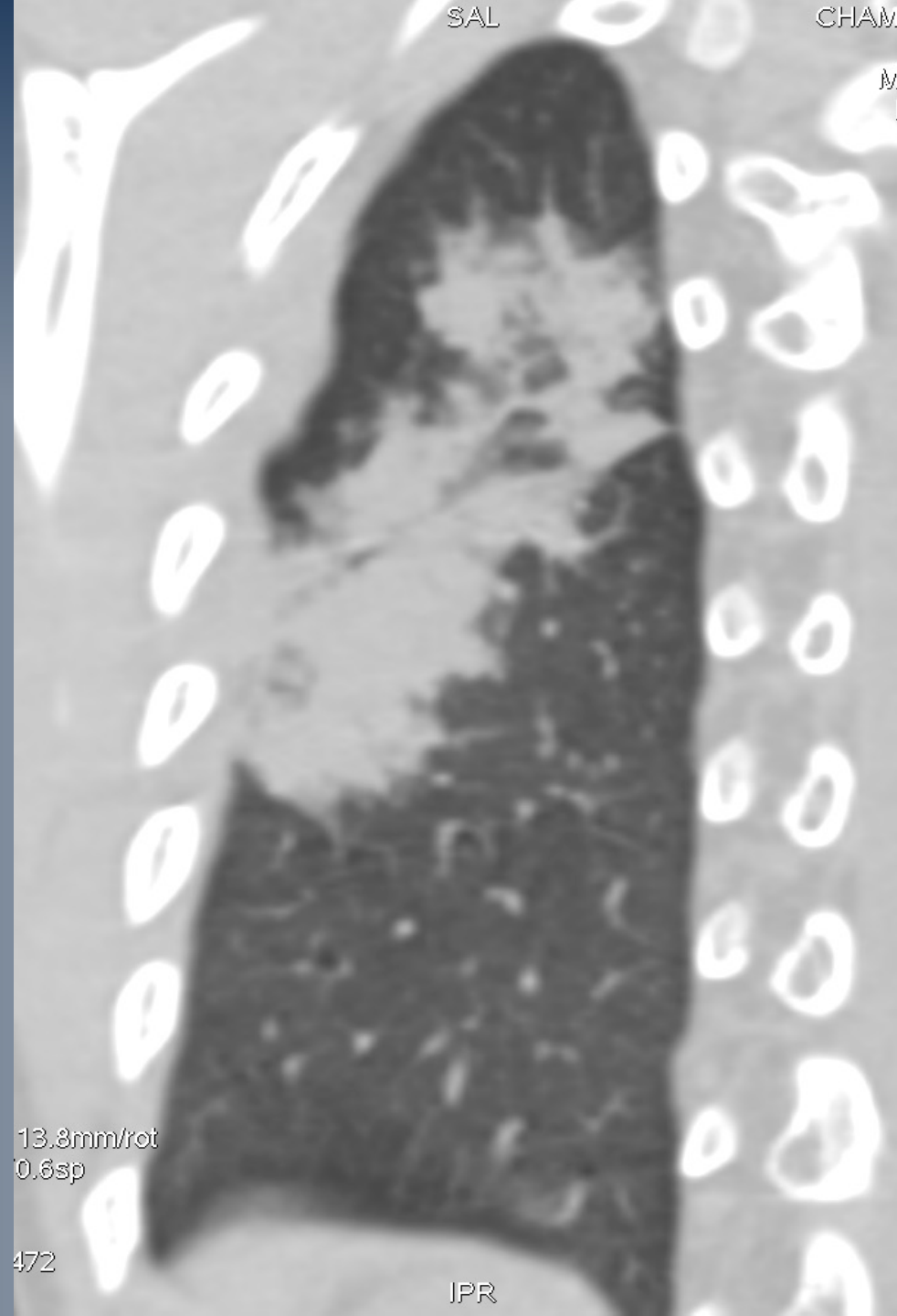


Second session (4 weeks): 4 mets treated in the right lung

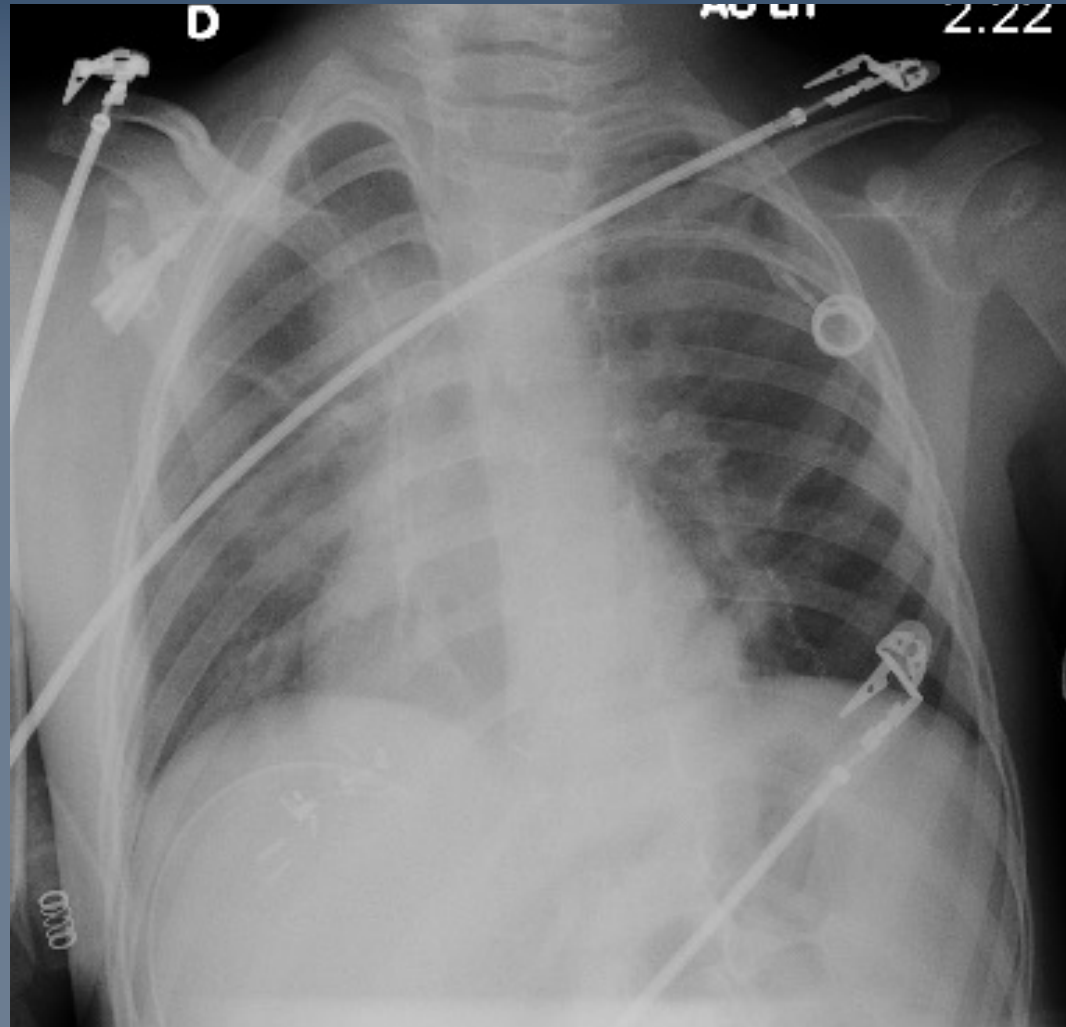


Second session (4 weeks): 4 mets treated in the right lung



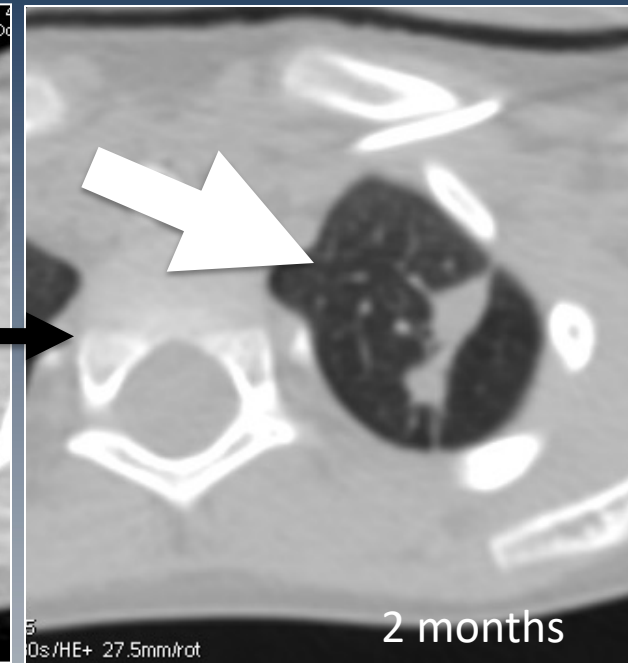
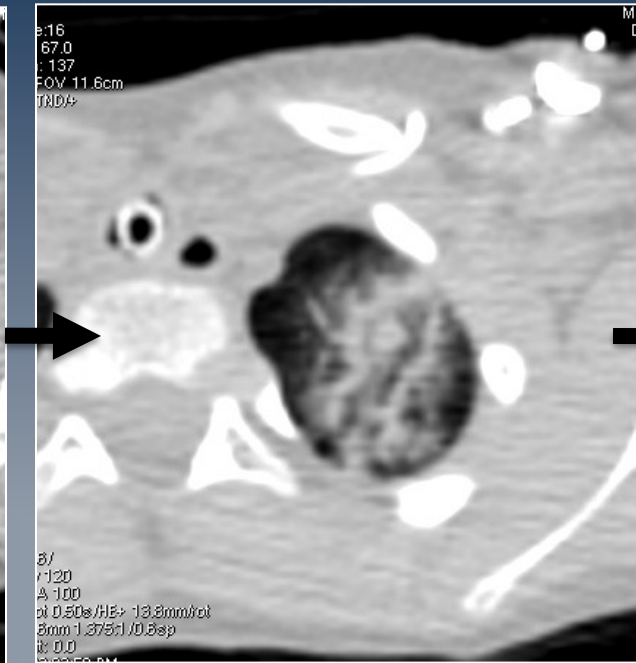
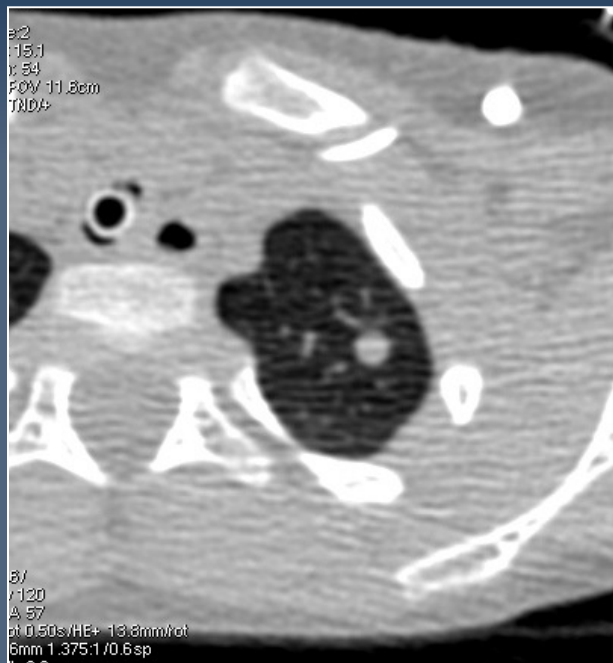


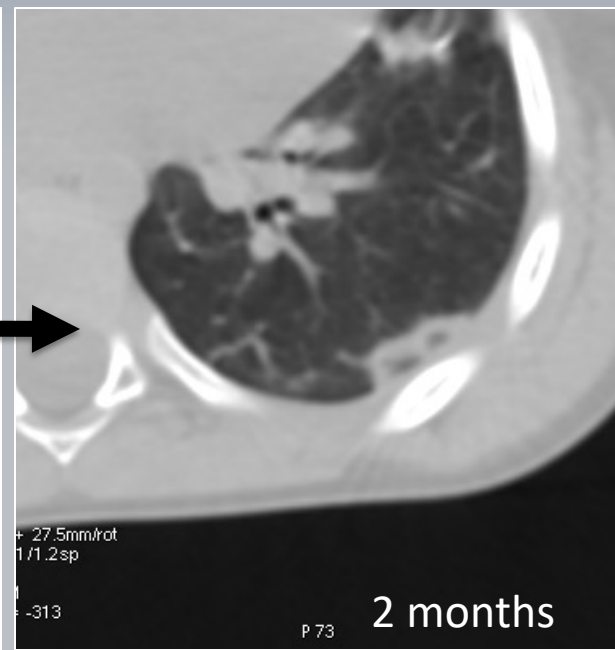
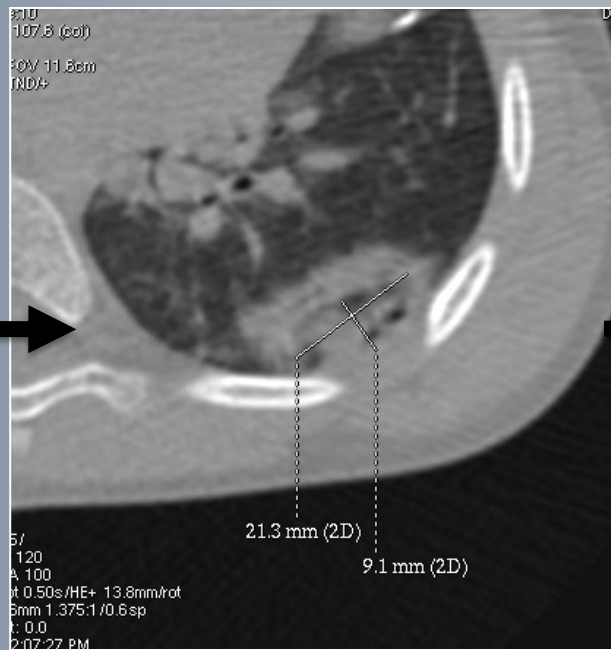
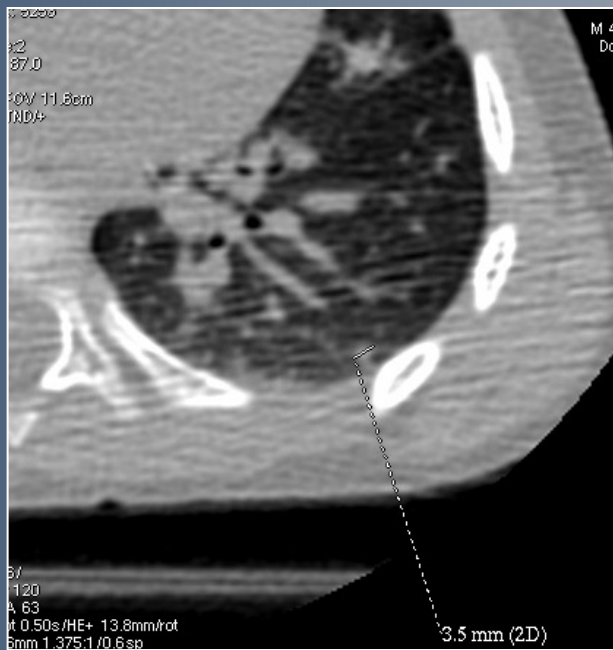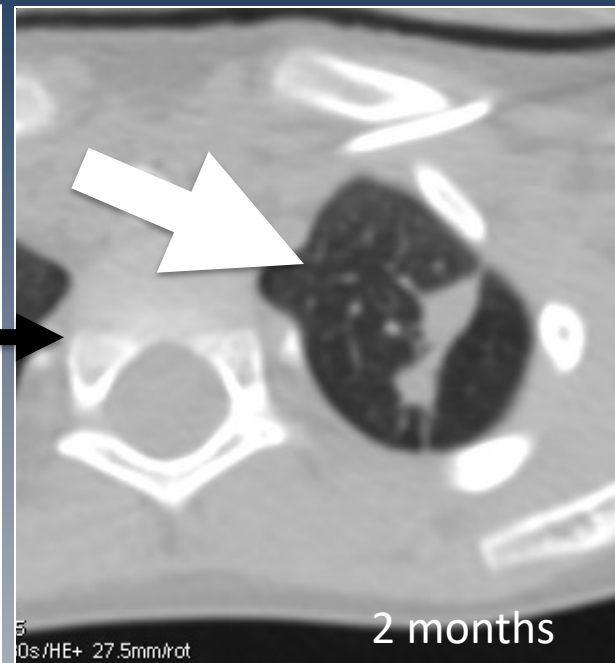
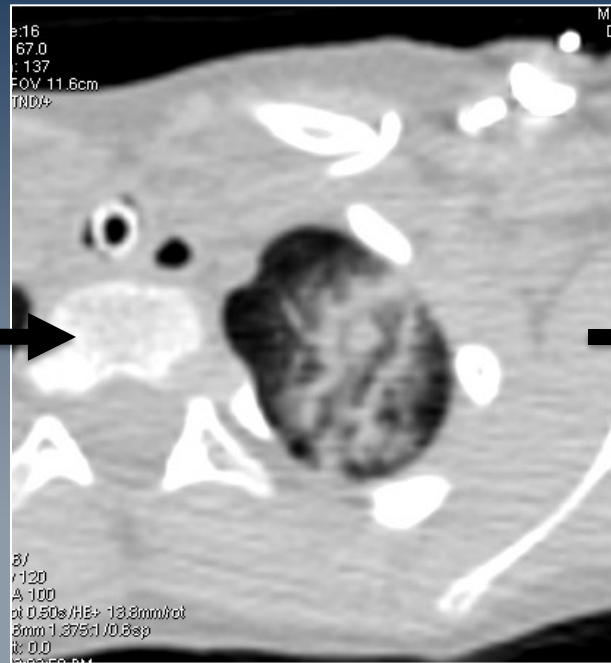
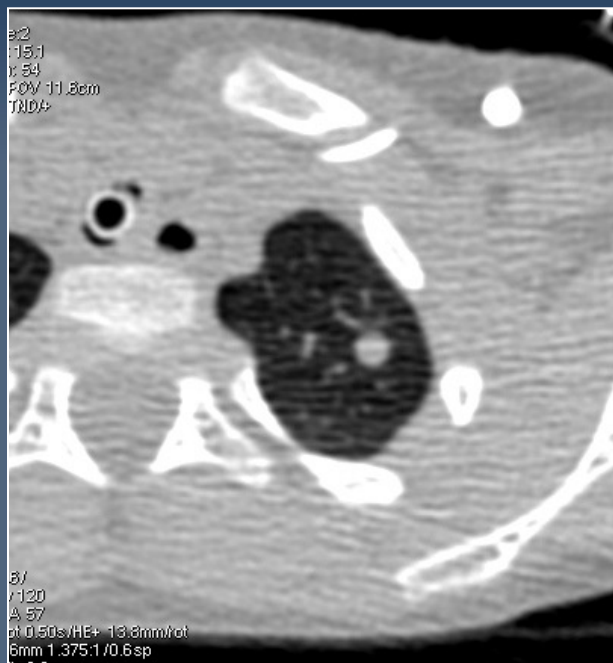




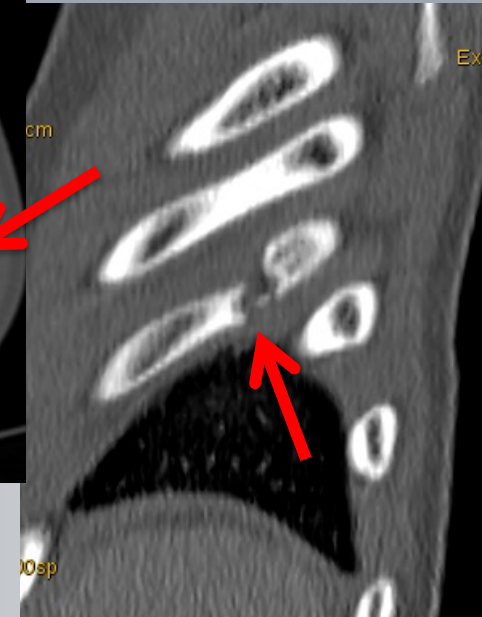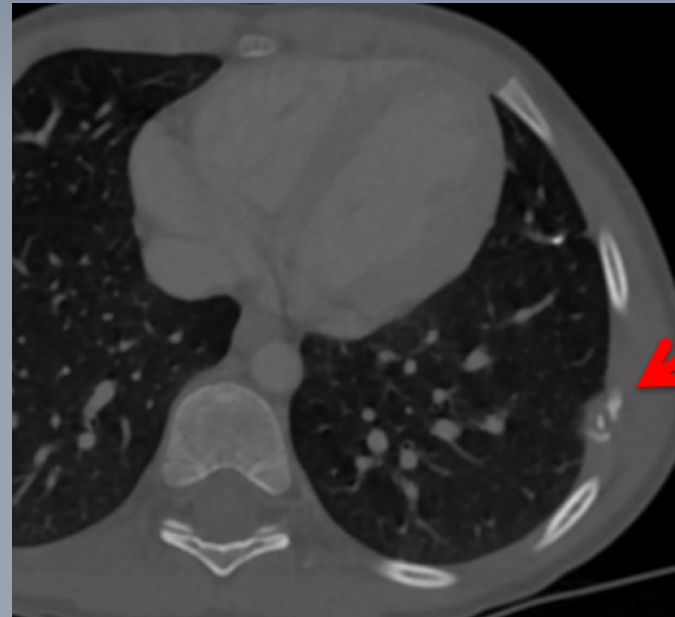
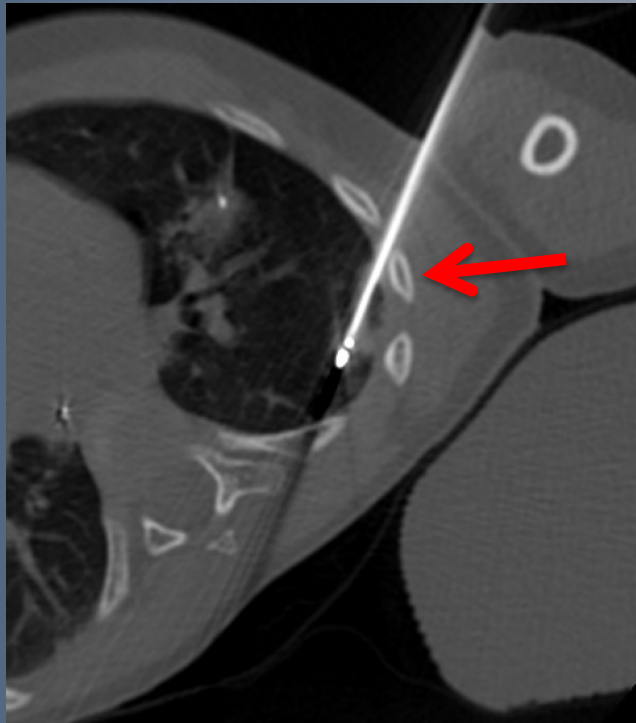
Day 2: discharged

Day 7: R0 hepatic resection





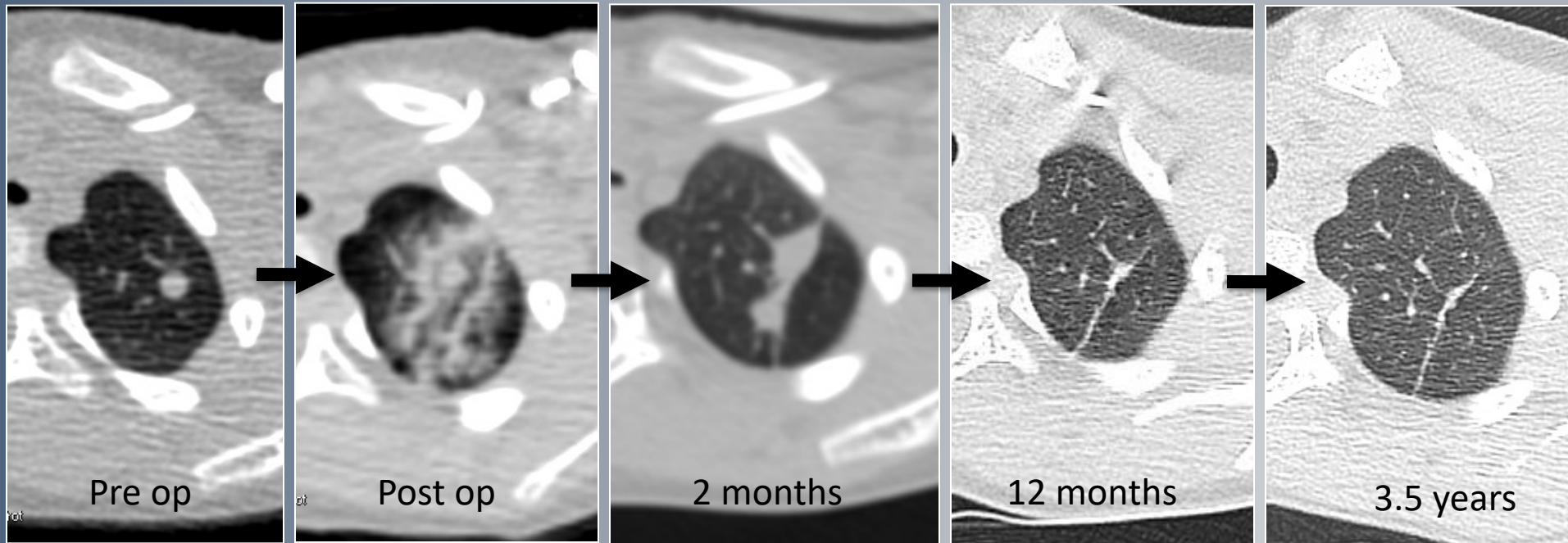
- Complications:
  - 1 delayed non-pathological fracture of the rib (at 11 months)
  - Asymptomatic
  - biopsied



- No other complication

1 new lung mets  
retreated after 8 months

1 new lung mets  
retreated after 3.5 years





## RFA benefit

- has avoided bilateral thoracotomies
- has allowed surgical liver resection

## RFA benefit

- has avoided bilateral thoracotomies
- has allowed surgical liver resection
- but...
  - no biopsy (too small)
  - imaging follow-up more difficult
  - no data in the literature

Patient is 10 years old and disease free,

we have not seen him since 11 months

Thank you