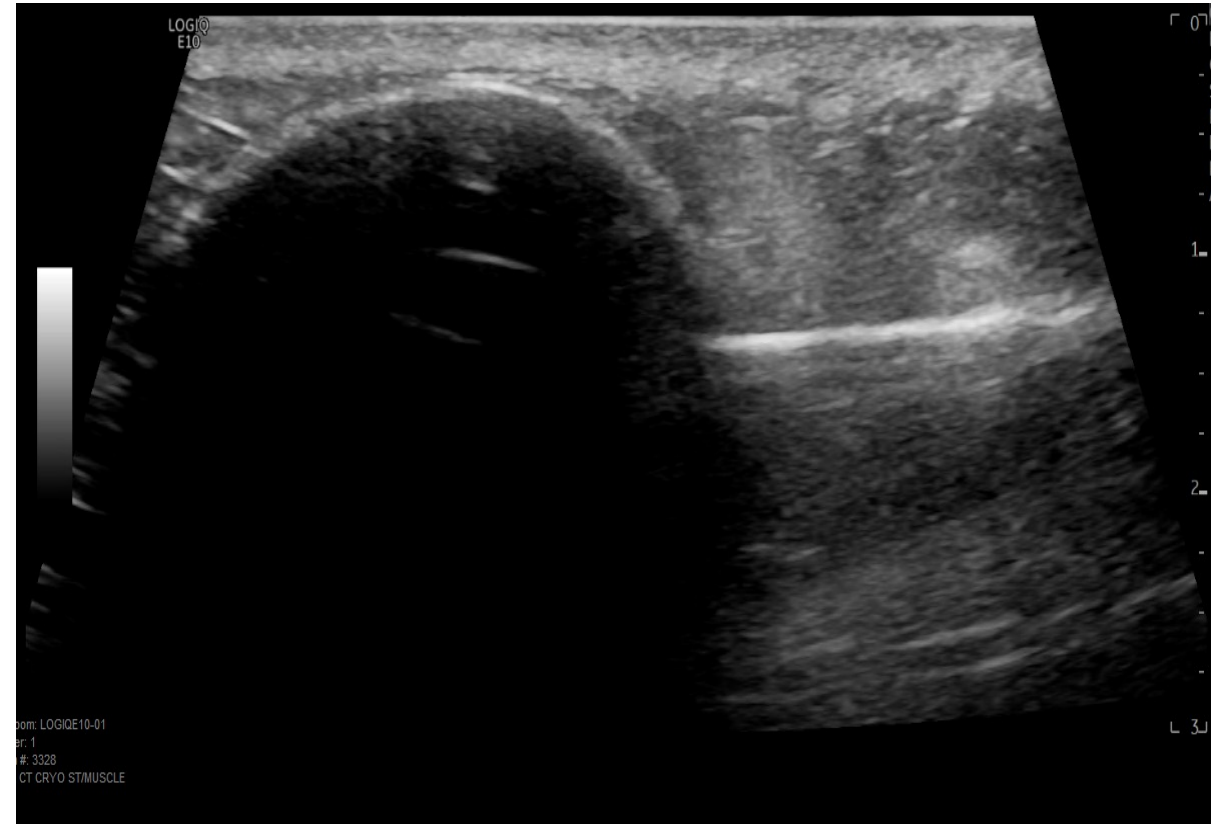
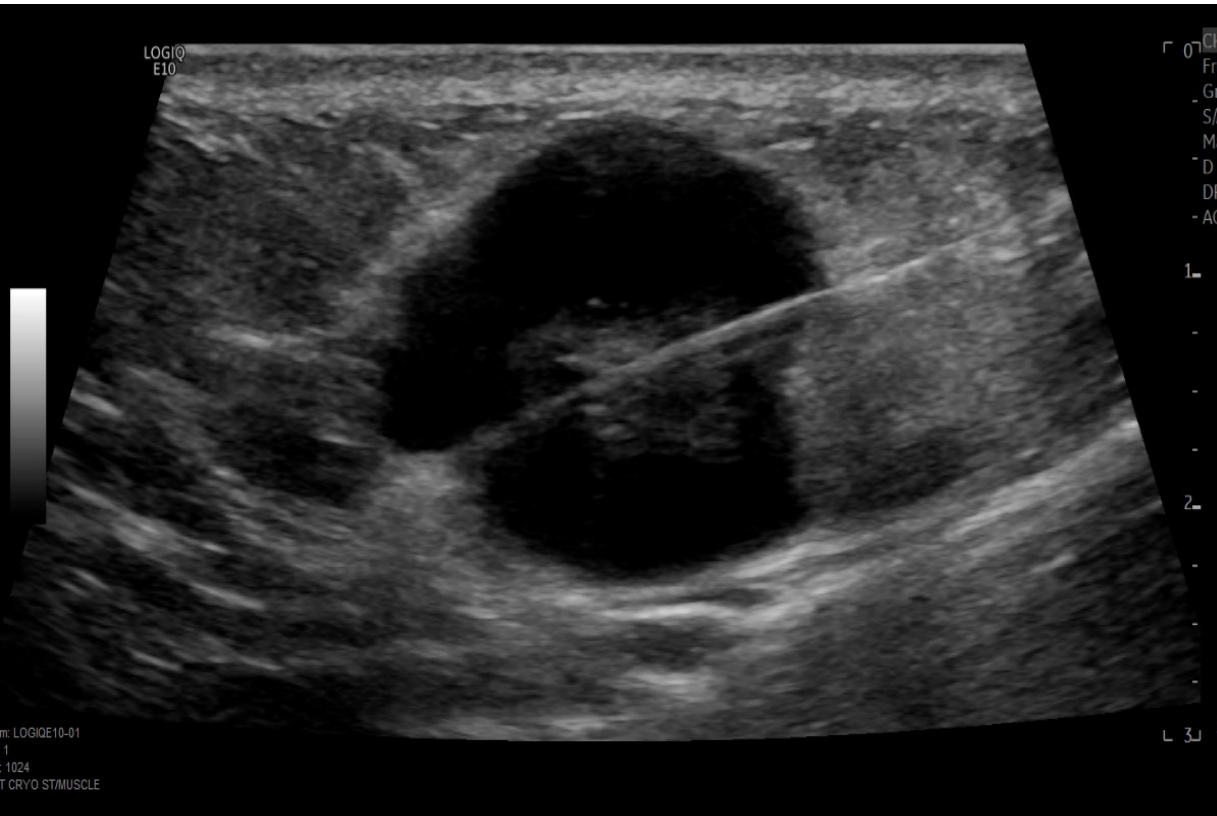


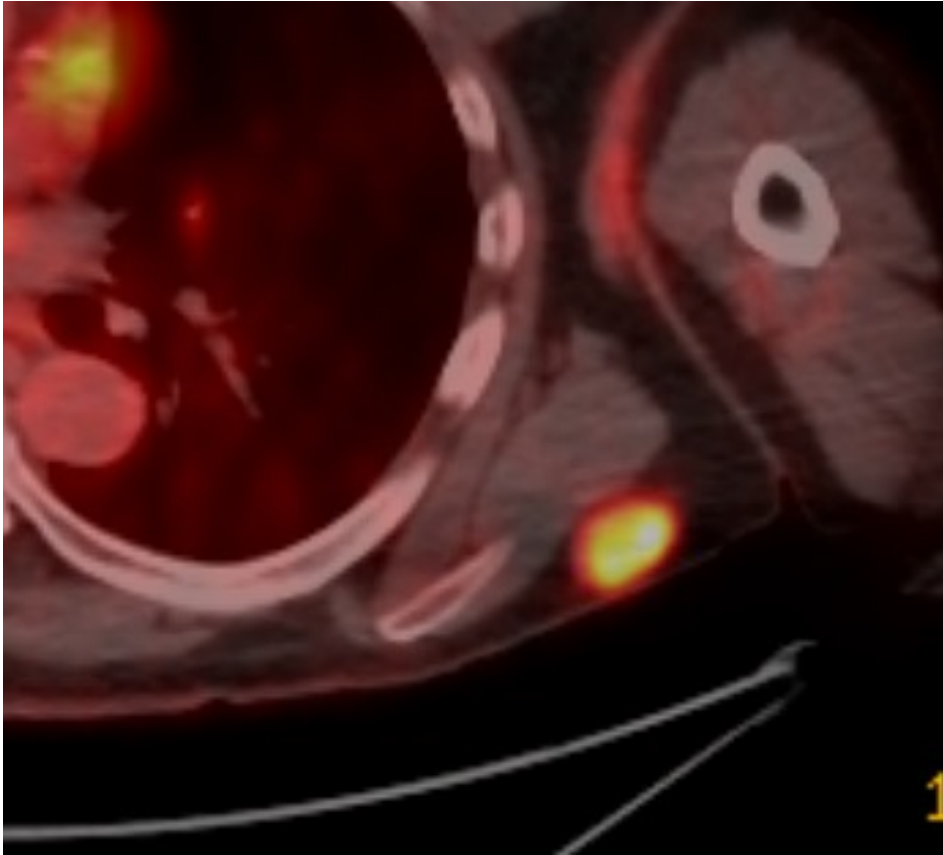
Small subcutaneous nodule

Steven Yevich, MD MPH
MD Anderson Cancer Center
Houston, Texas

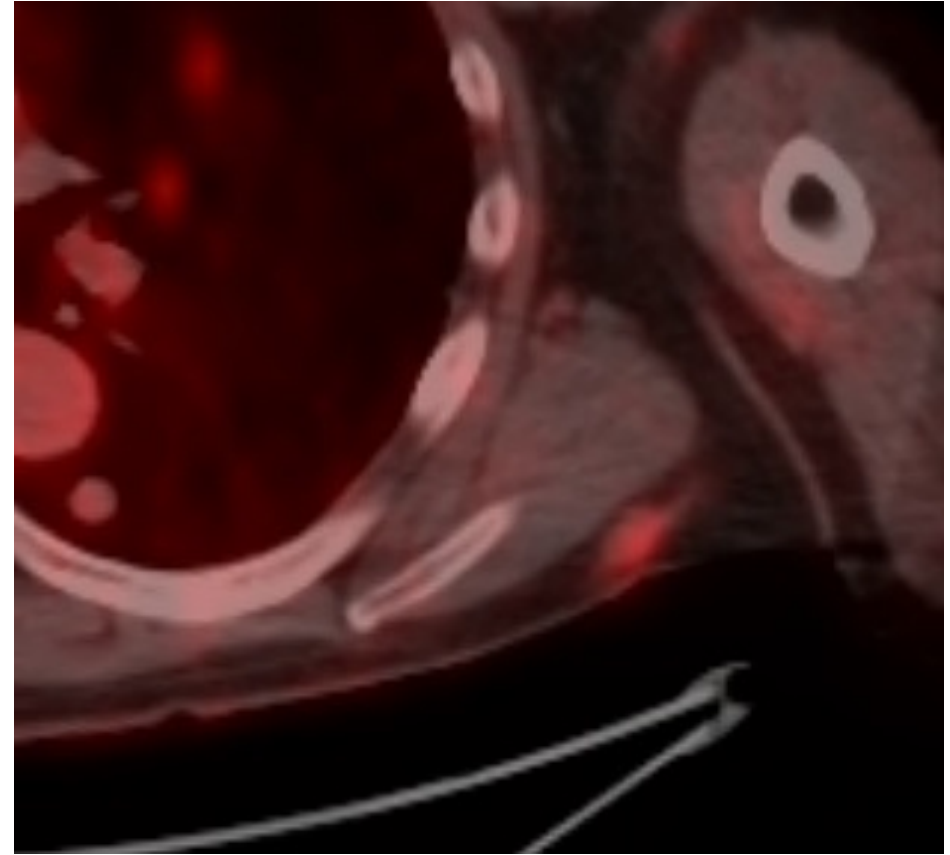
Procedure Monitoring with Ultrasound



Follow up



Pre treatment



8 month post treatment