



George Behrens, MD
Interventional Radiologist



Vascular and
Interventional Radiology

Extreme 10 cases

| Case

66 year-old female with hypertension who found to have a 12cm enhancing mass in segment IV-V of the liver during US evaluation

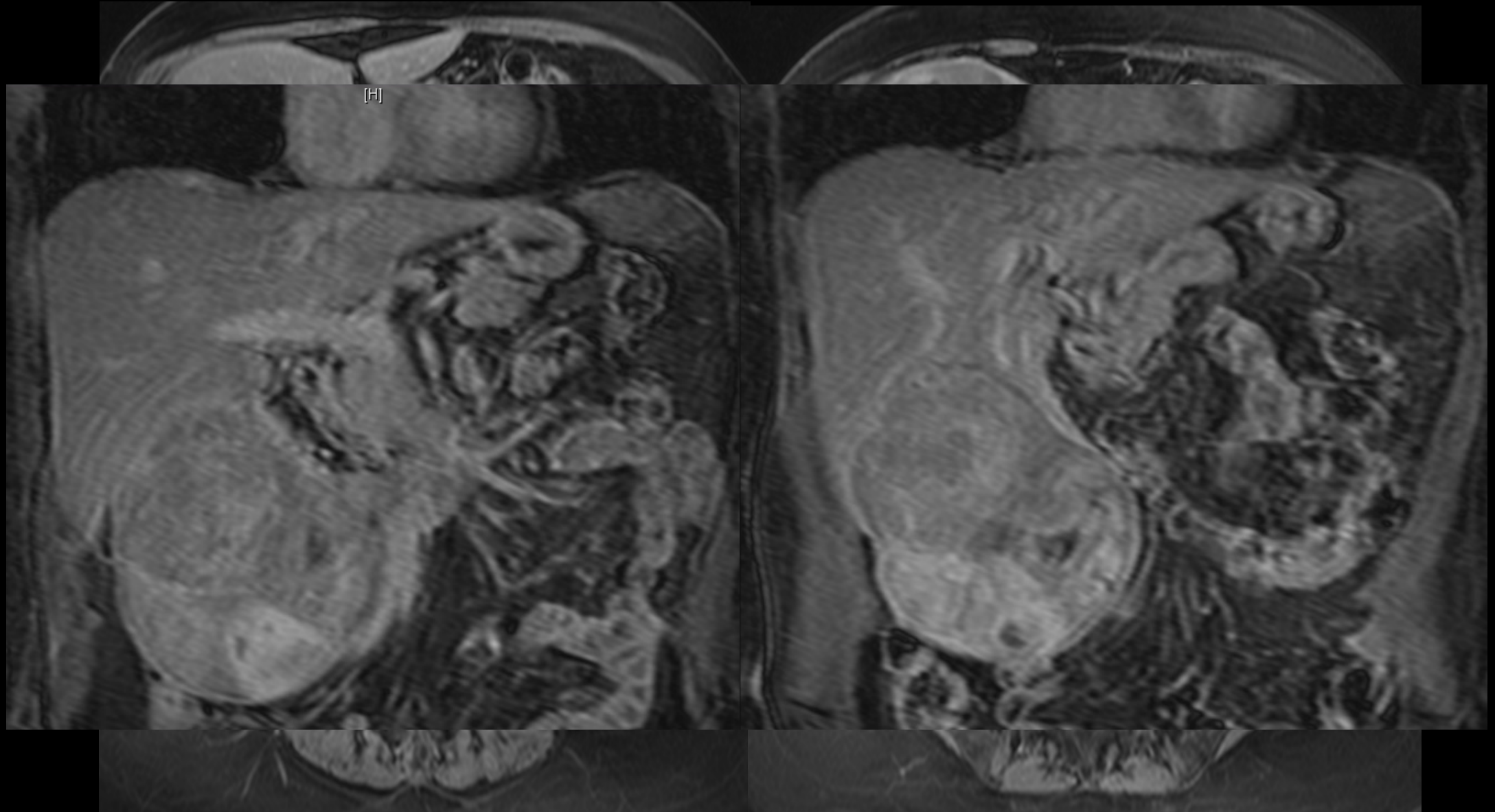
Patient was taken to liver resection

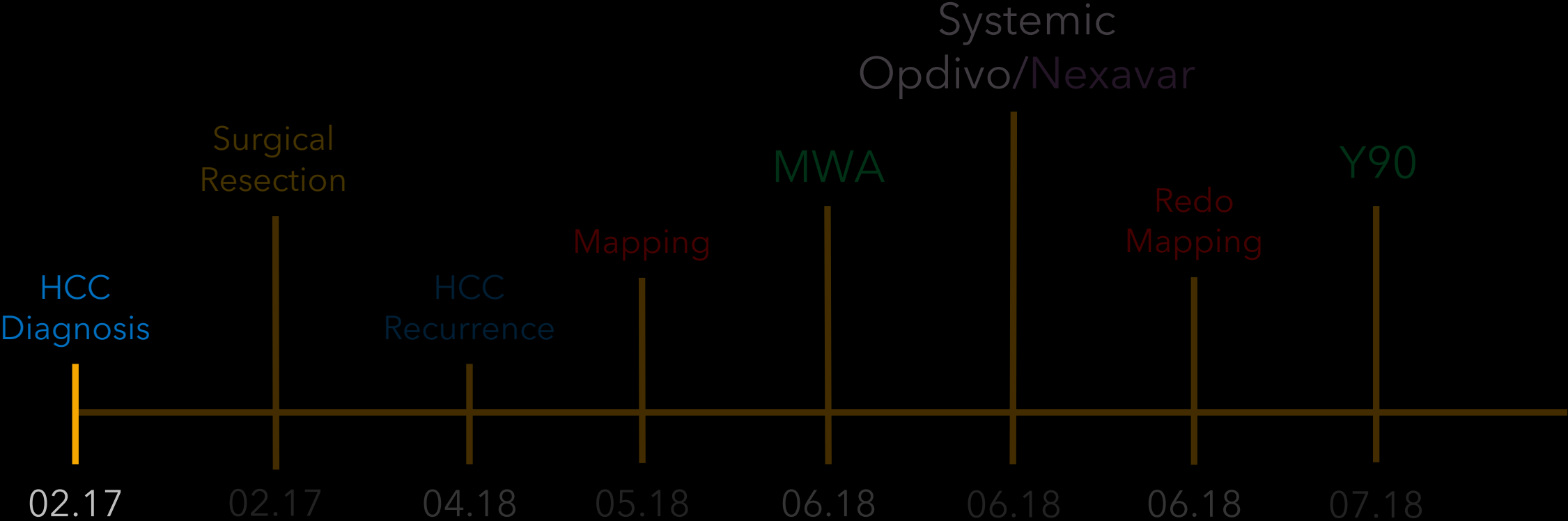
- Complete Resection.
- Path: HCC. Negative margins

Laboratories

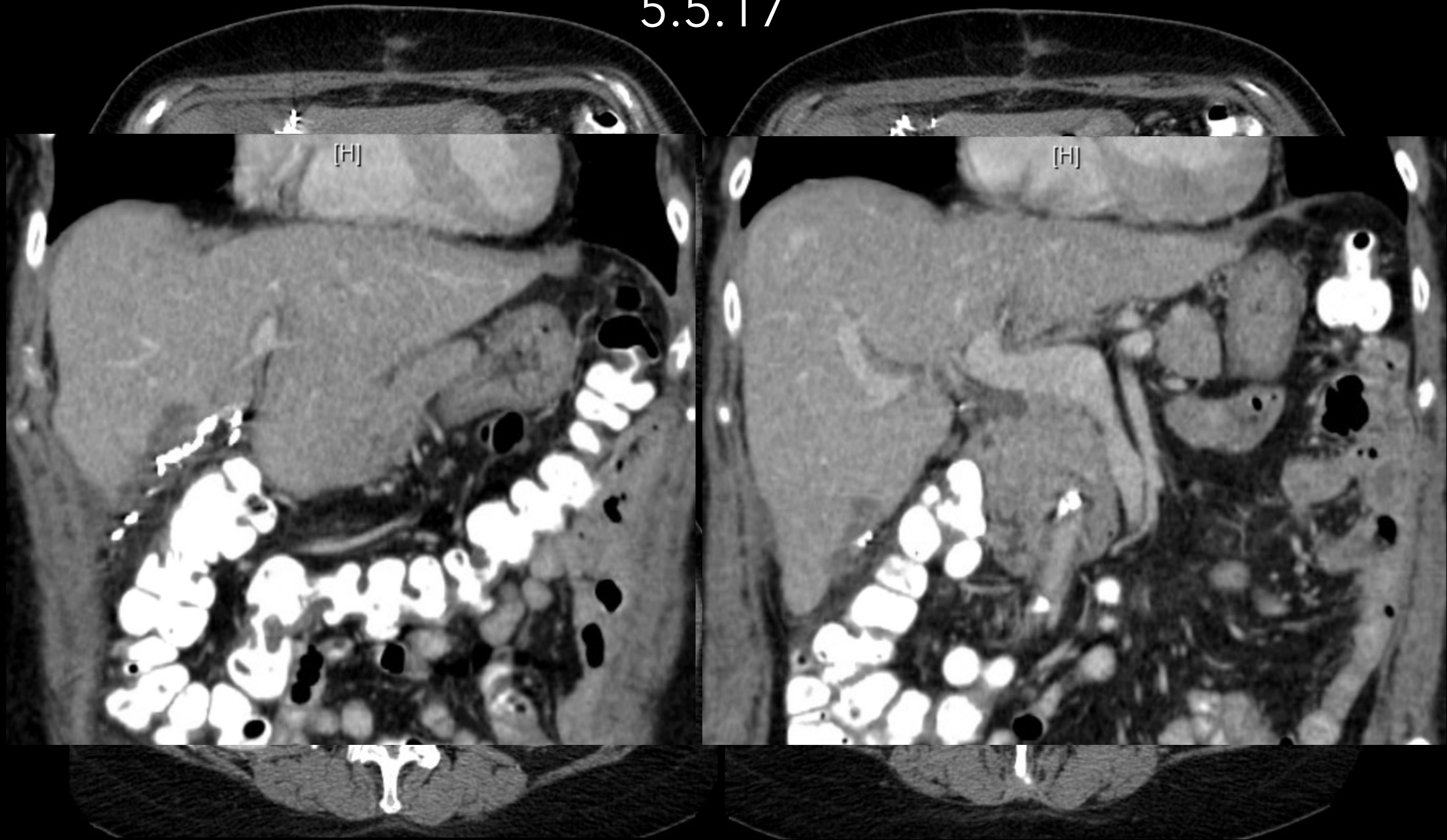
- Tbil: 0.5; Alb: 2.5; Alk Phos: 475 AFP: 10
- Child-Pugh: A
- ECOG: 0

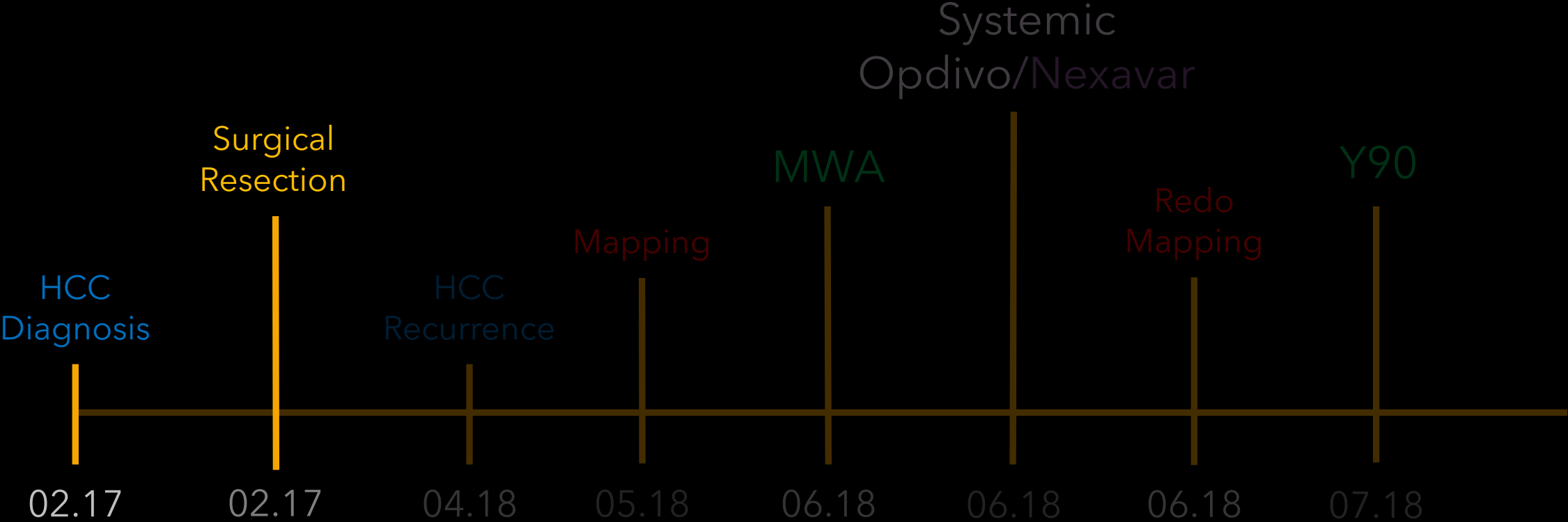
2.16.17



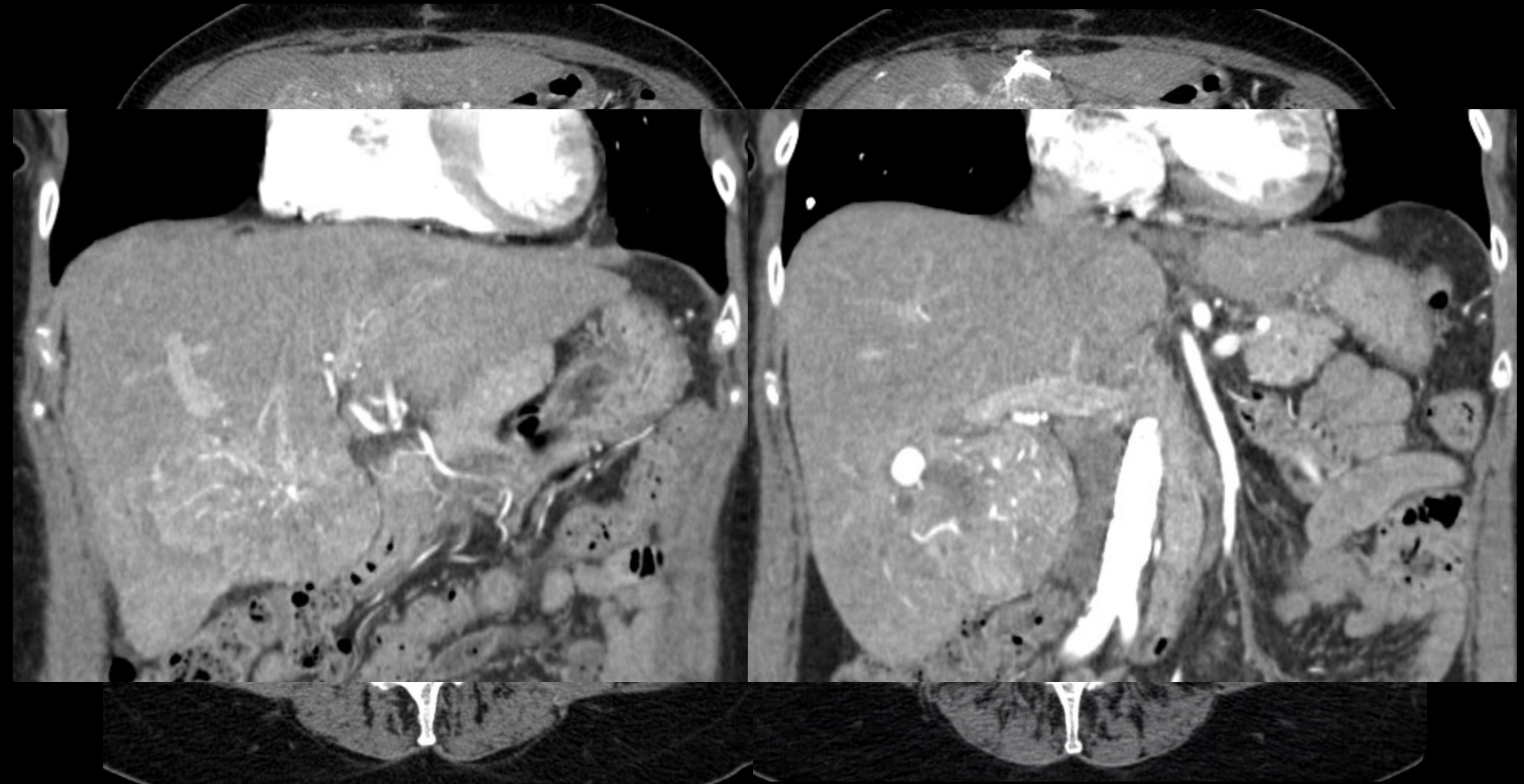


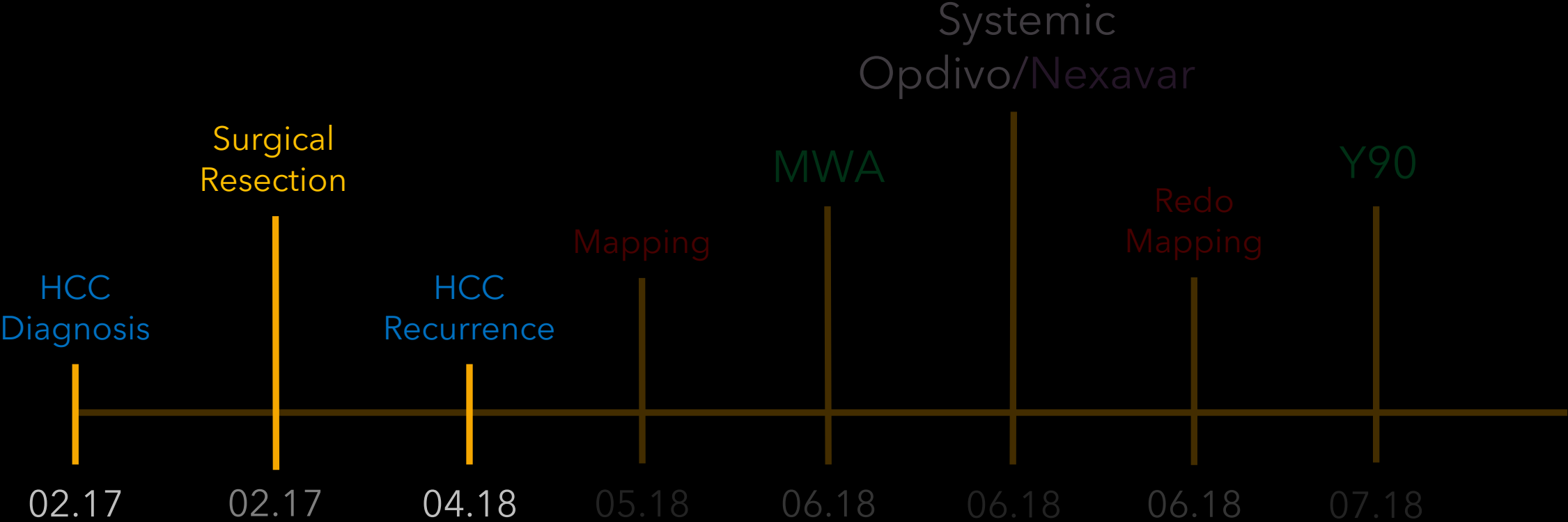
5.5.17



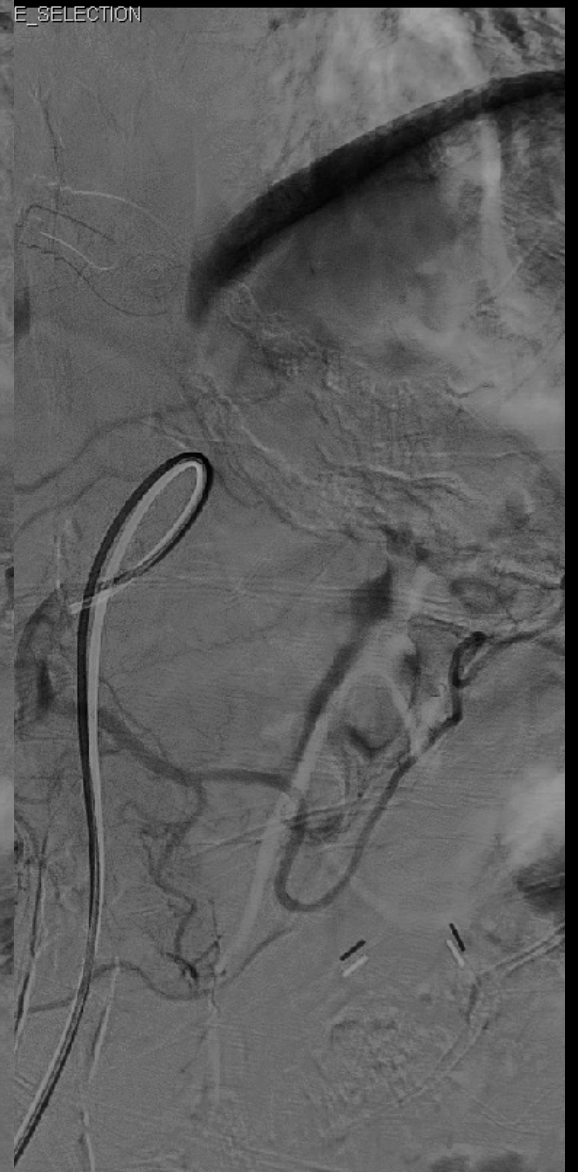
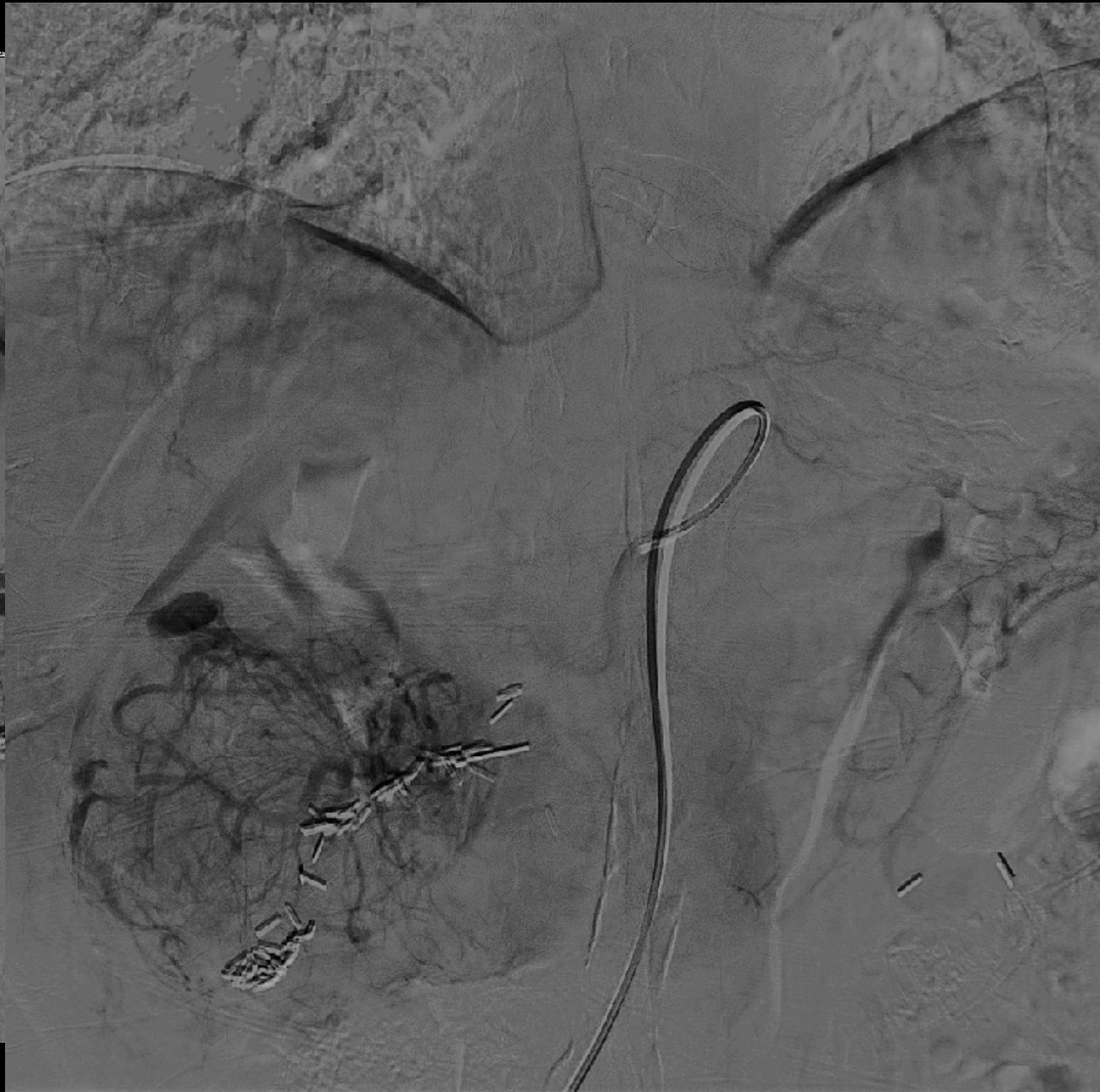
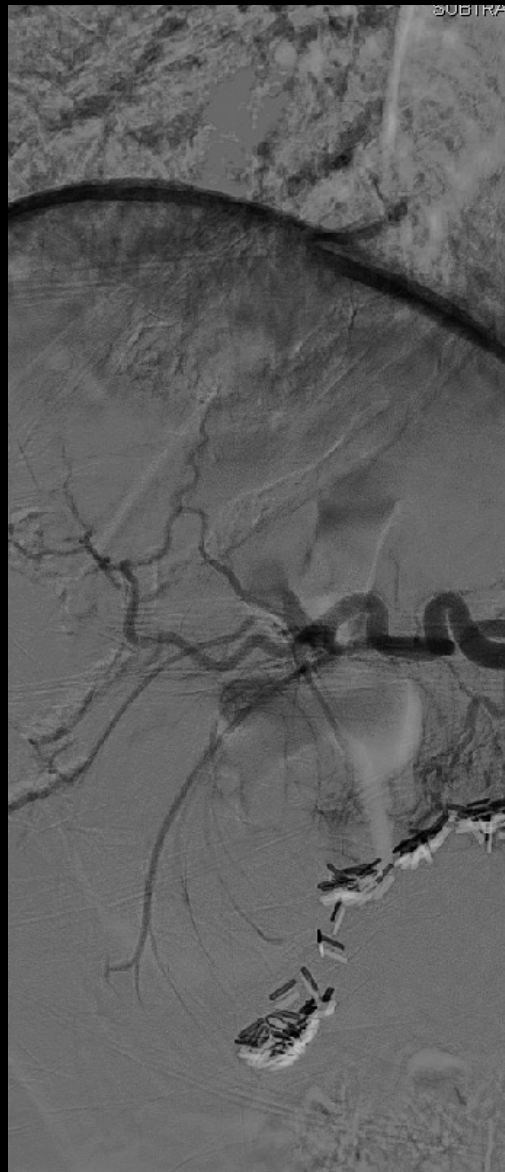4.30.18

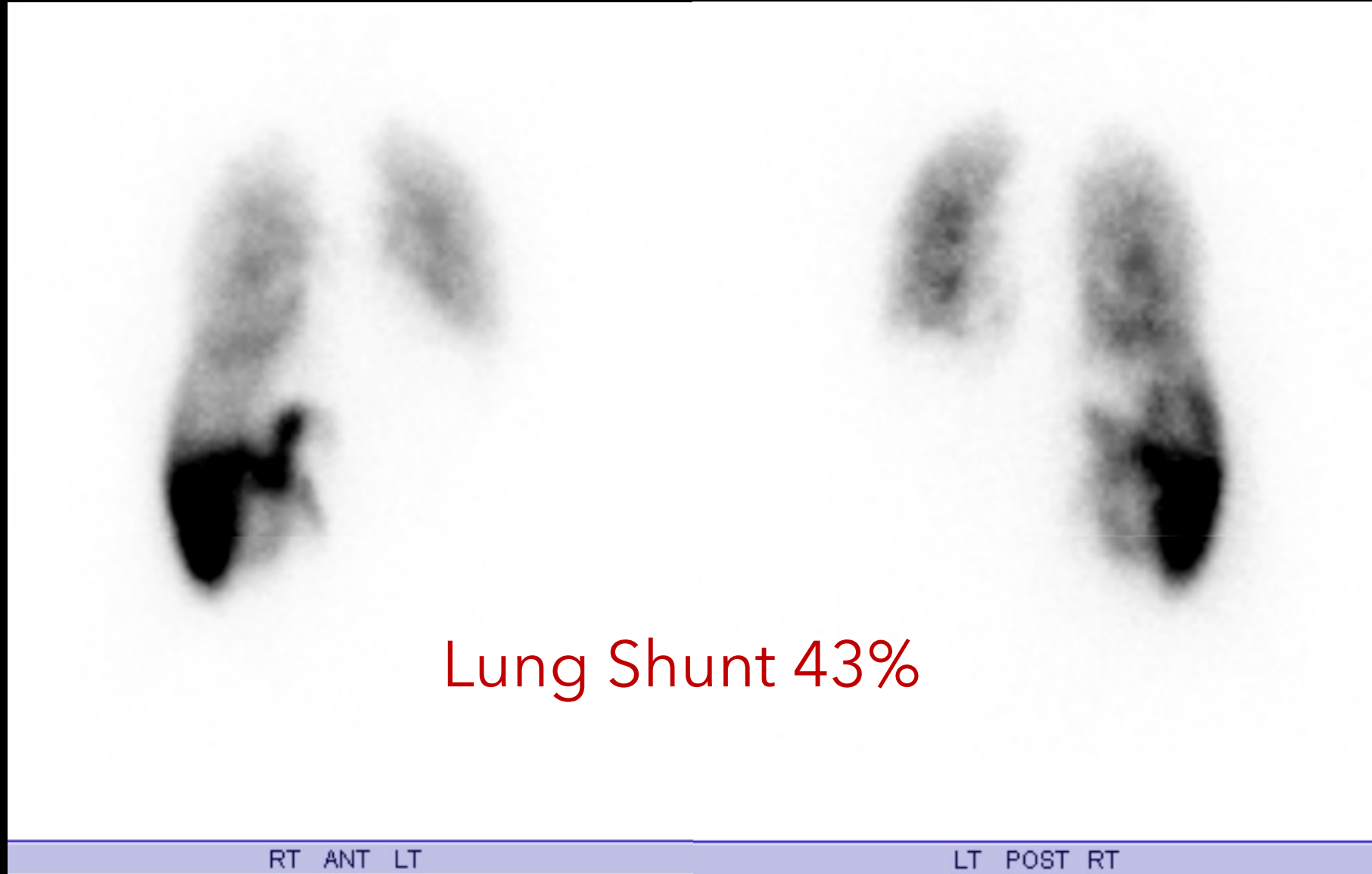


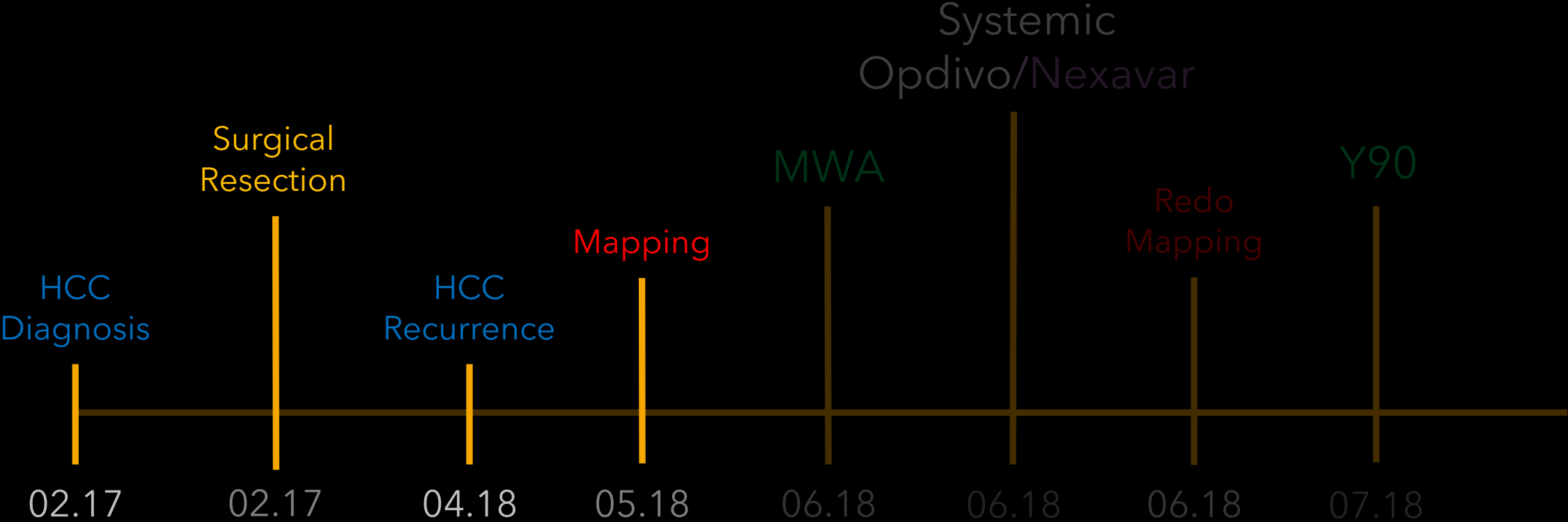


5.22.18



5.22.18

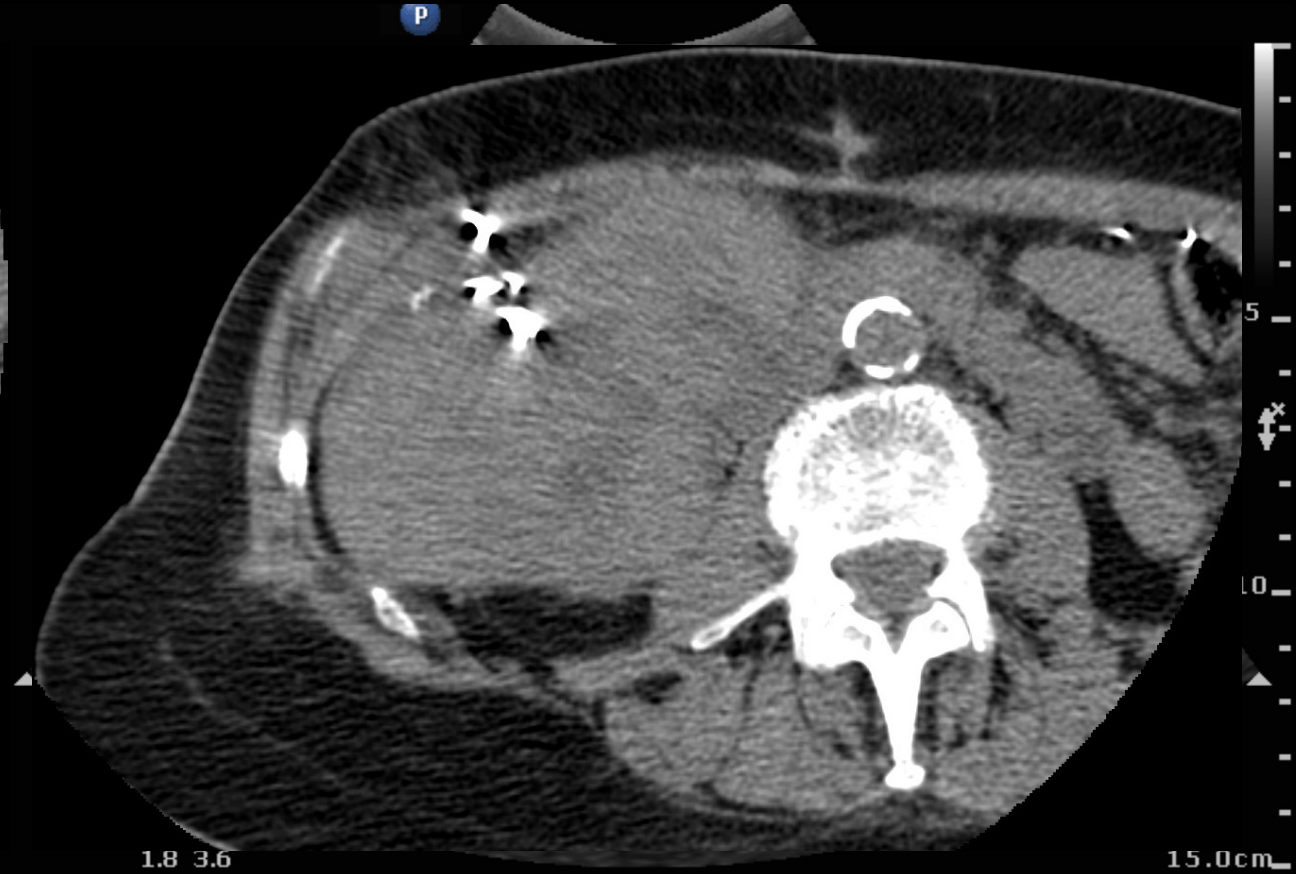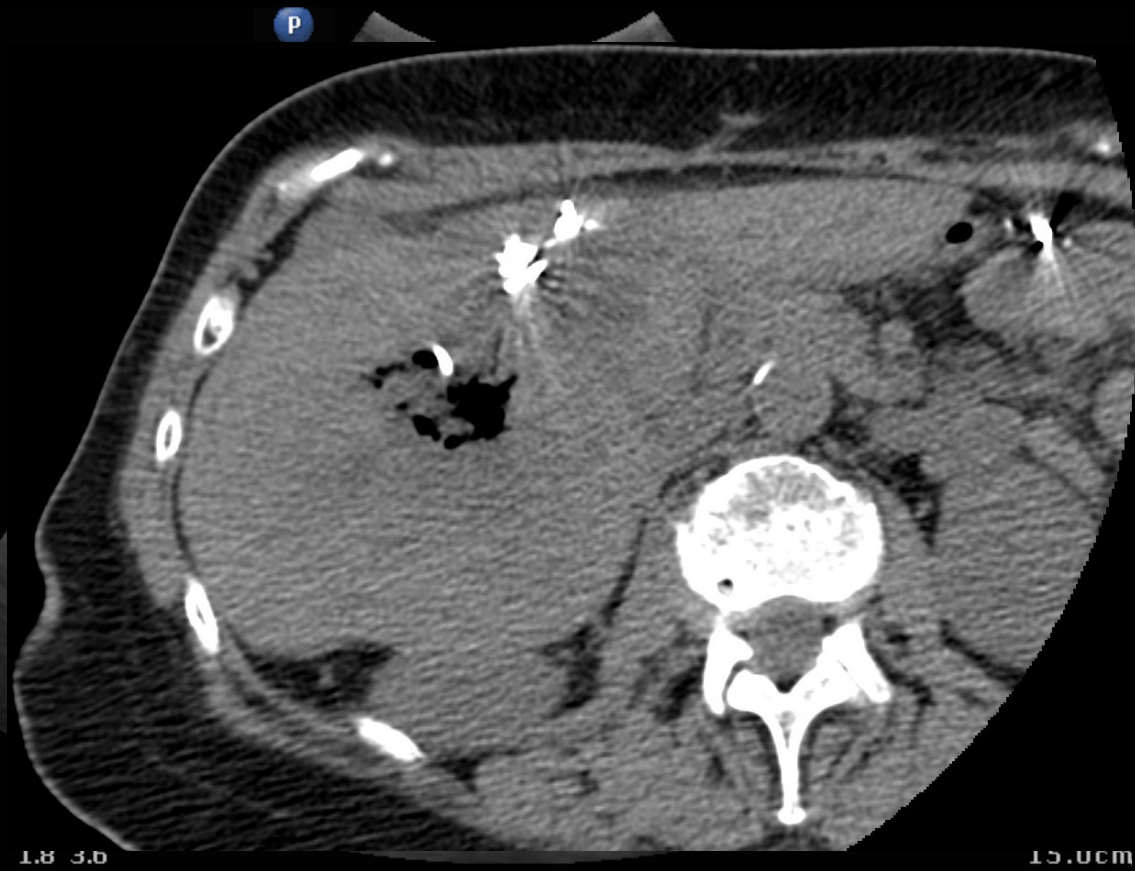


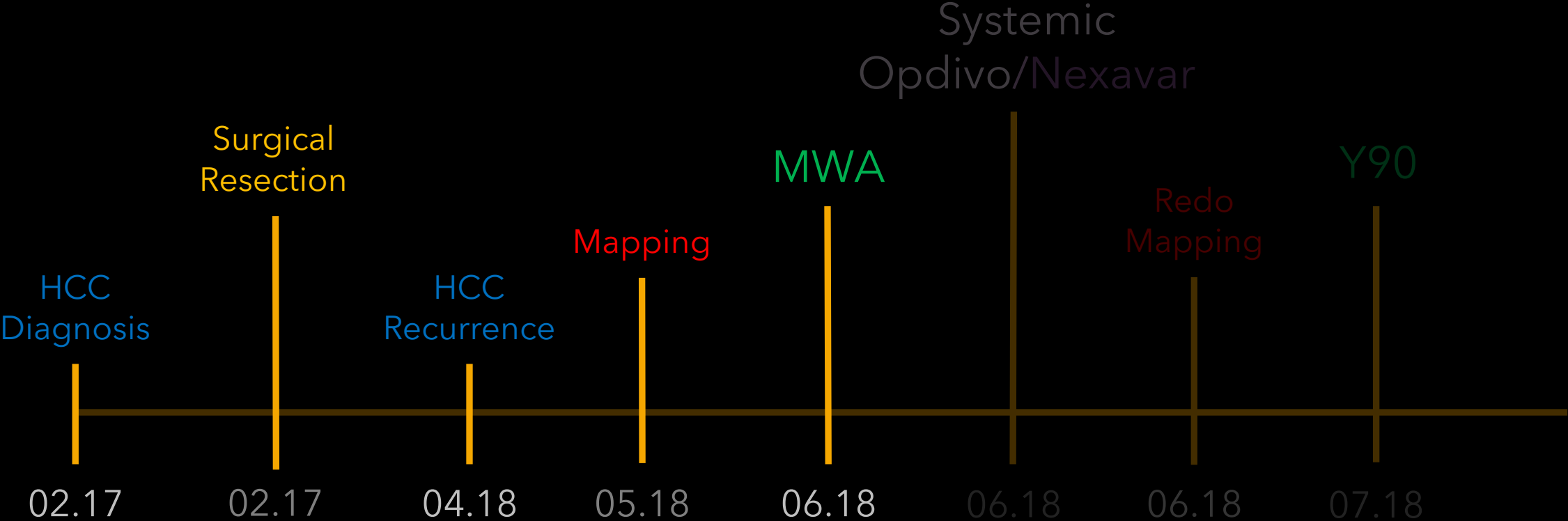


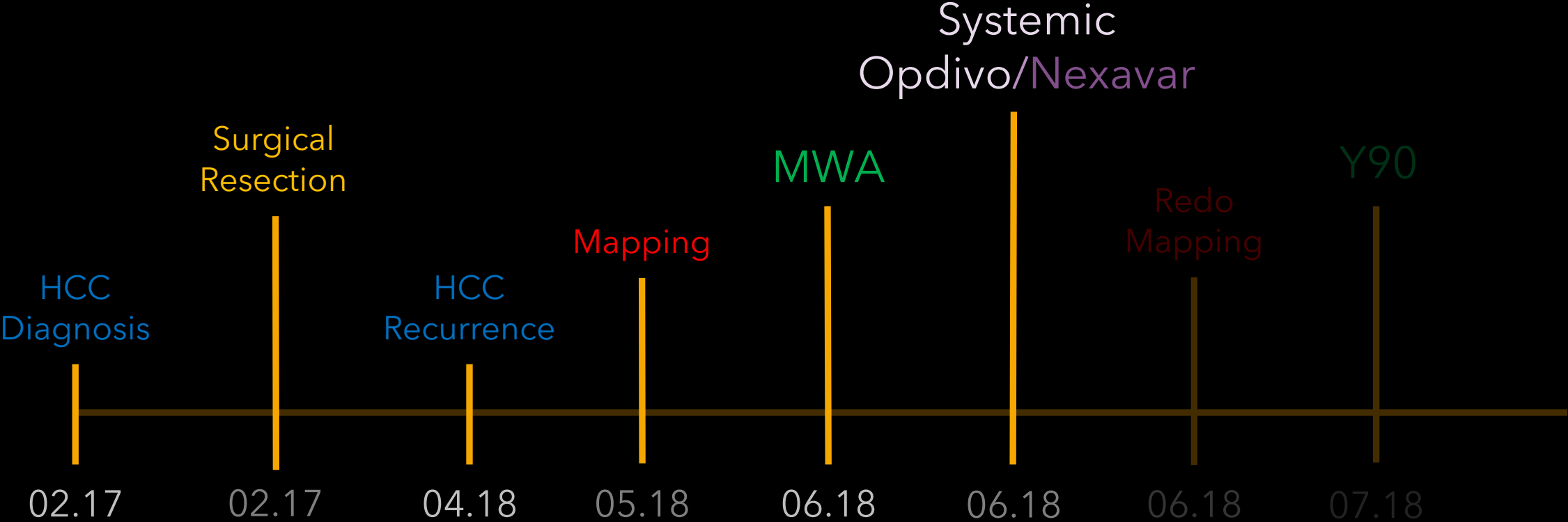
Can we improve
Lung Shunting?

How?

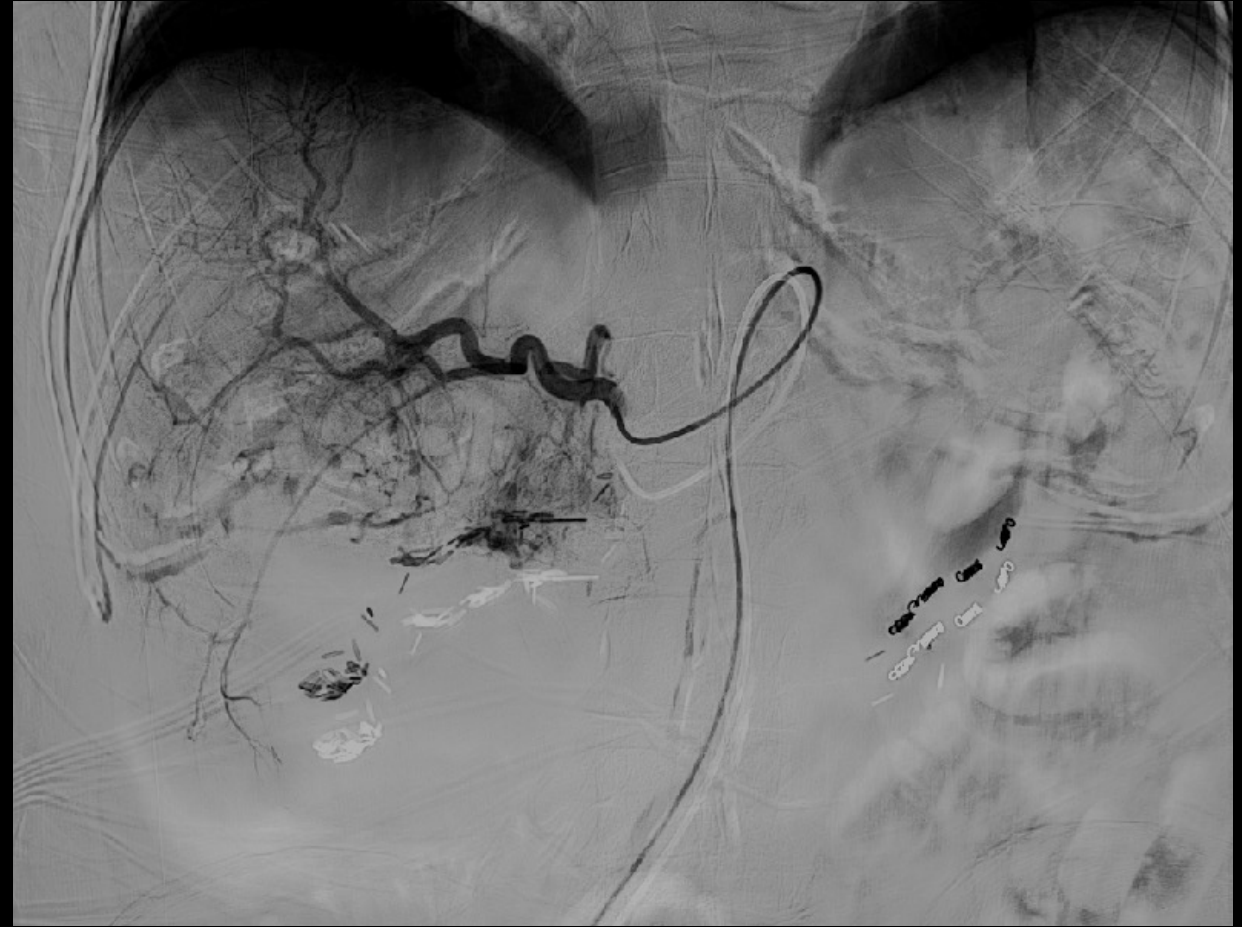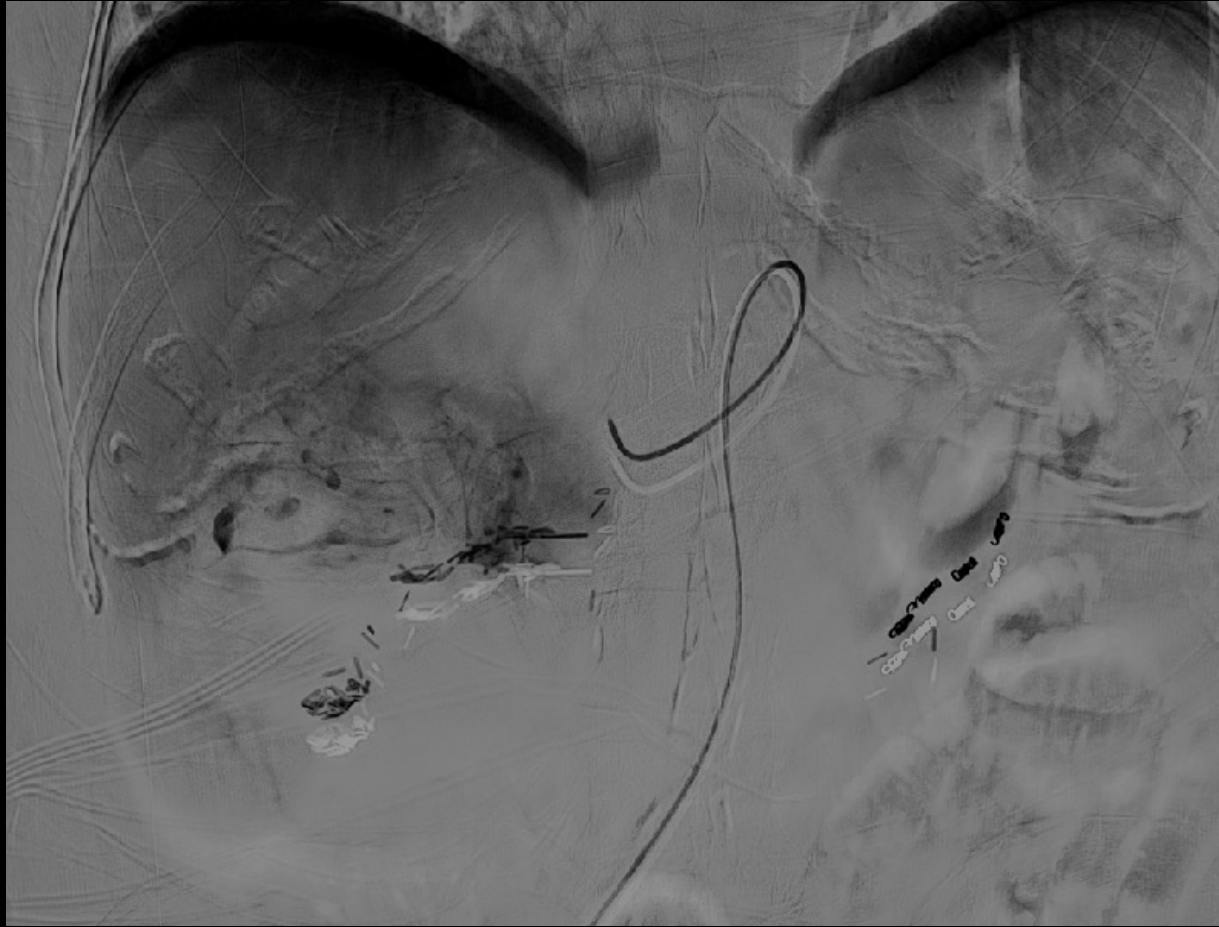6.13.18
MWA



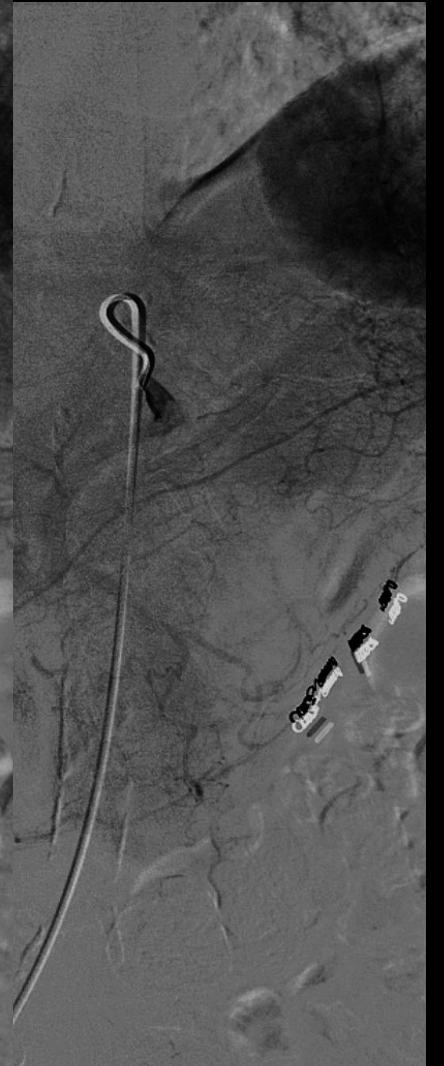
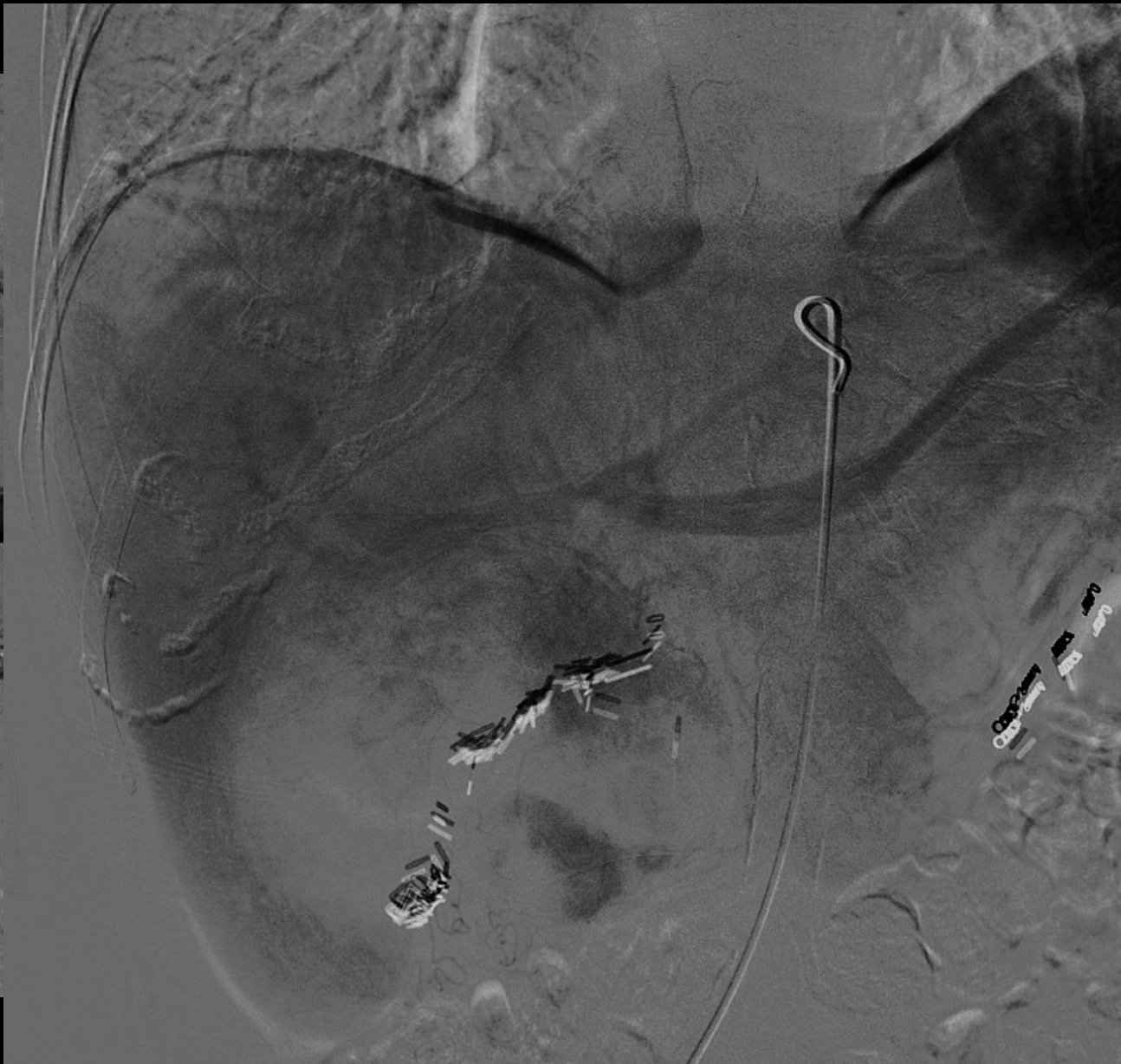
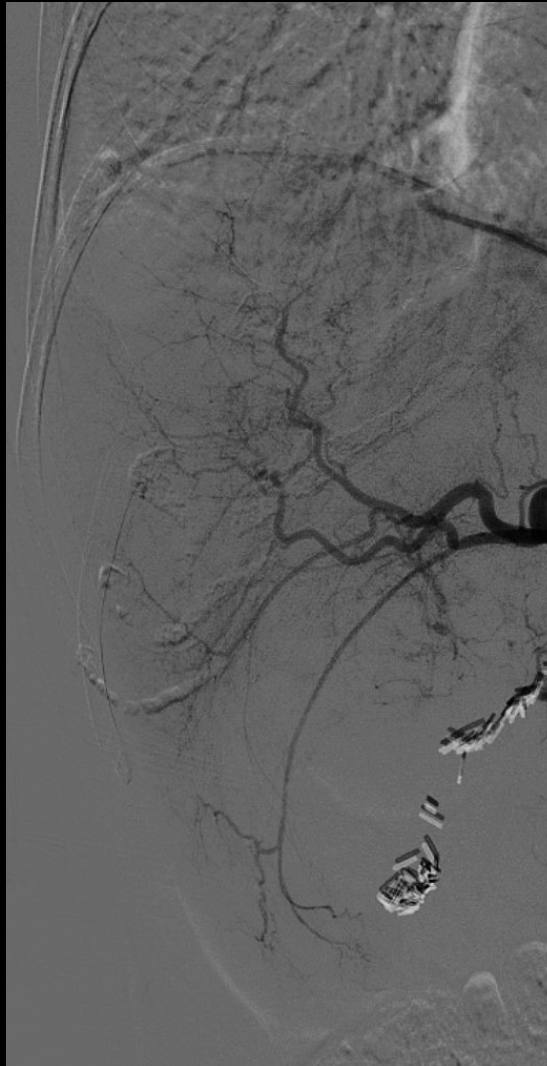

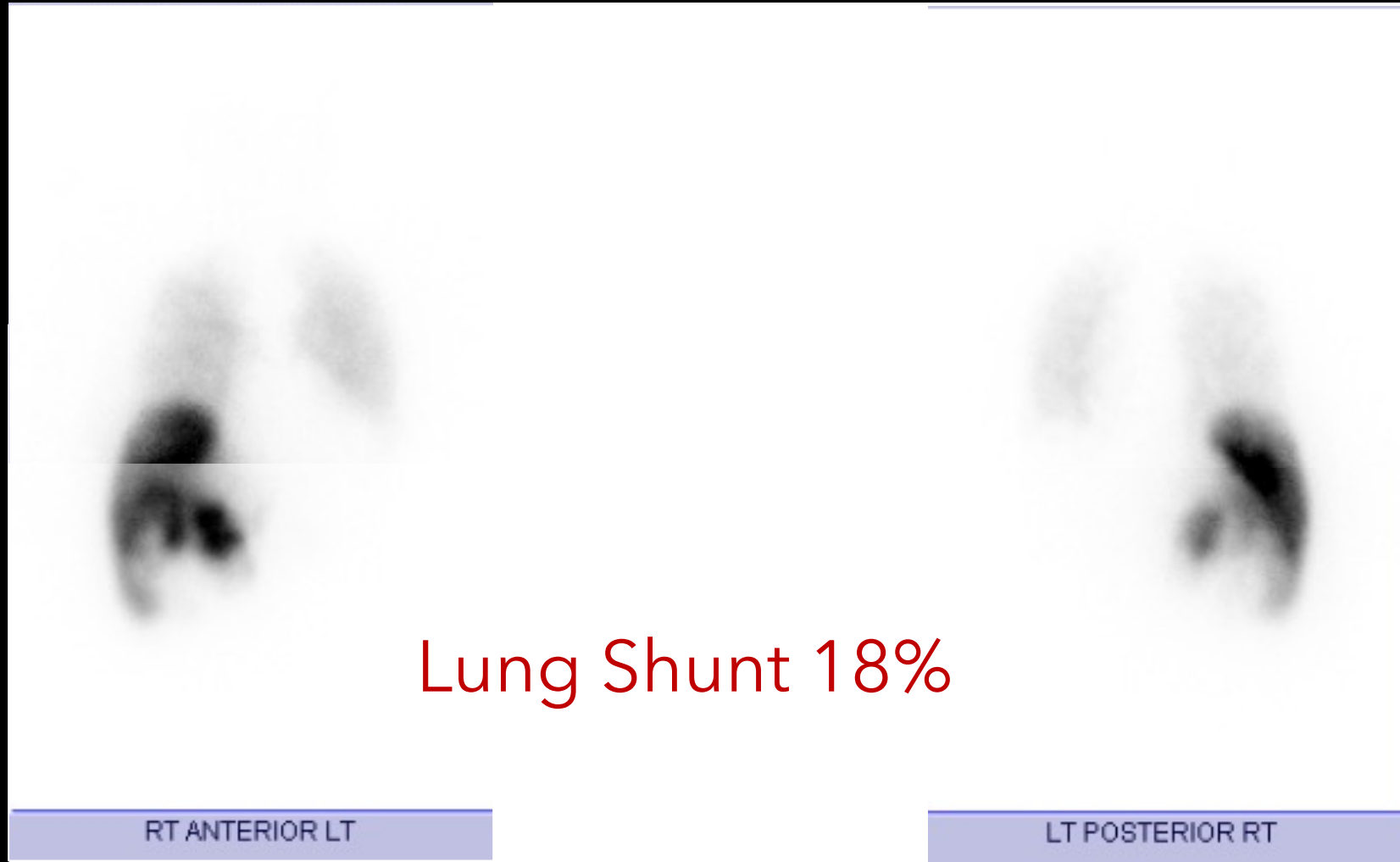
6.27.18 Redo-Mapping

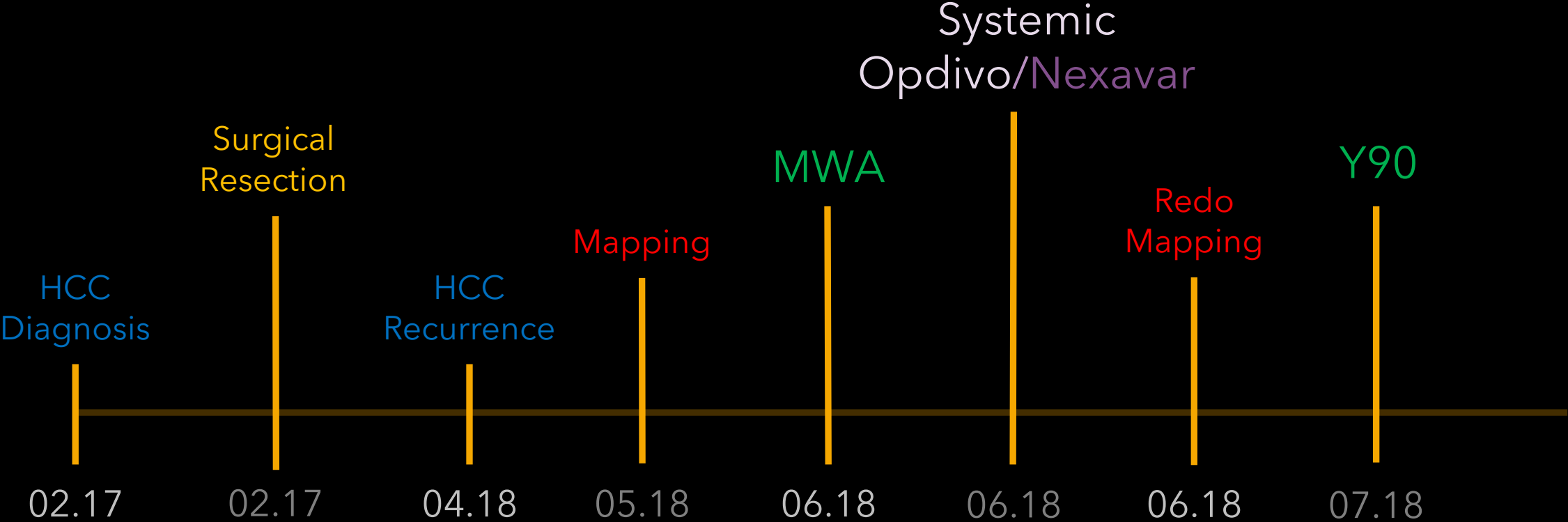


7.19.18

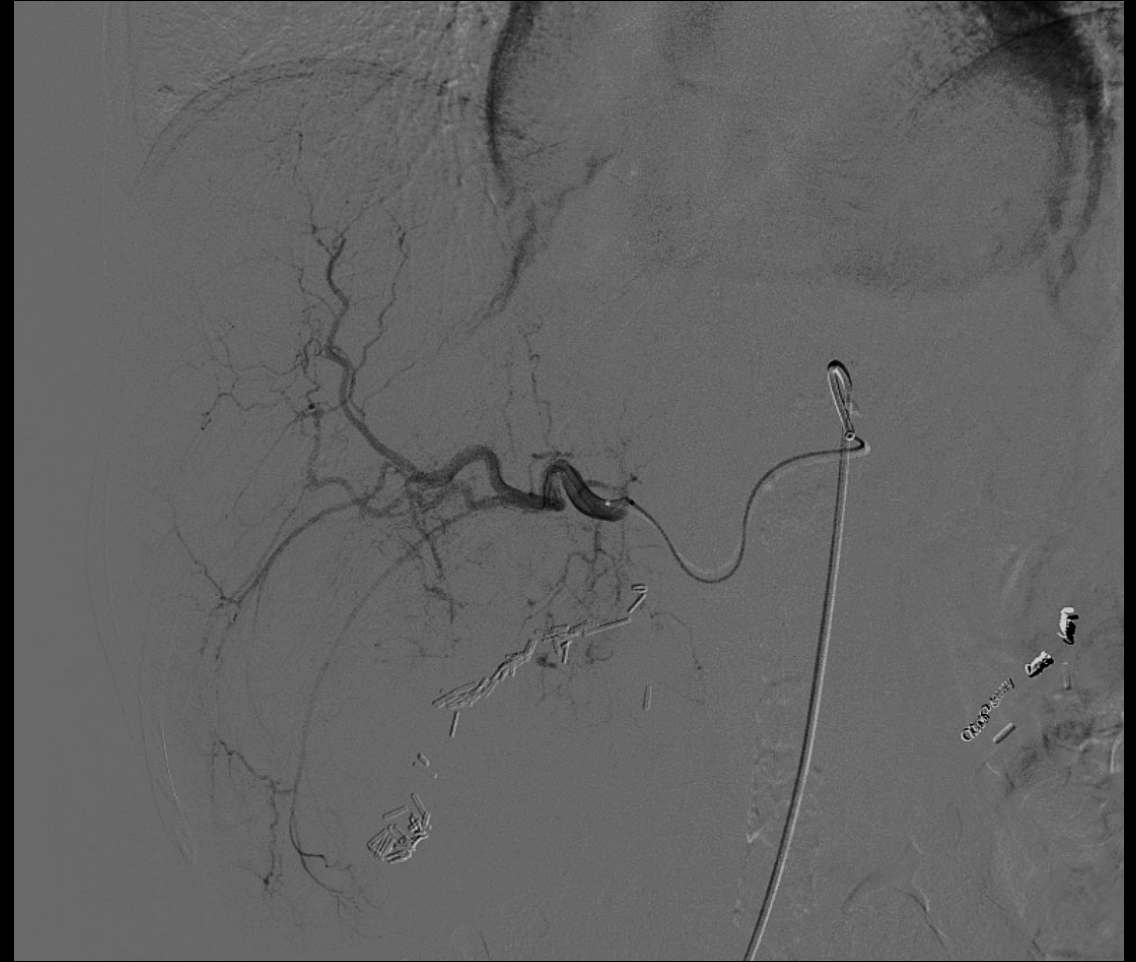
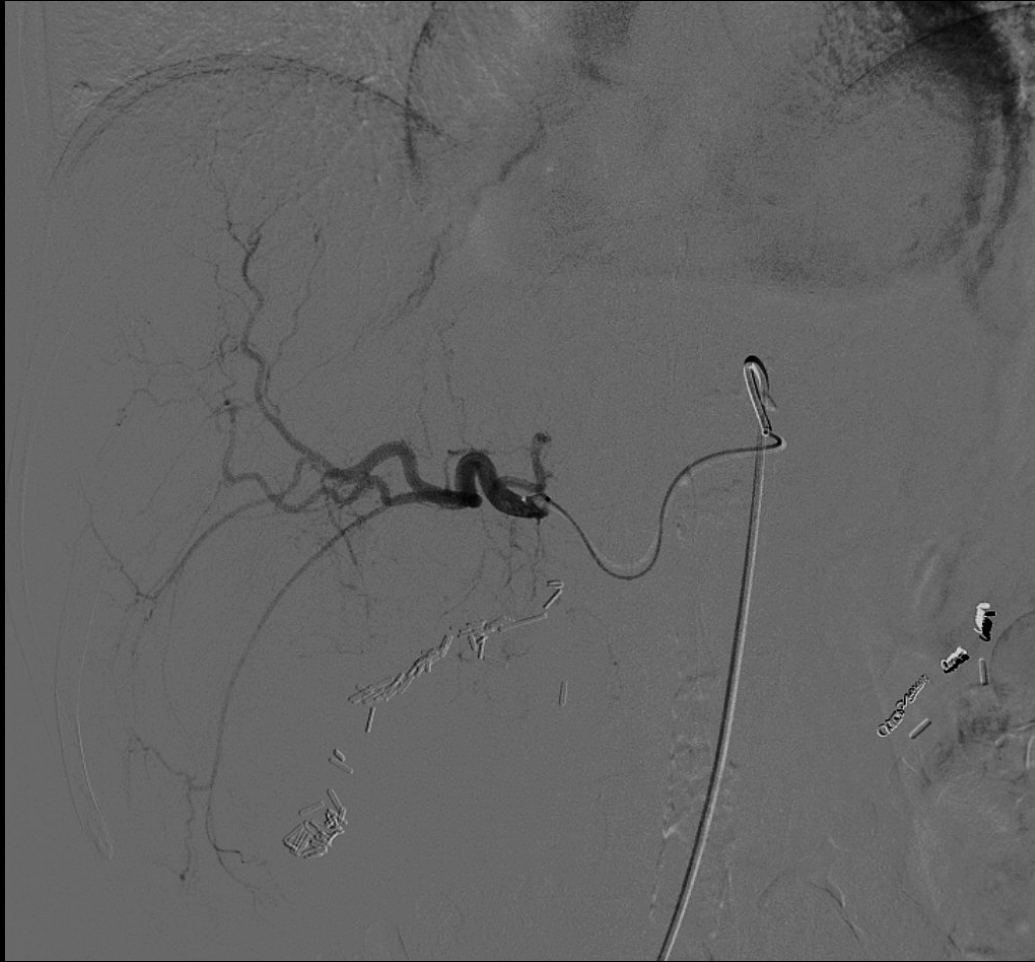

6.27.18

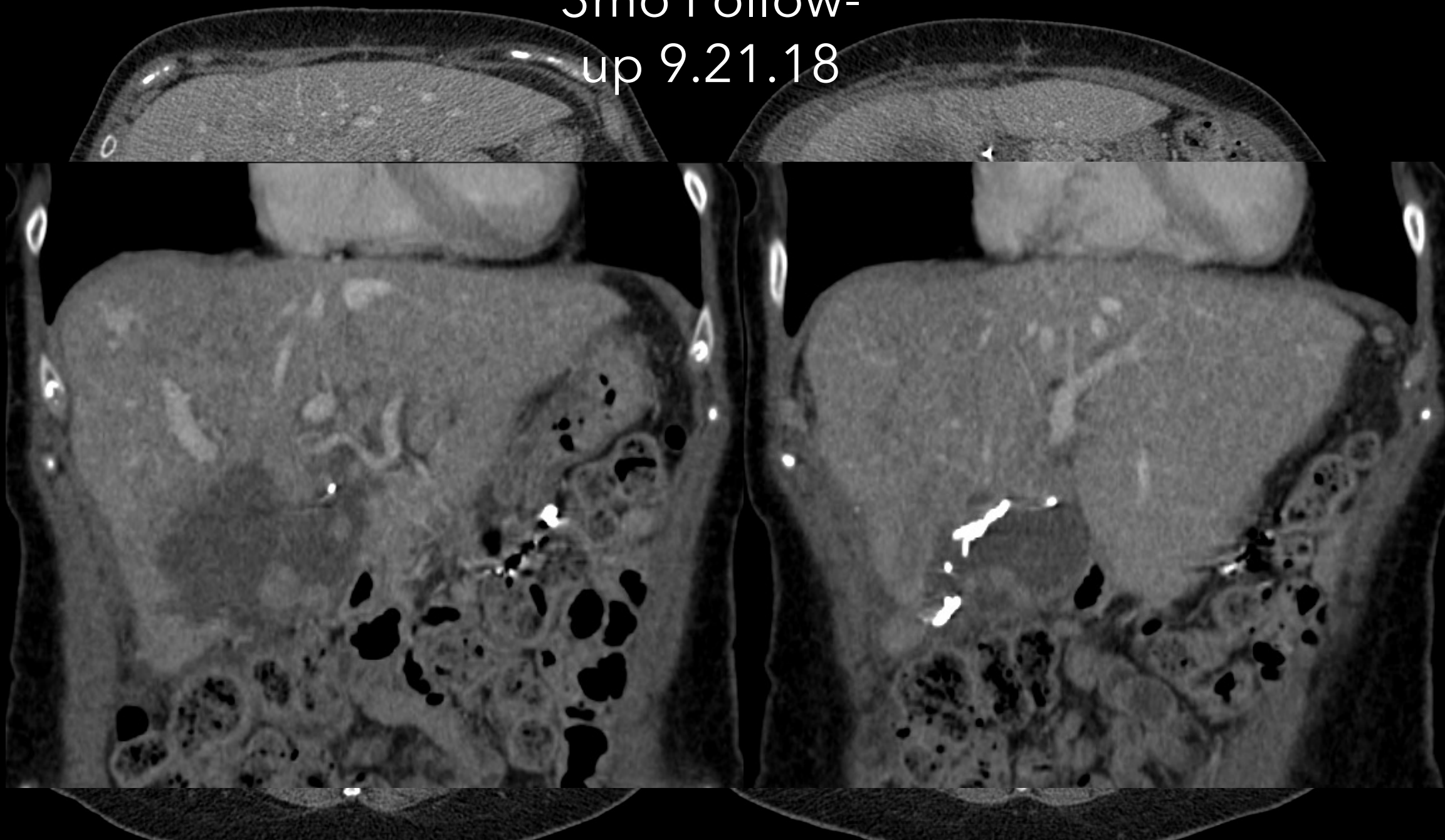




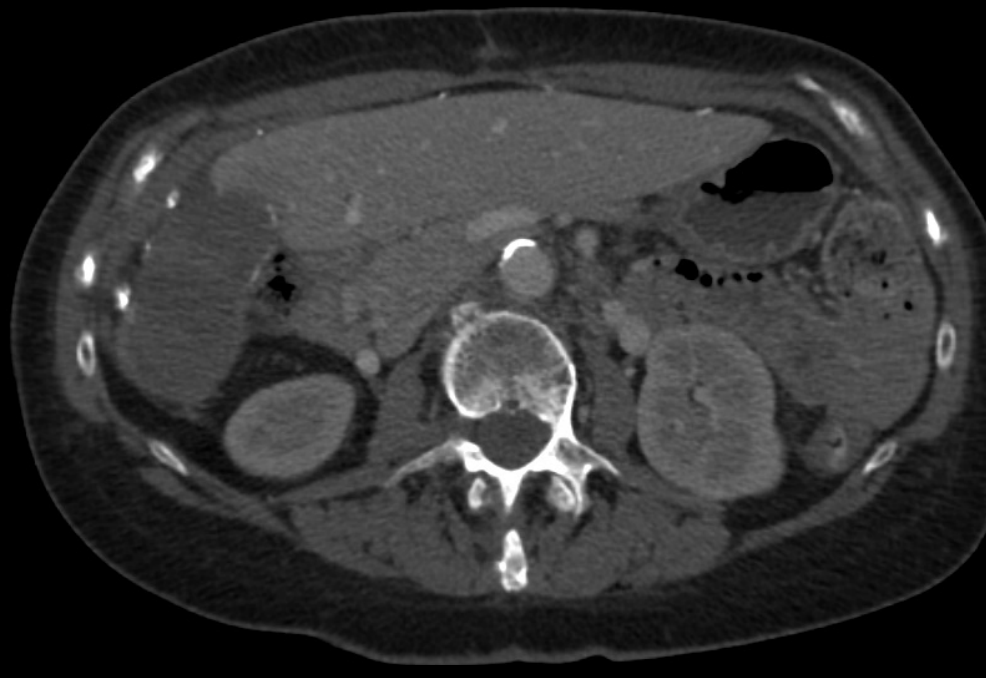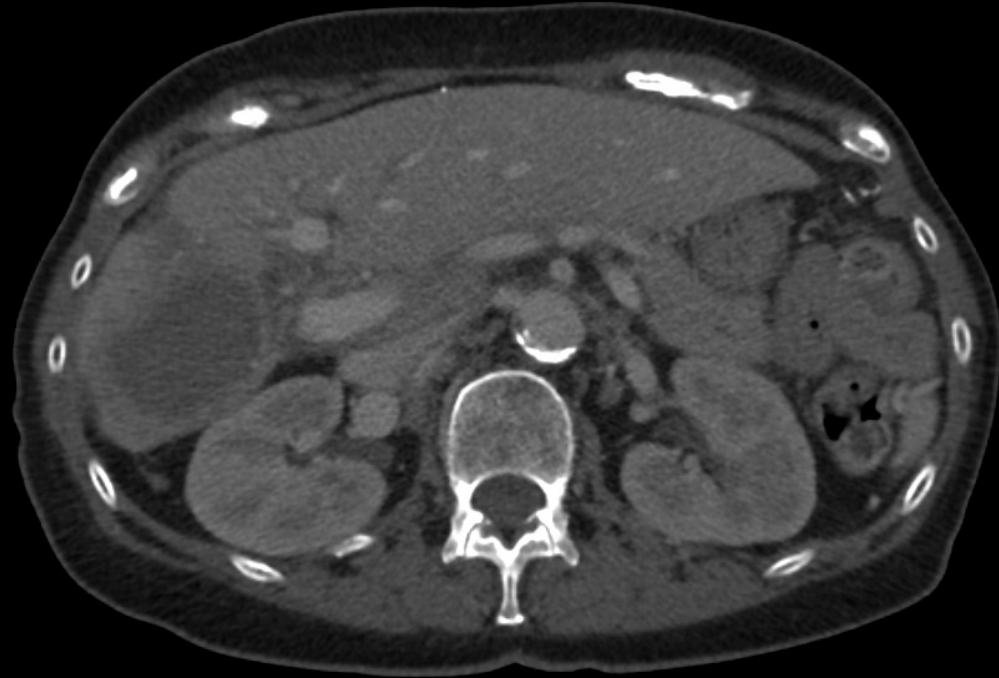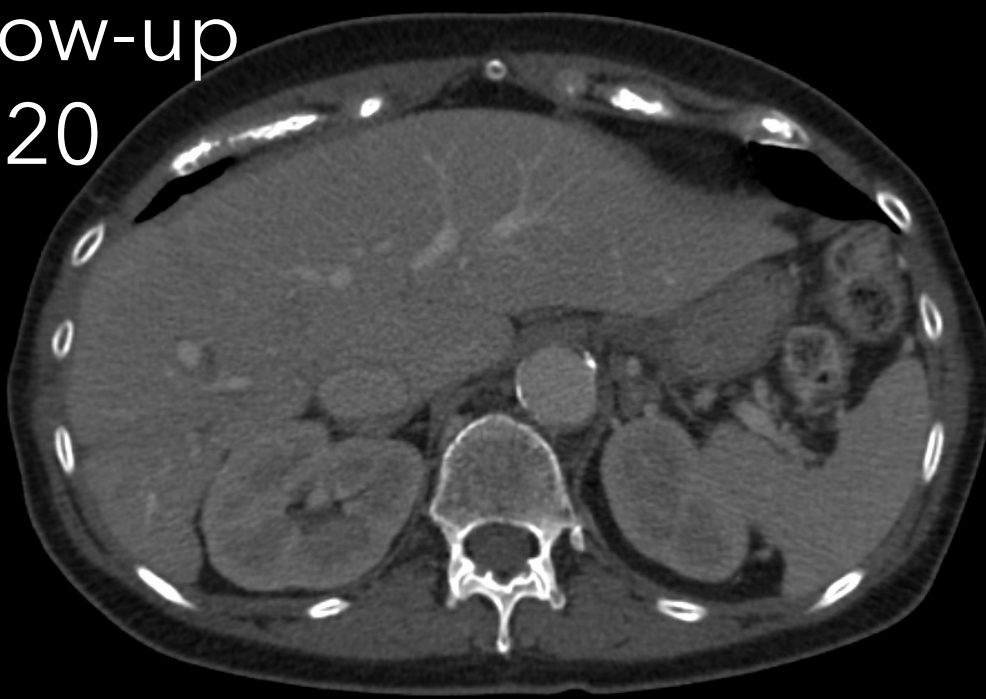
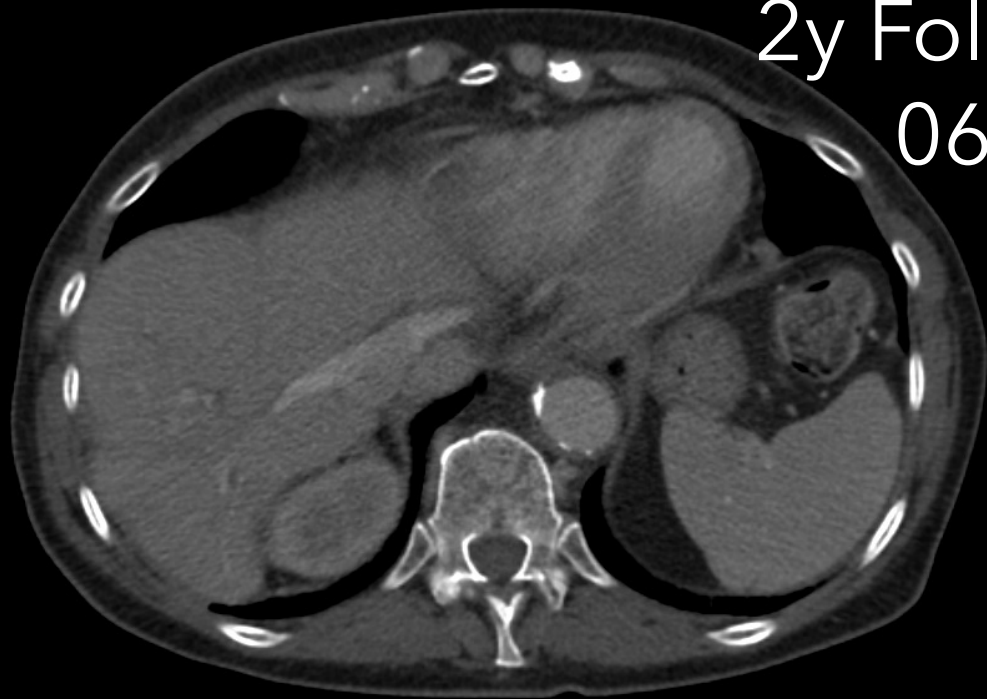7.19.18
Y90



3mo Follow-
up 9.21.18



2y Follow-up
06.20



| Case

52 year-old male with Metastatic Prostate Cancer on androgen deprivation therapy and Tanezumab who present with significant LEFT shoulder pain

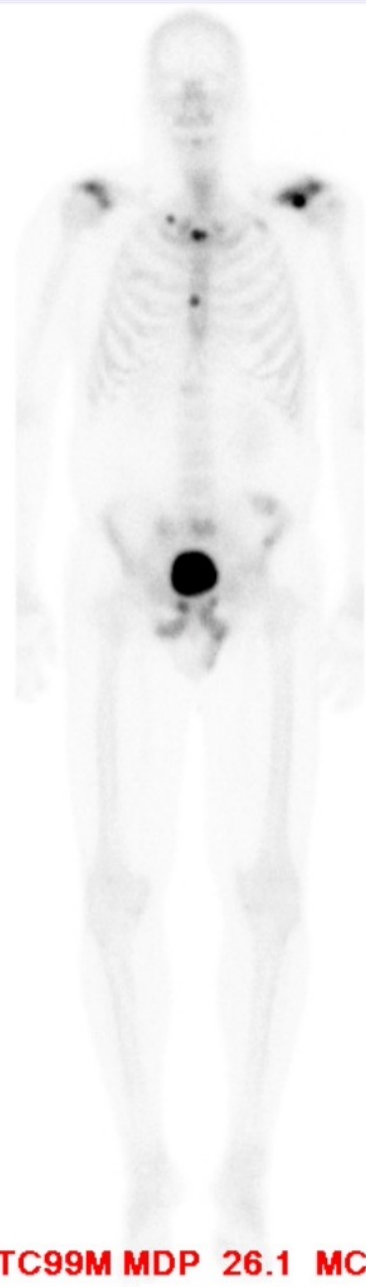
Metastatic bone lesion LEFT scapula (Spine/Acromioclavicular)

- Treated with RT (400 cGy)

2015

WHOLEBODY 9/10/2015

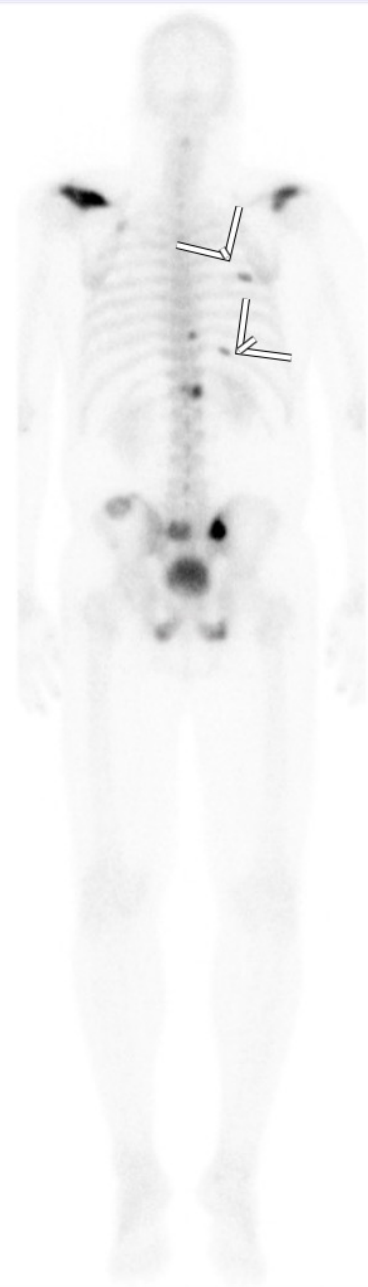
%



TC99M MDP 26.1 MCI

RT ANT LT

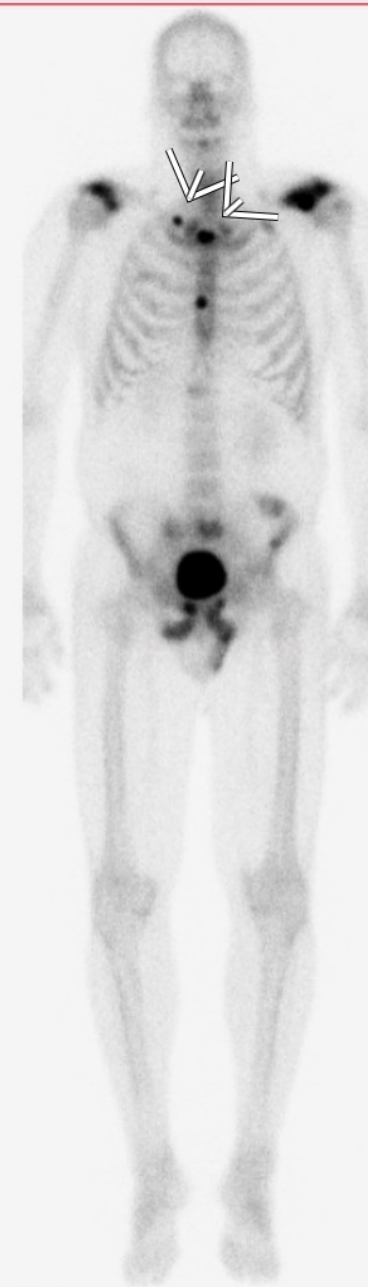(B:0%,T:31%)



LT POST RT

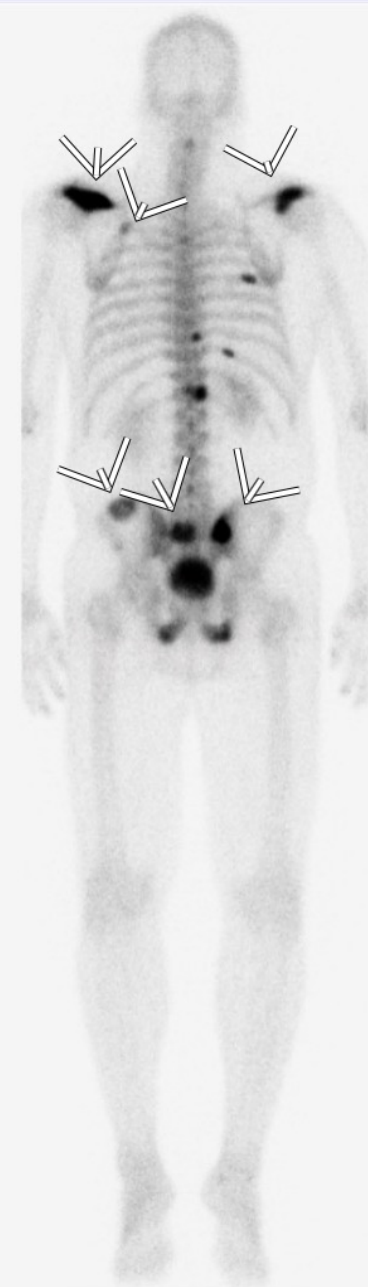
WHOLEBODY 9/10/2015

%



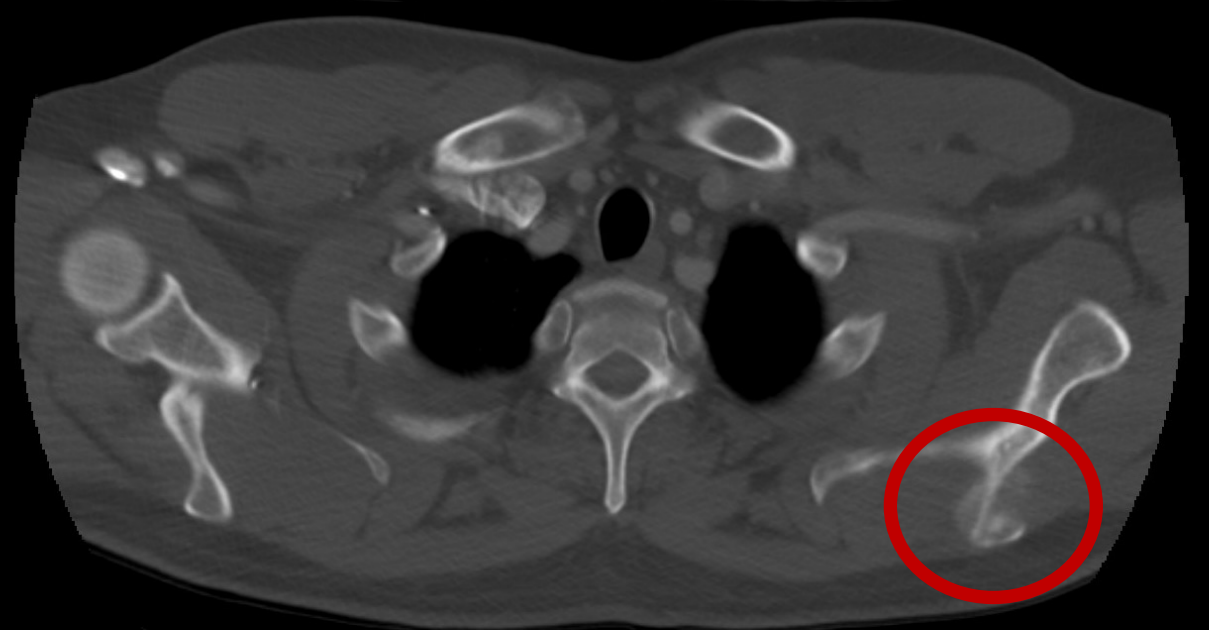
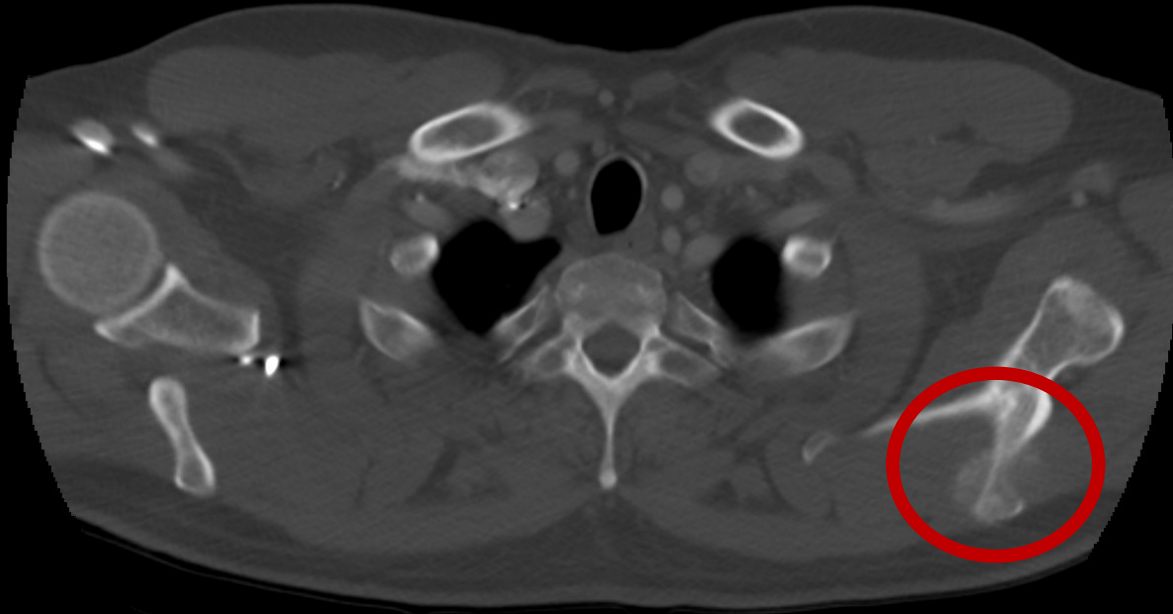
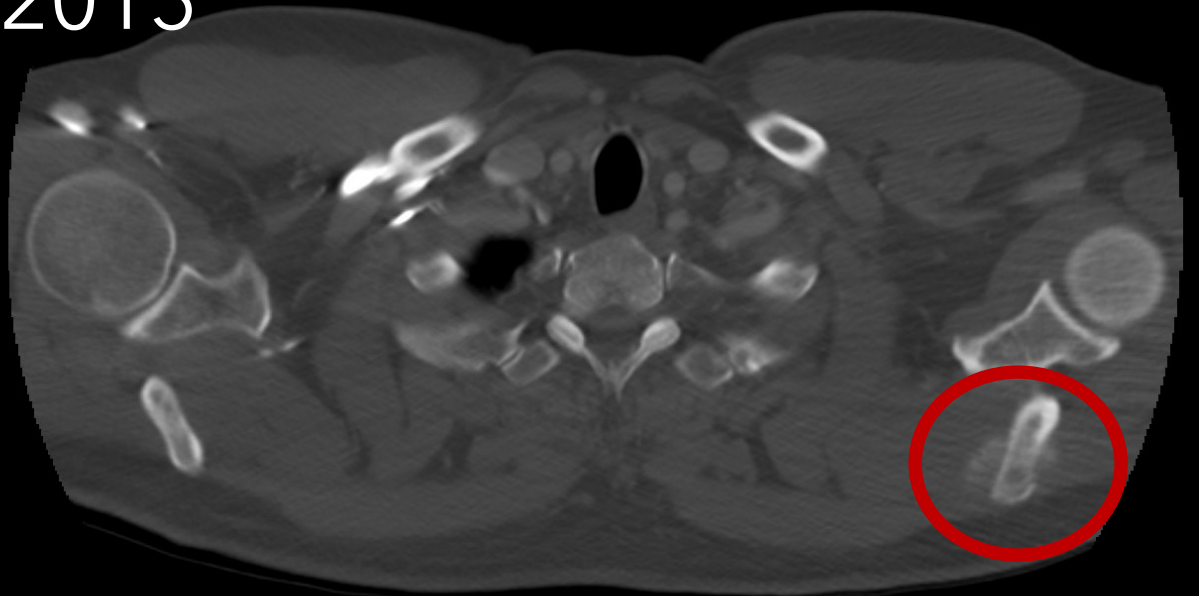
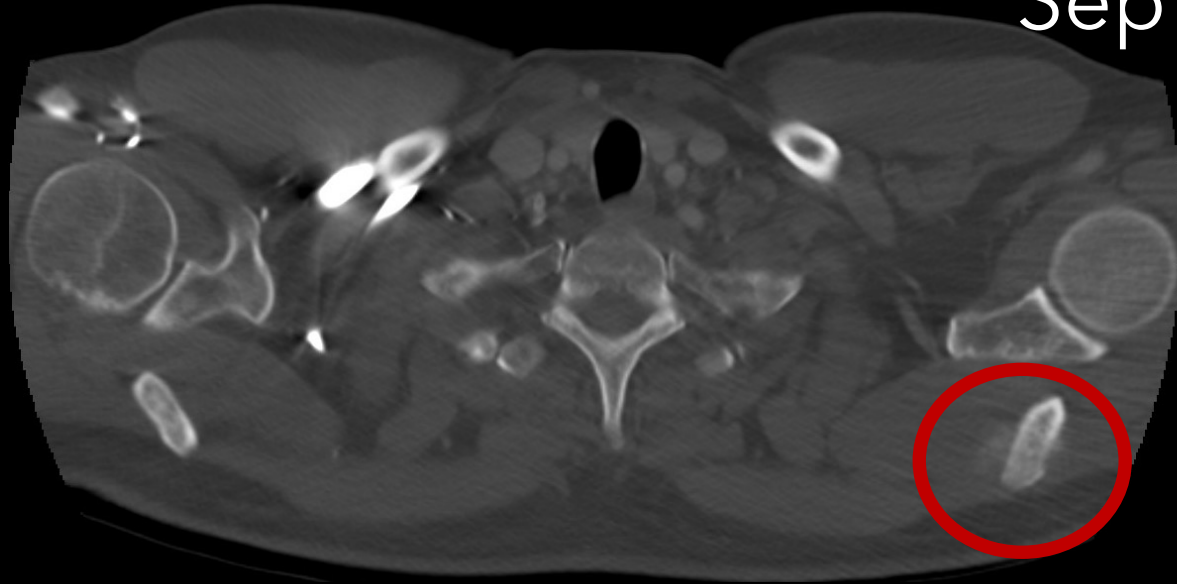
RT ANT LT

(B:0%,T:23%)



LT POST RT

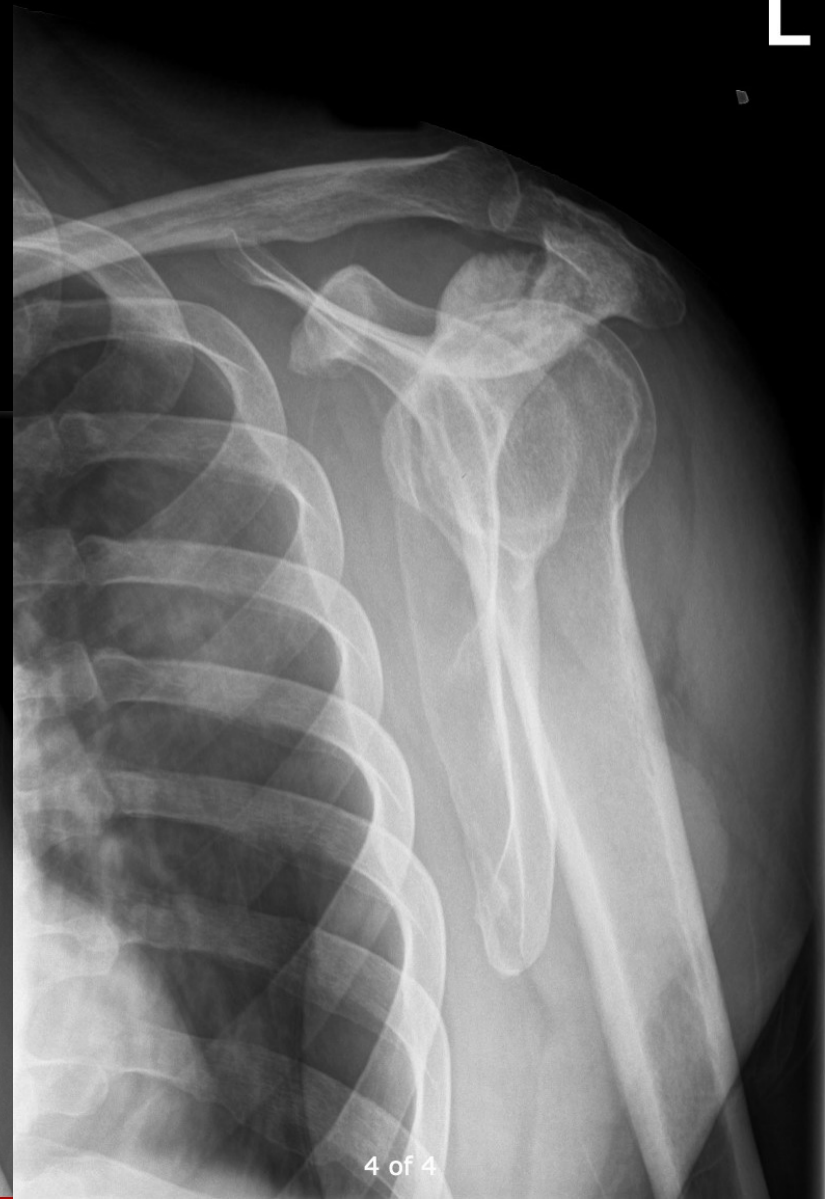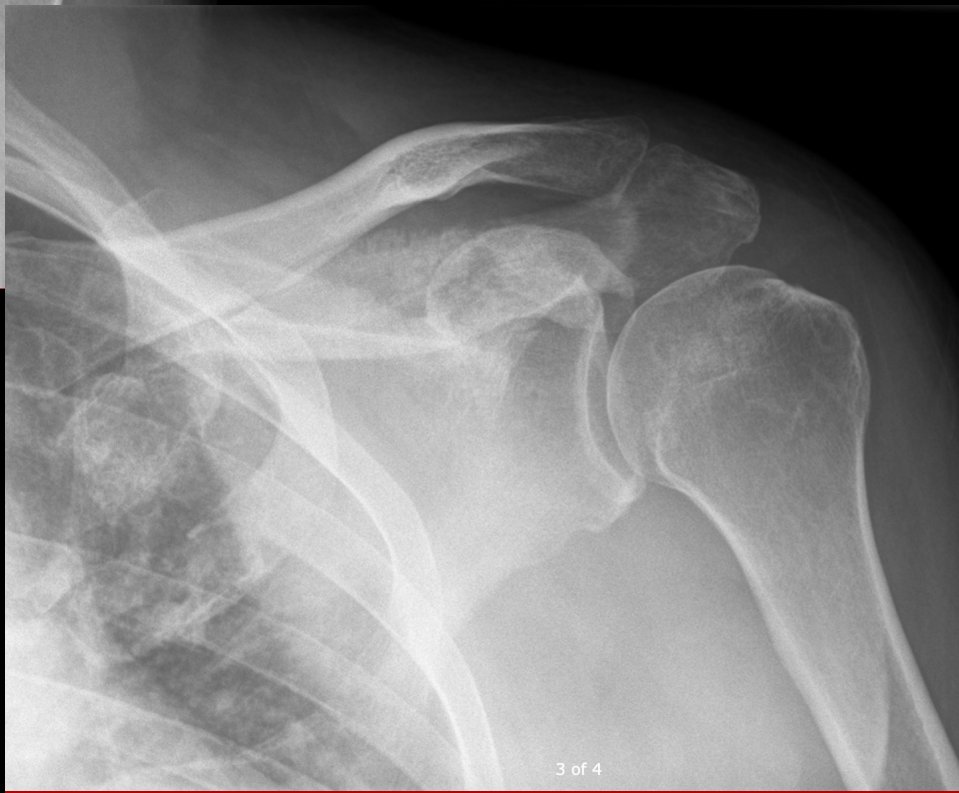
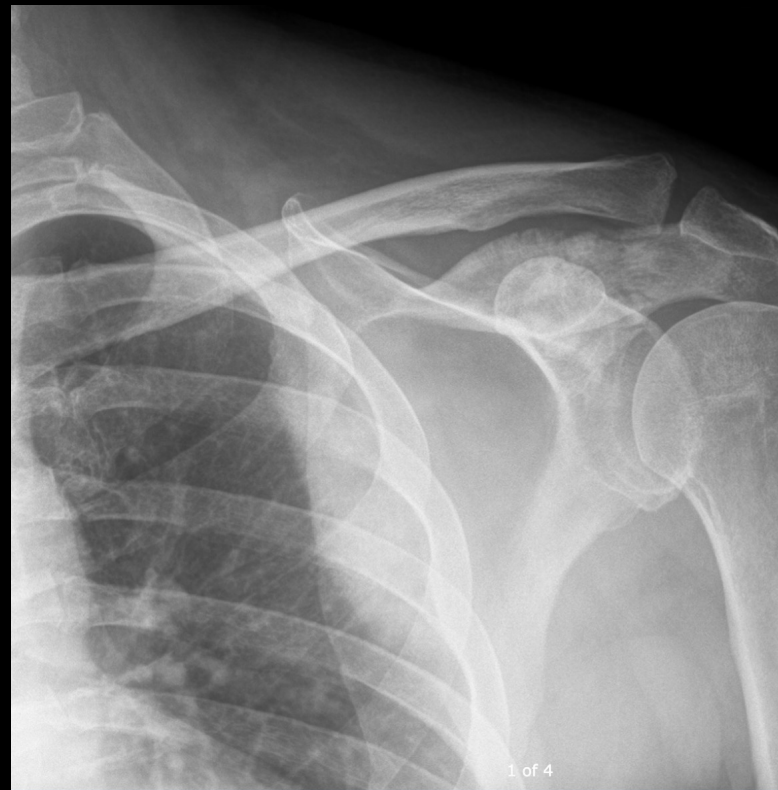Pre RT
Sep 2015



5m later

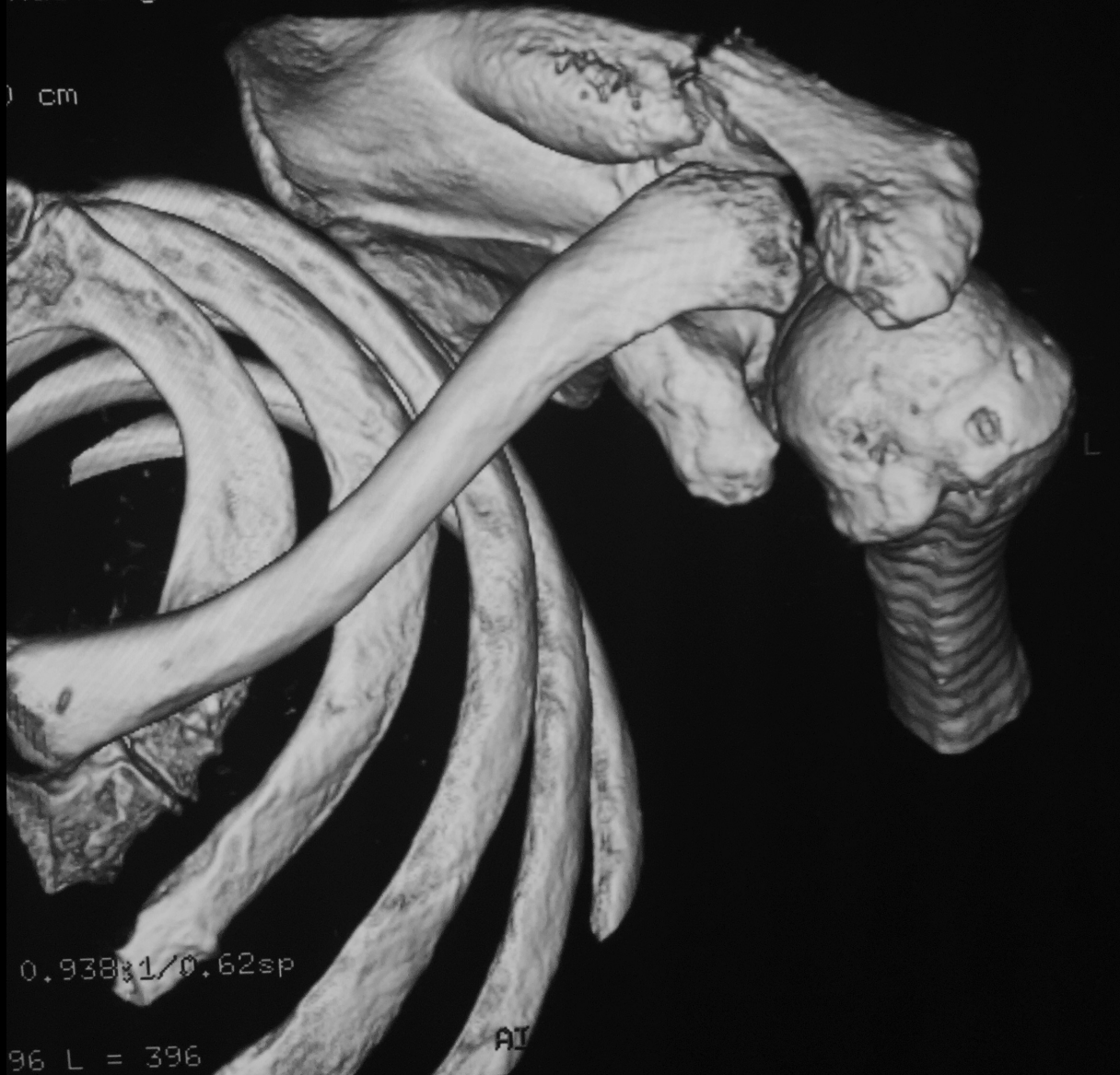
Severe LEFT shoulder pain
Decrease range of motion

Post RT
Feb 2016



ndering No cut

) cm



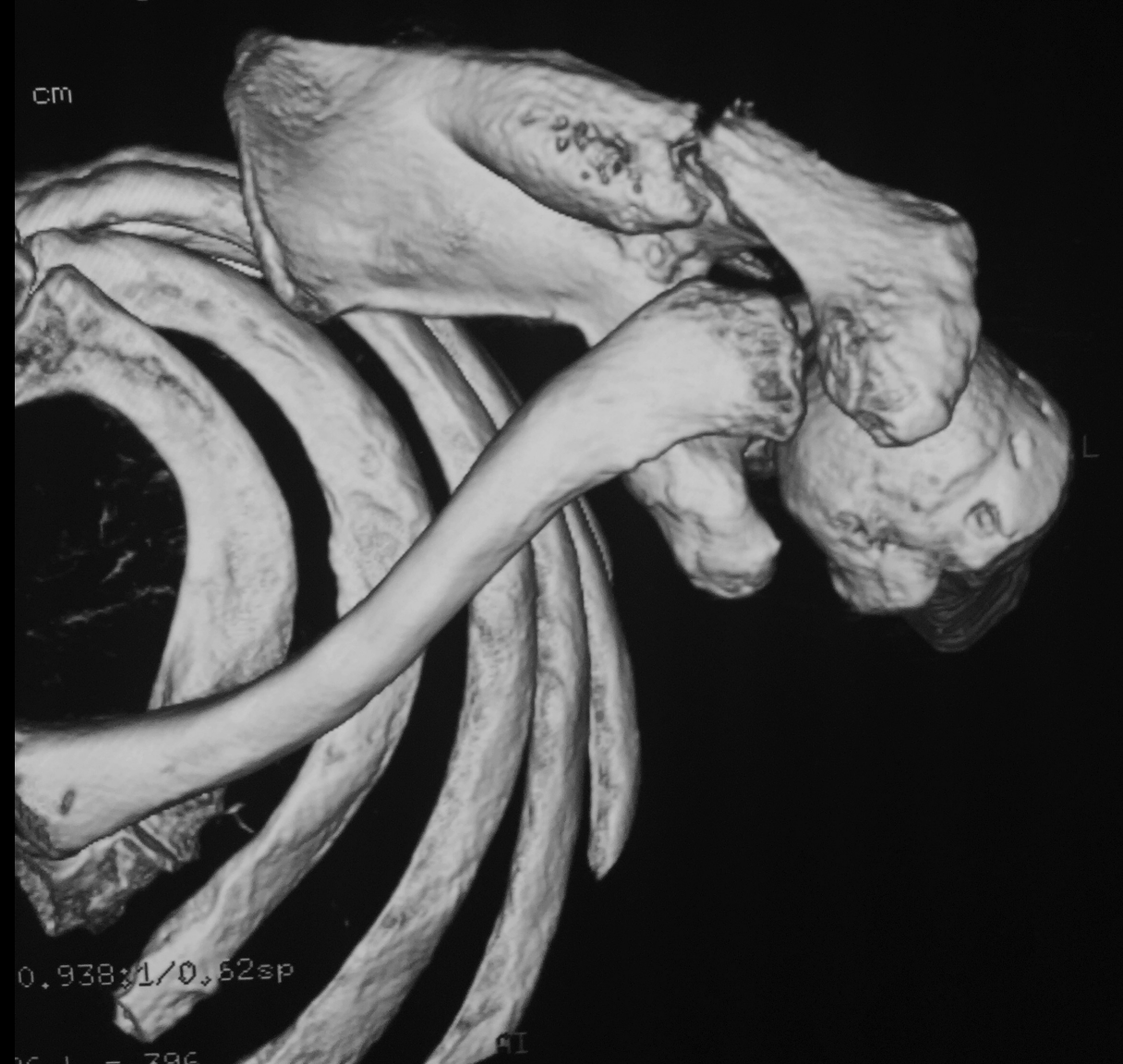0.938;1/0.62sp

96 L = 396

AI

ndering No cut

cm



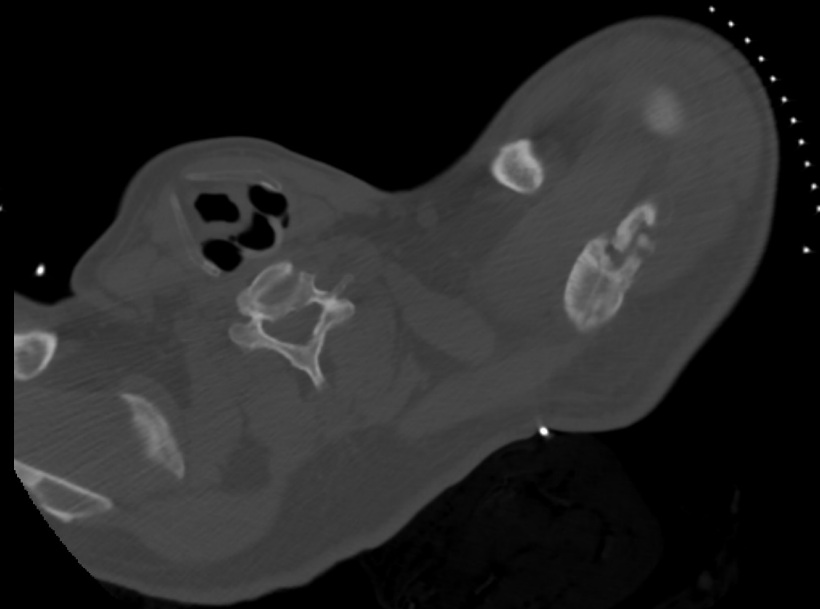
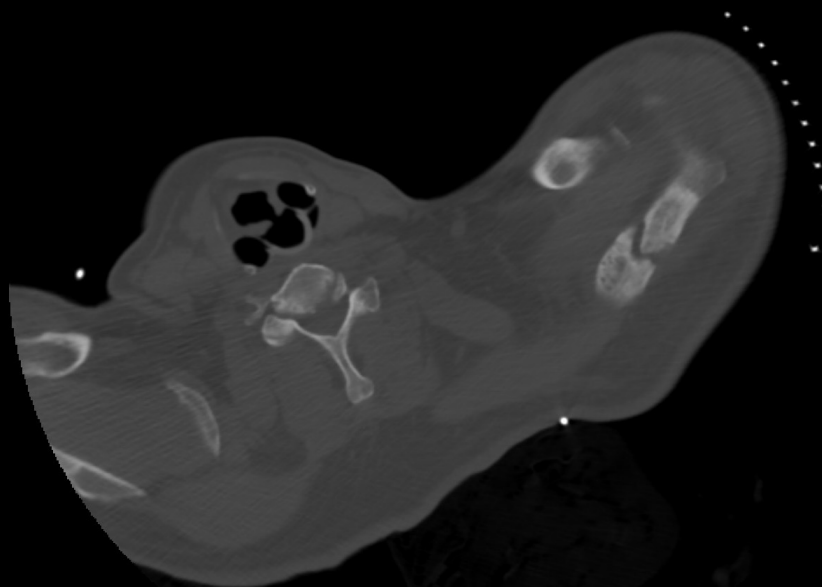
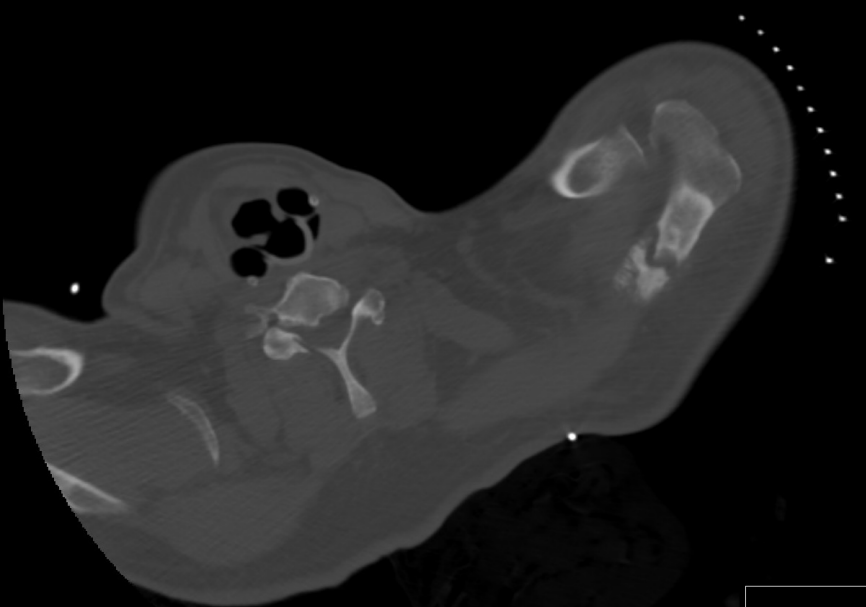
0.938;1/0.62sp

96 L = 396

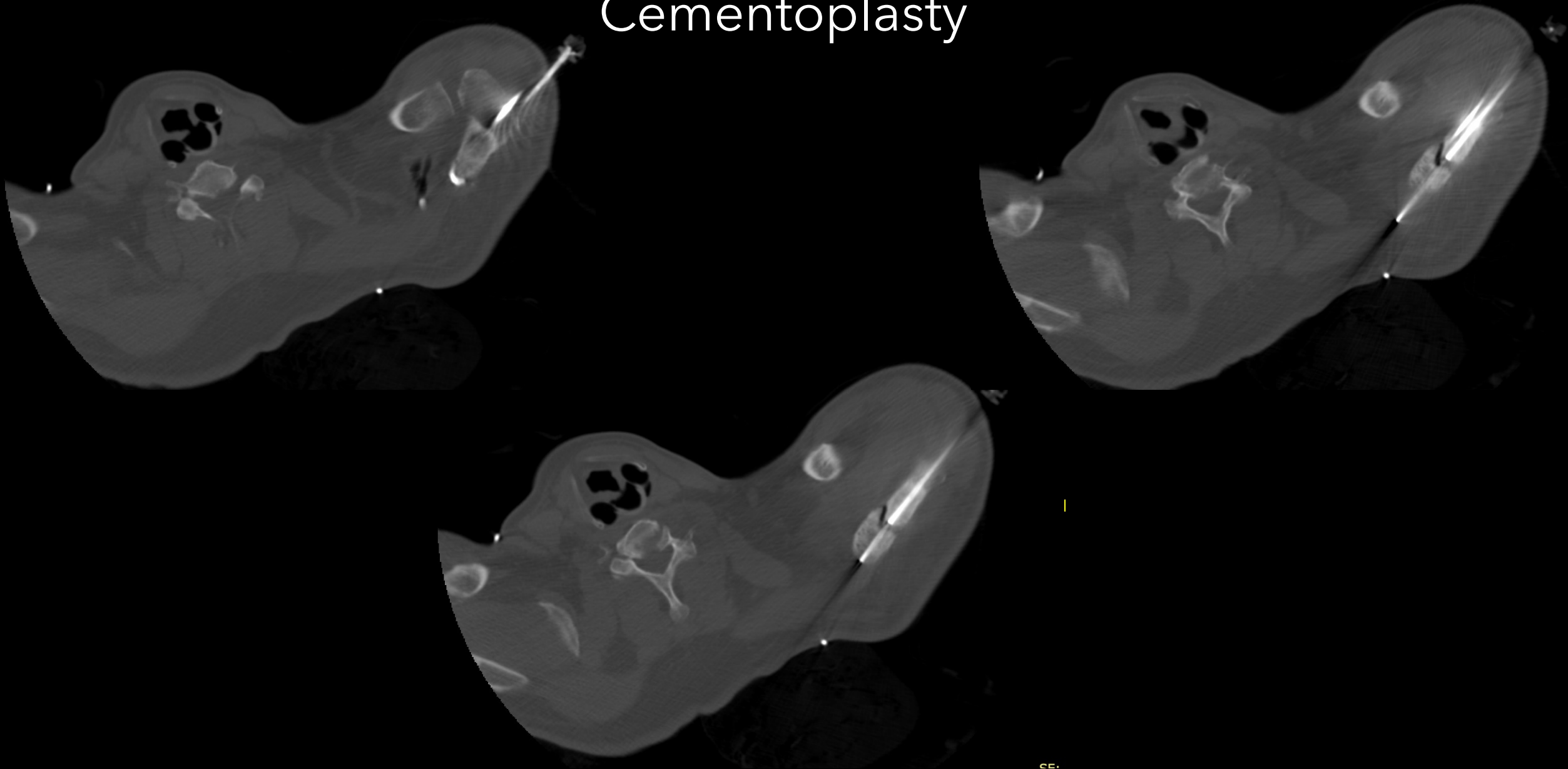
AI

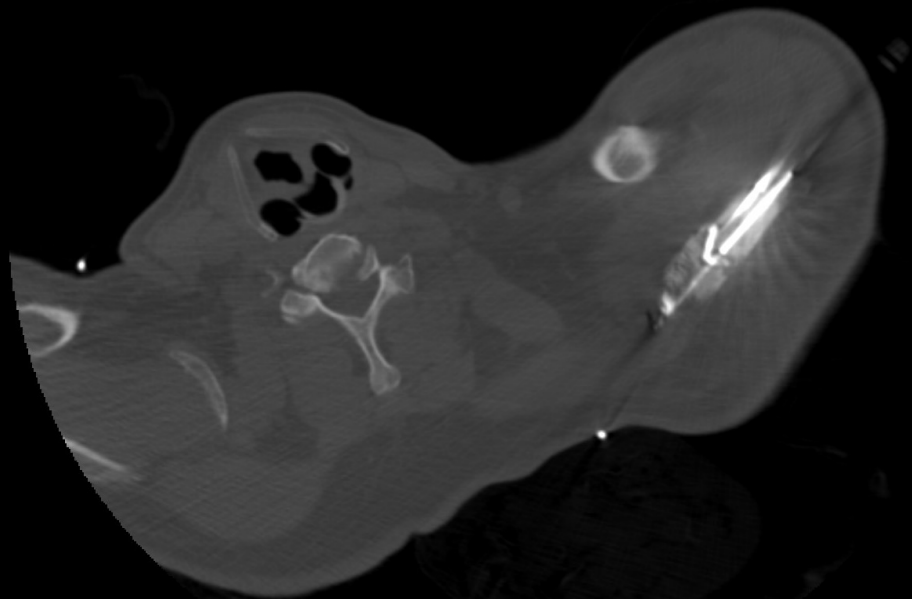
What can we offer?

Ablation Cementoplasty



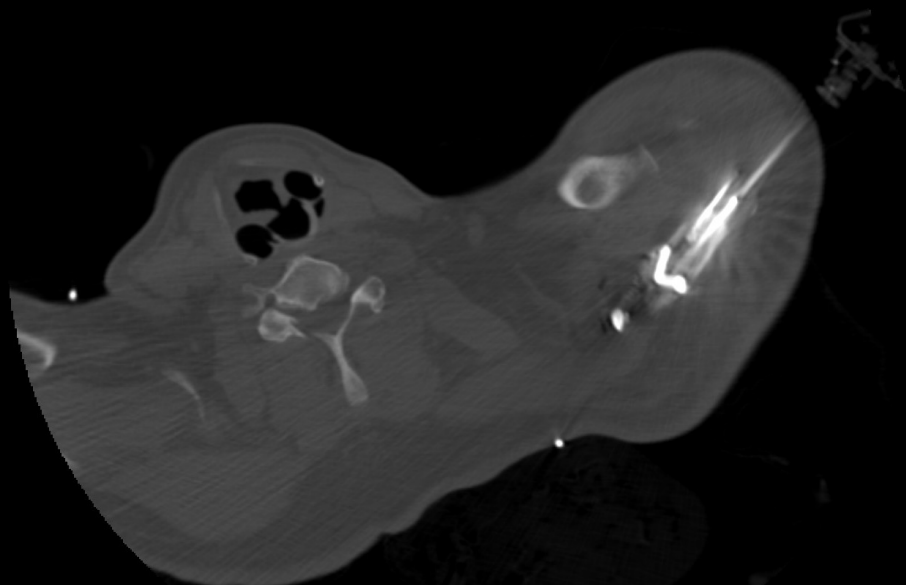
Ablation Cementoplasty





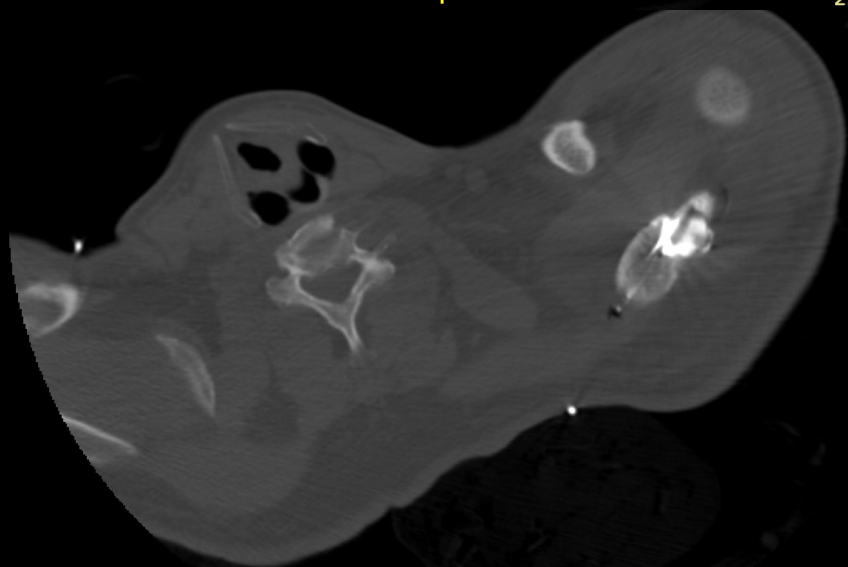
P

SE:
2.500000 mr



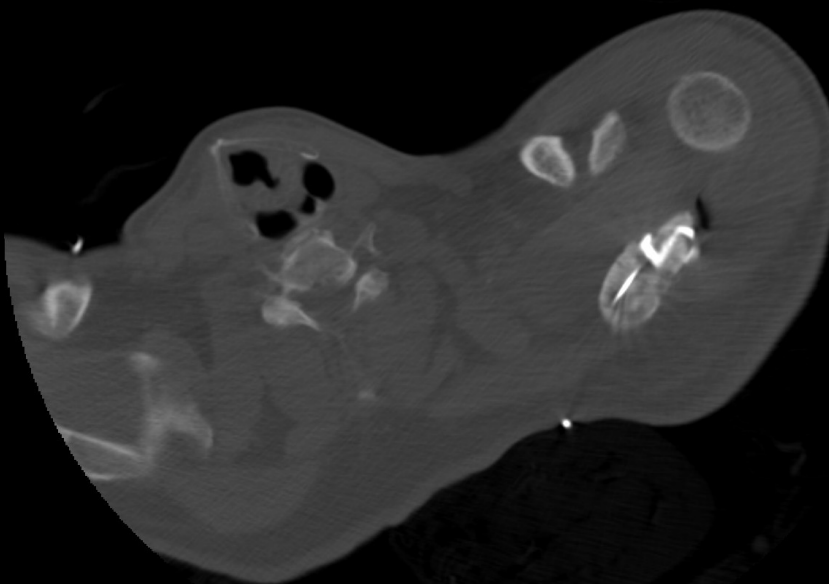
P

SE:
2.500000 mr



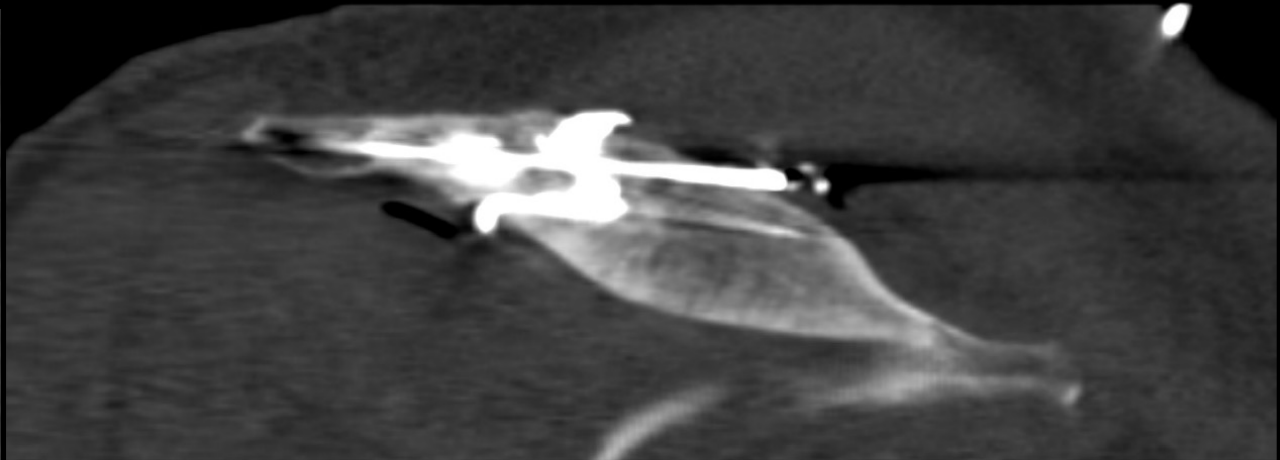
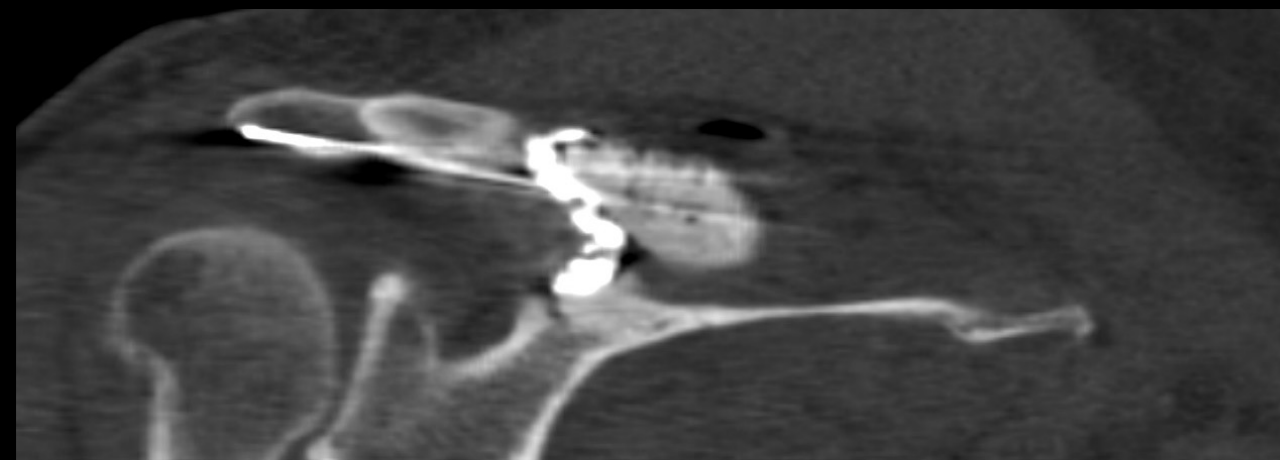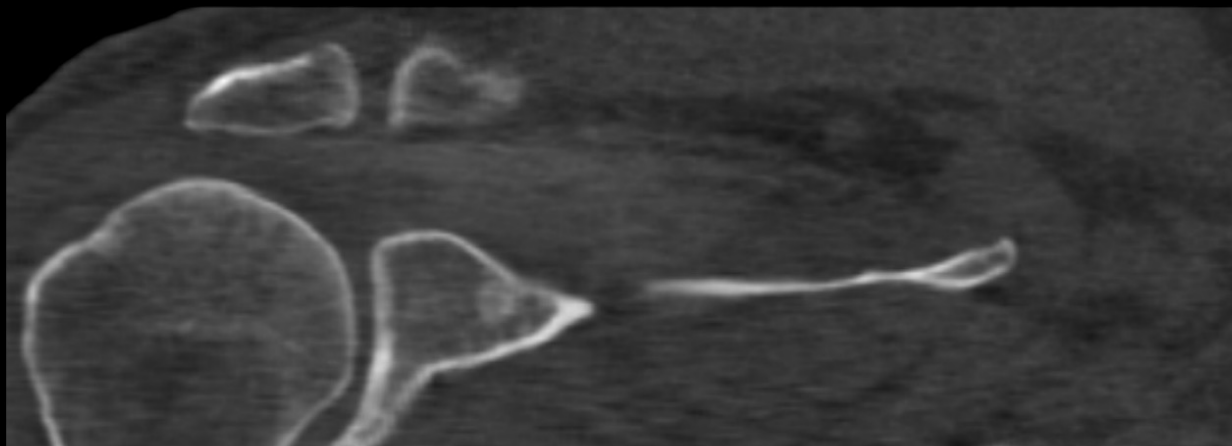P

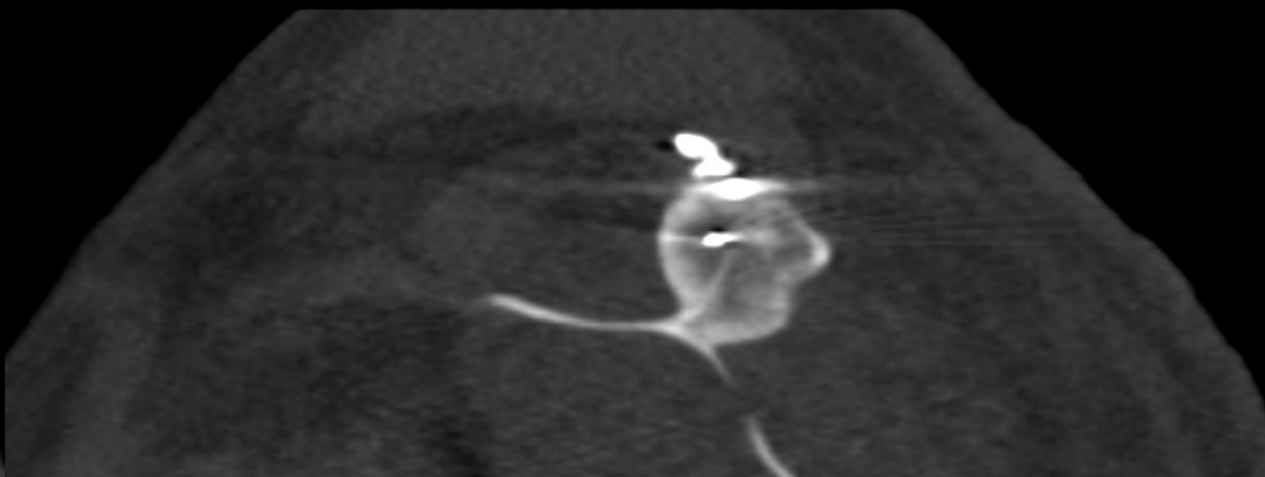
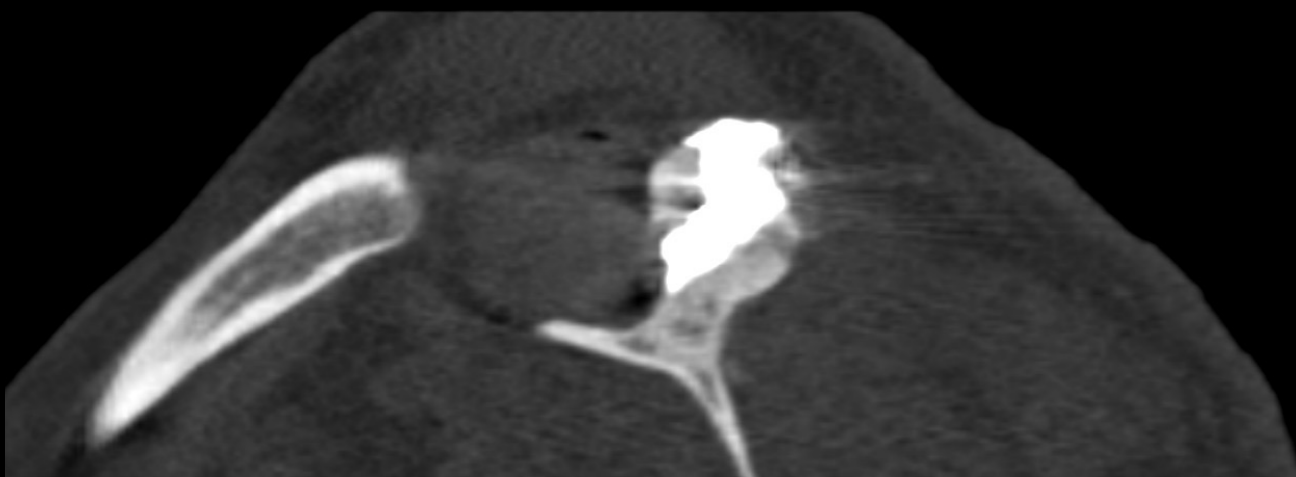
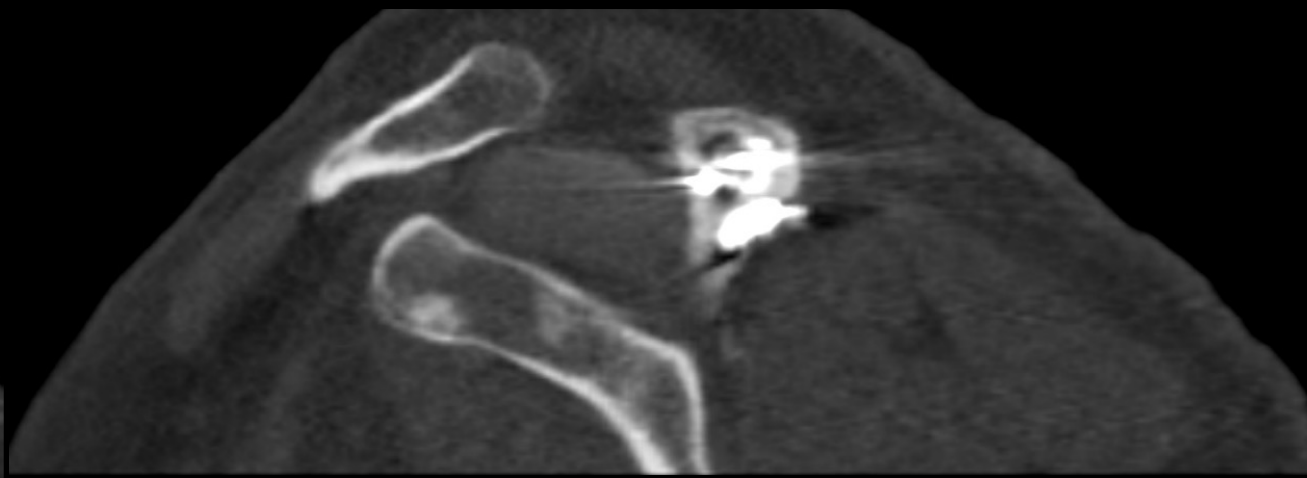
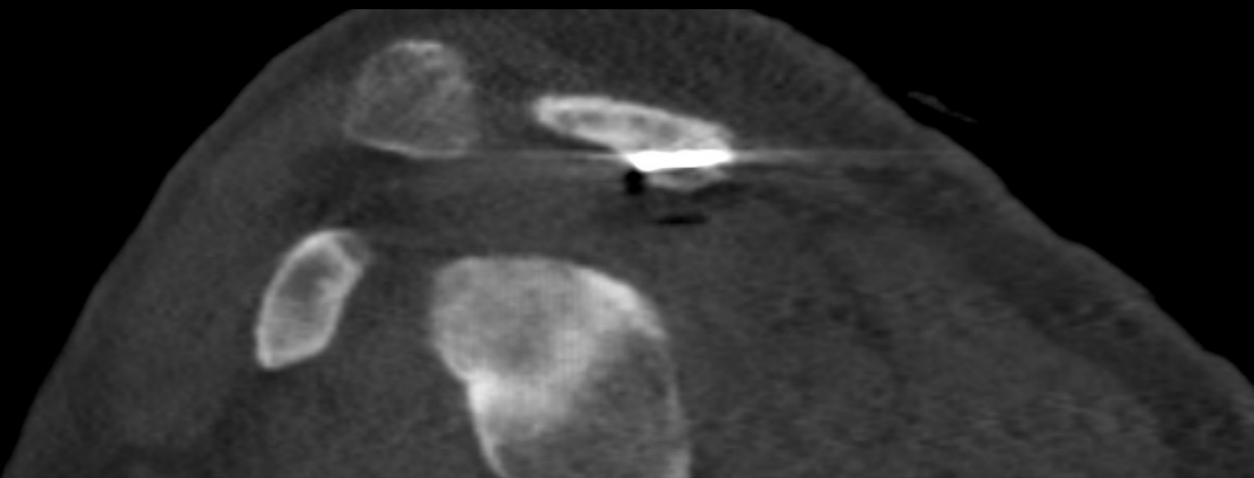
SE:
2.500000 mr

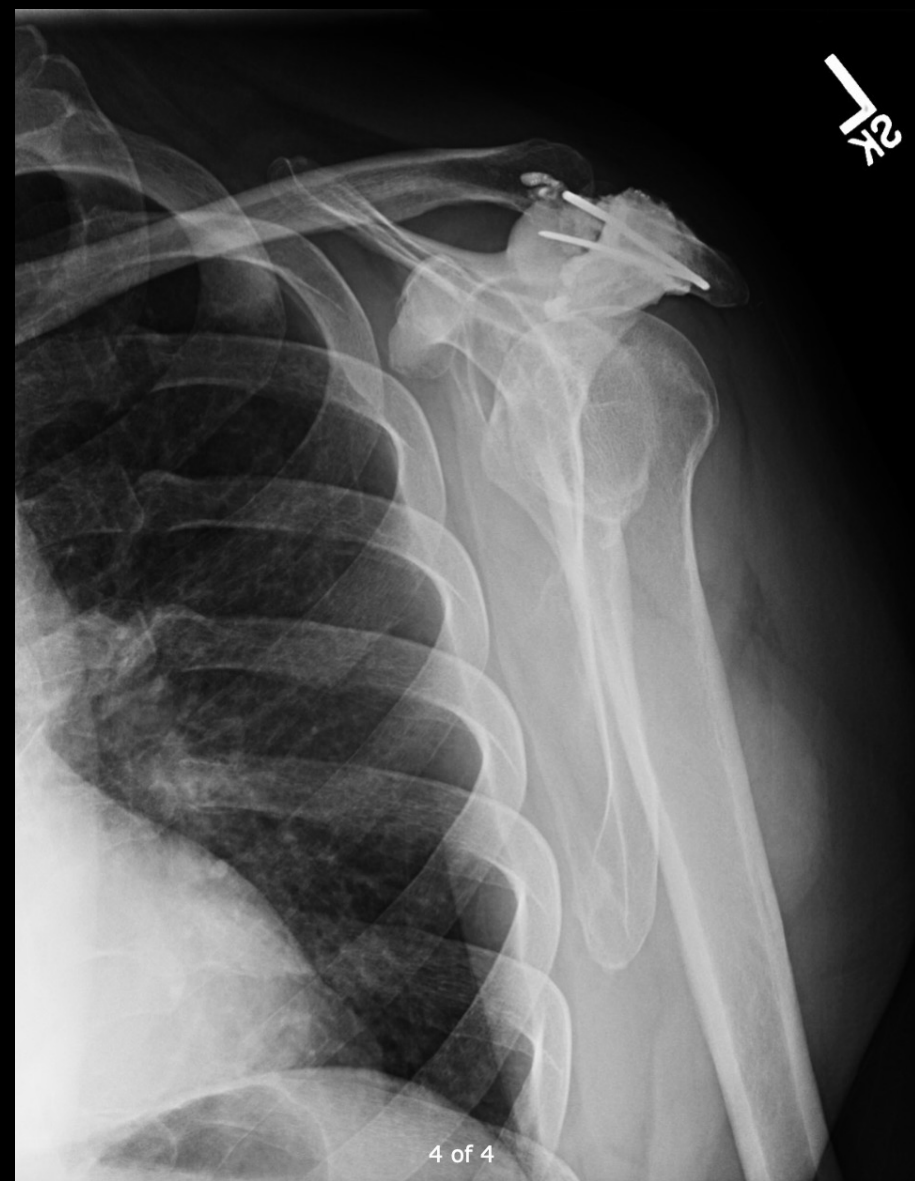
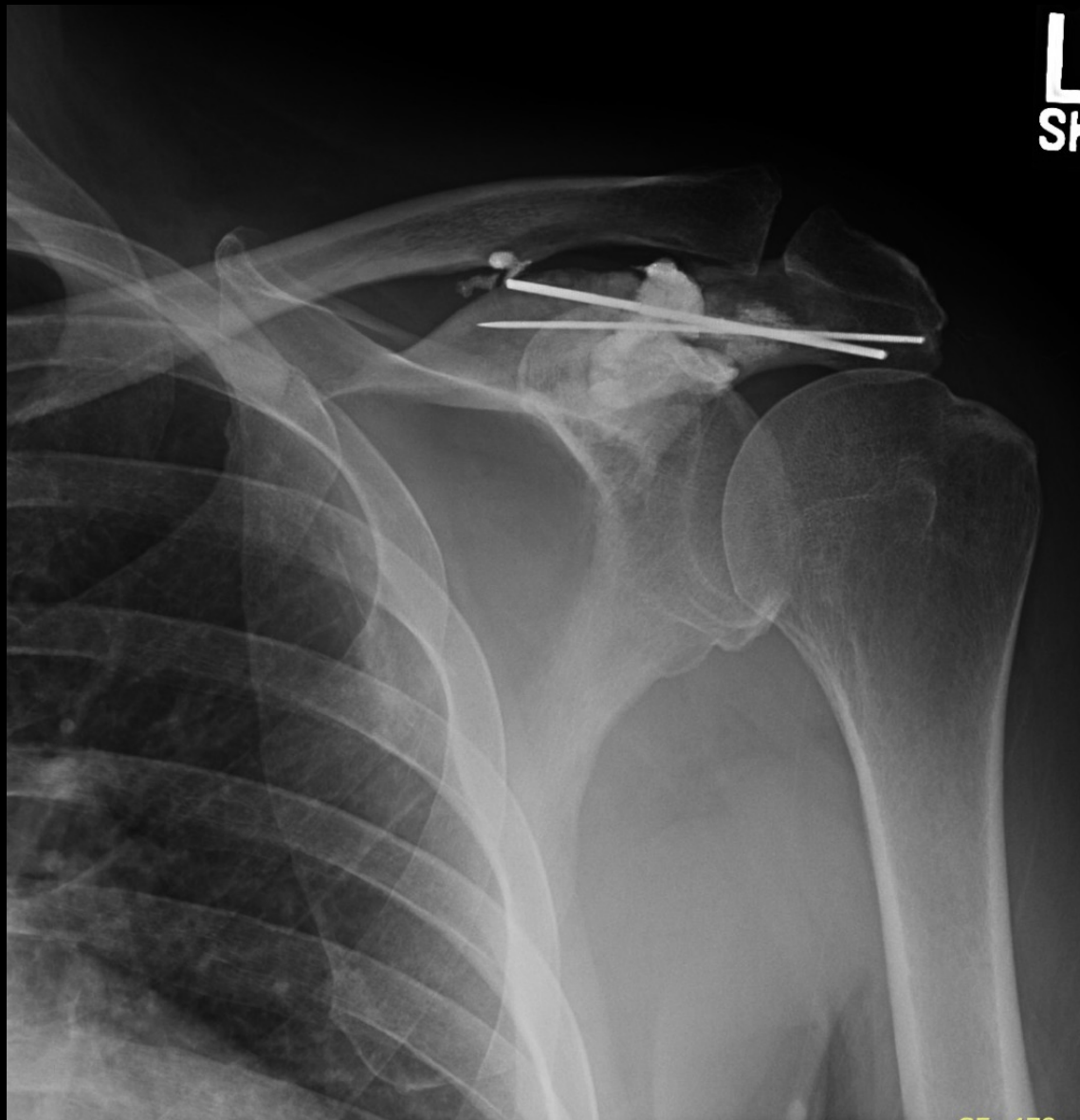
P

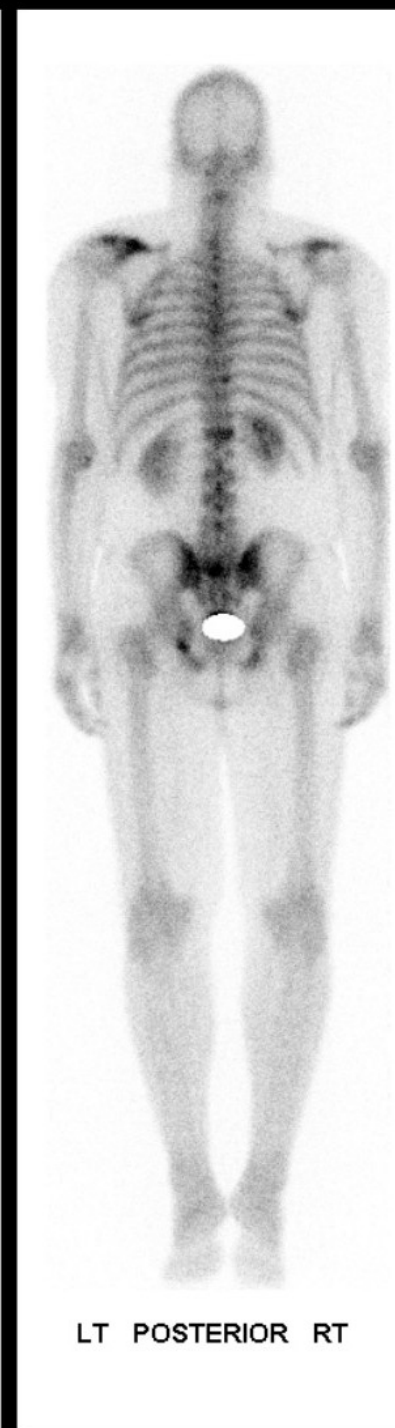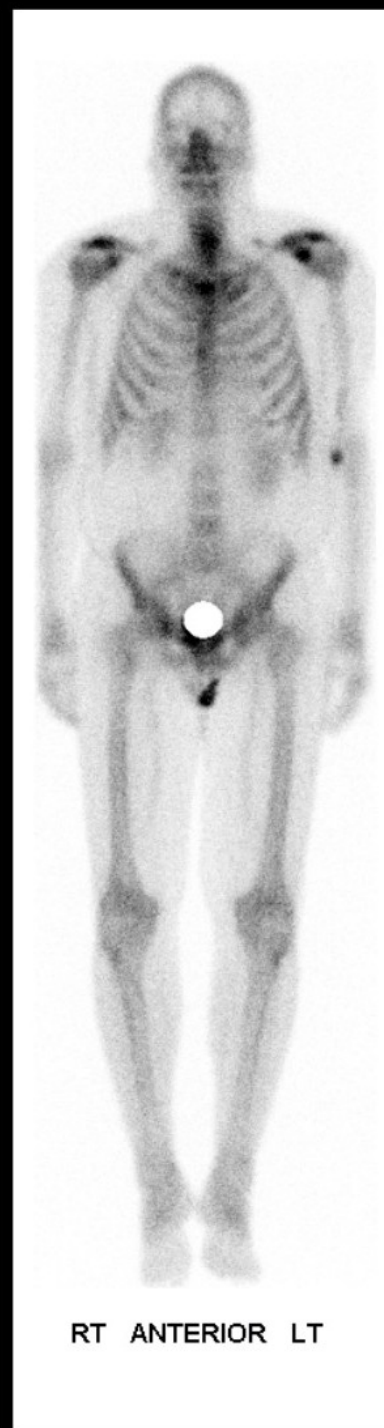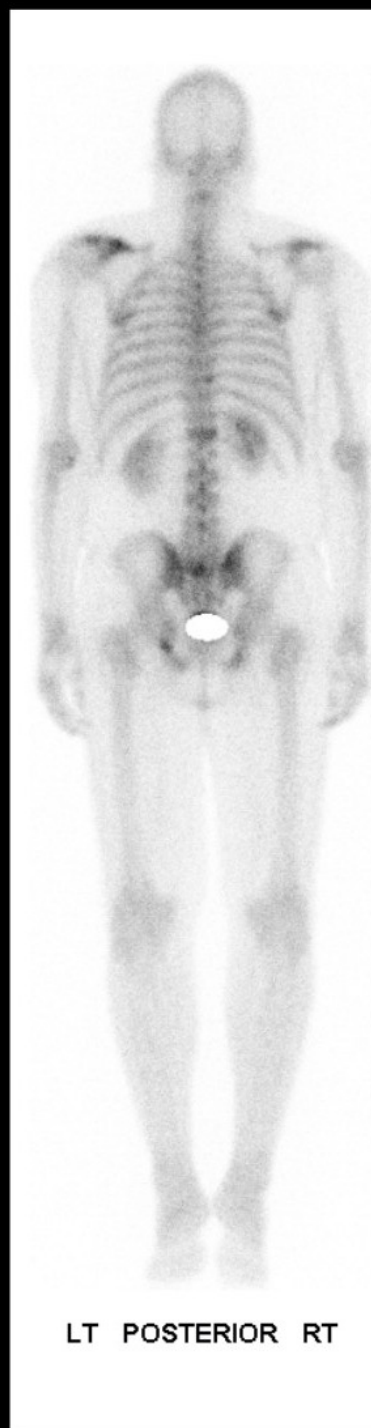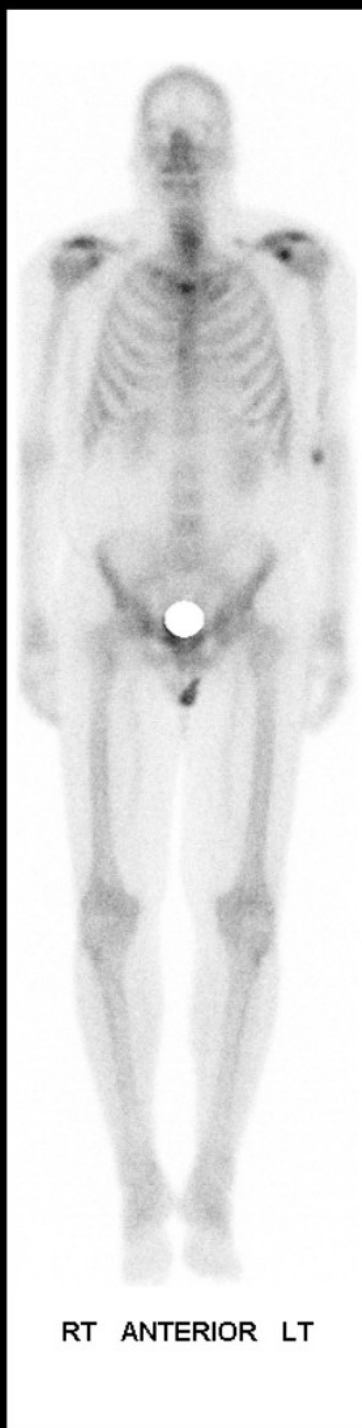SE:
2.500000 mr



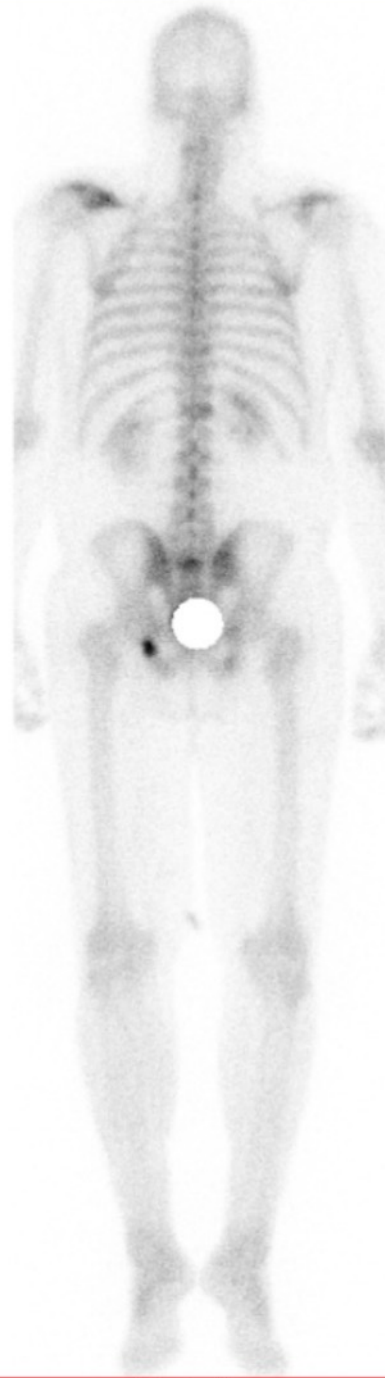
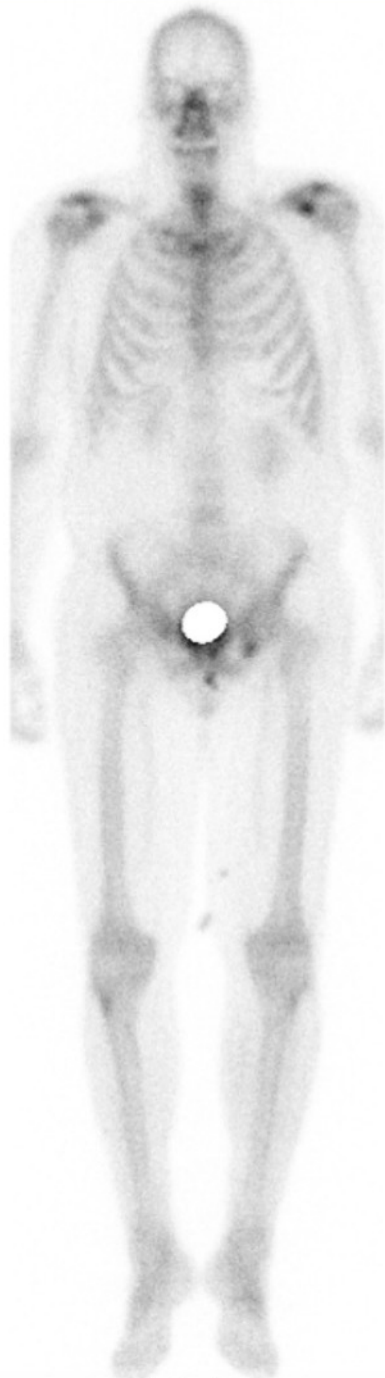




2018



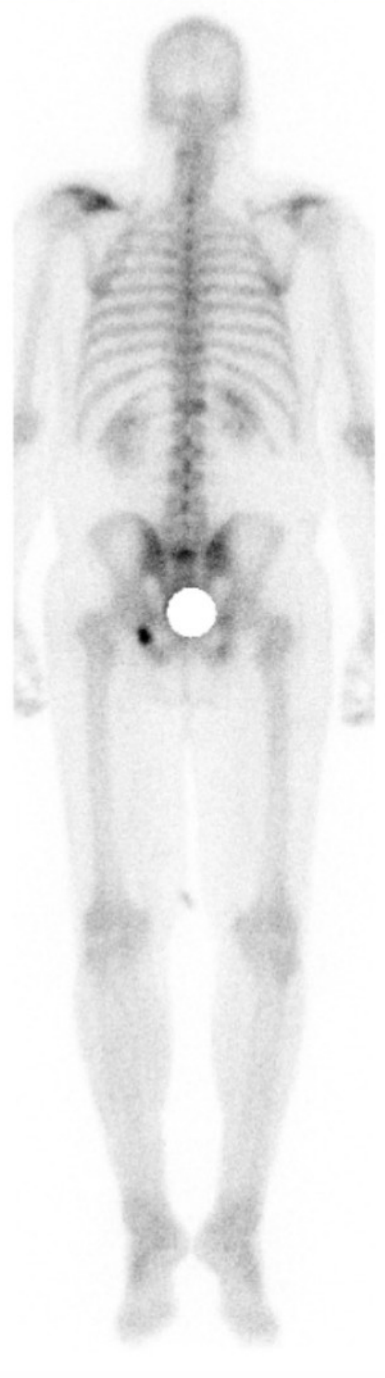
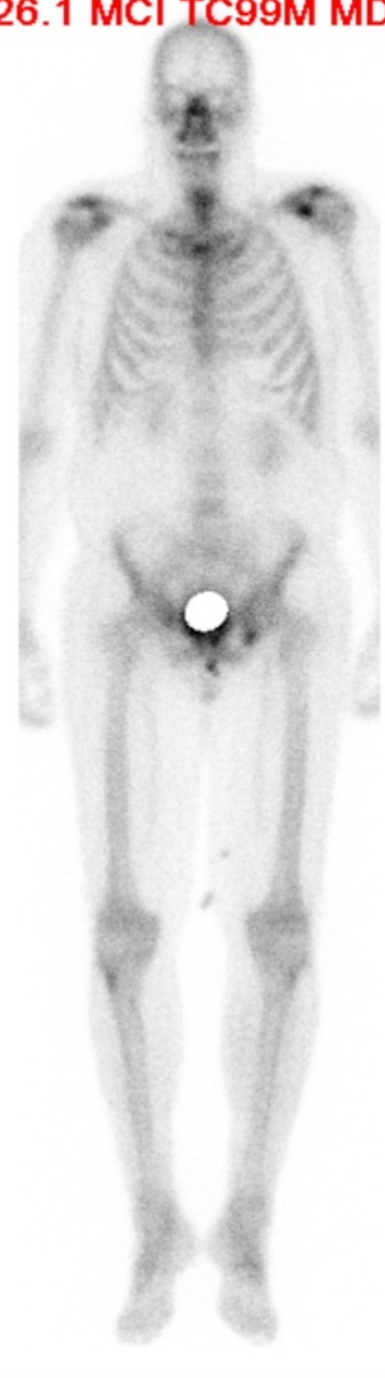
2019



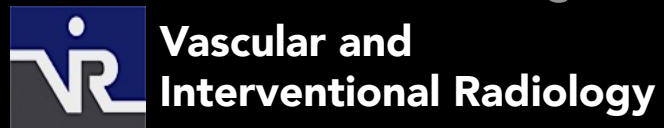
66

0

26.1 MCI TC99M MDP



George Behrens, MD
Interventional Radiologist



Extreme 10 cases