

# Tips and Tricks to Optimizing Outcomes Bland Embolization: My Top 5 Technical Pearls

(really, it works!)

Karen T Brown, MD, FSIR  
Professor of Radiology  
University of Utah  
Salt Lake City, Utah

Session 4  
Friday, October 22, 2021  
Miami Beach, FL

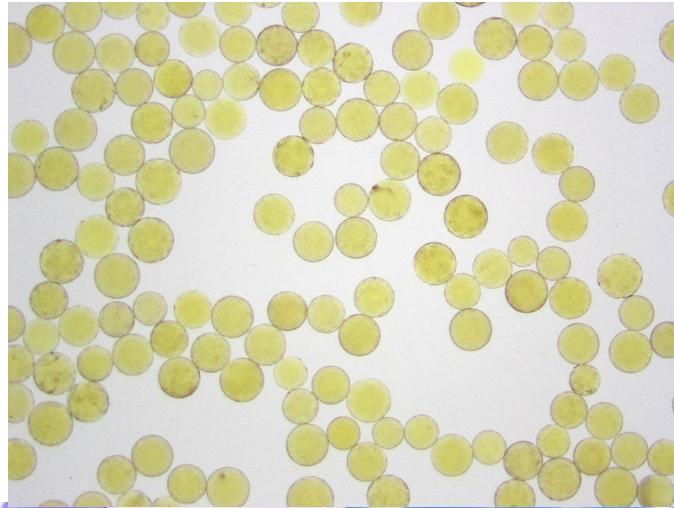
# Disclosures

**Karen Brown: Consultant — AstraZeneca**

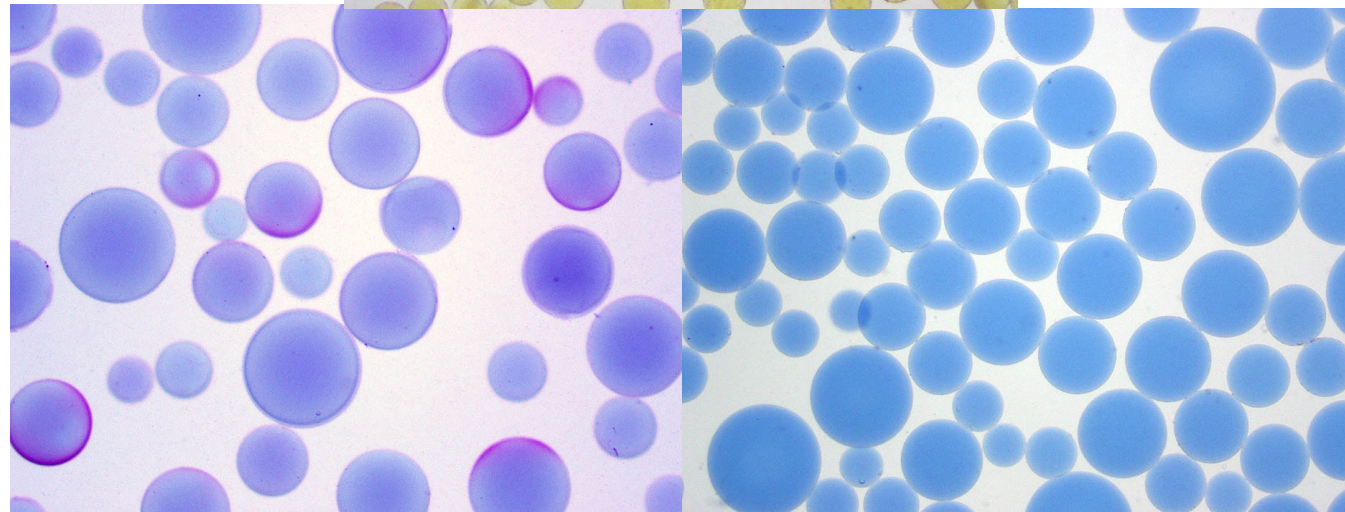
*Brand names are included in this presentation for participant clarification purposes only.  
No product promotion should be inferred.*

# “Know thy Embolics”

(This should probably be the first “pearl”)




Embozene™ 100 micron



Embospheres™ 100-300 micron    Bead Block™ 100-300 micron

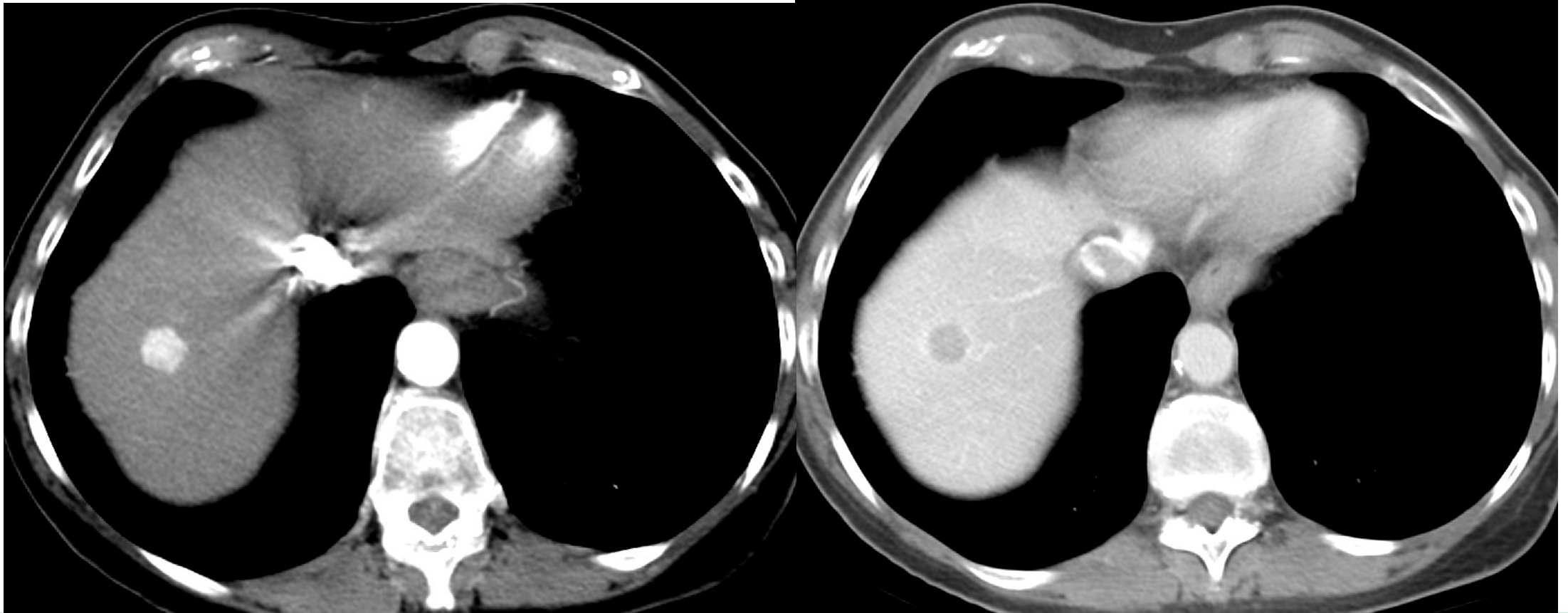
.....Very Different from PVA



# Pre-Treatment CT 1.31.16

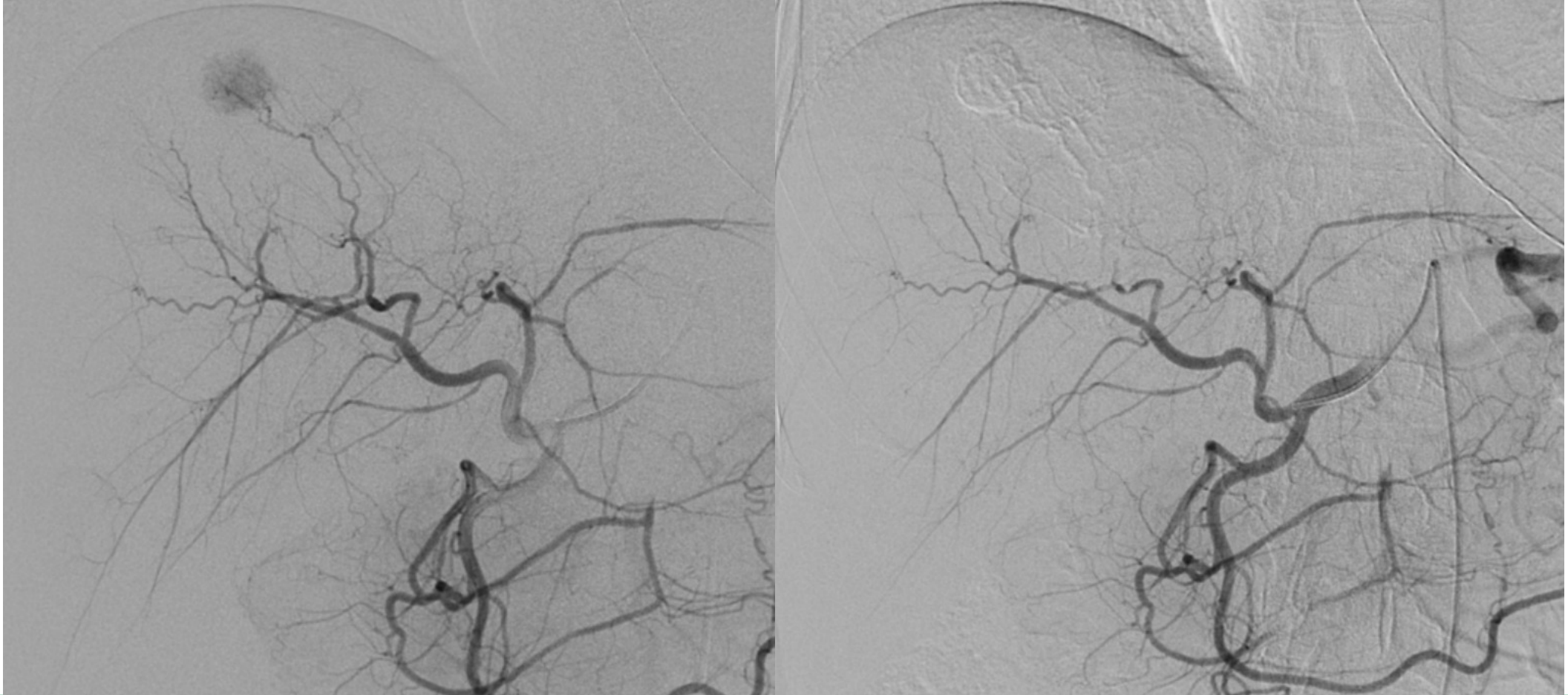
Arterial phase

Portal venous phase



# Embolization 2.9.16, Used 0.5cc 40 $\mu$ Embozene

**#1: Anesthesia!!**

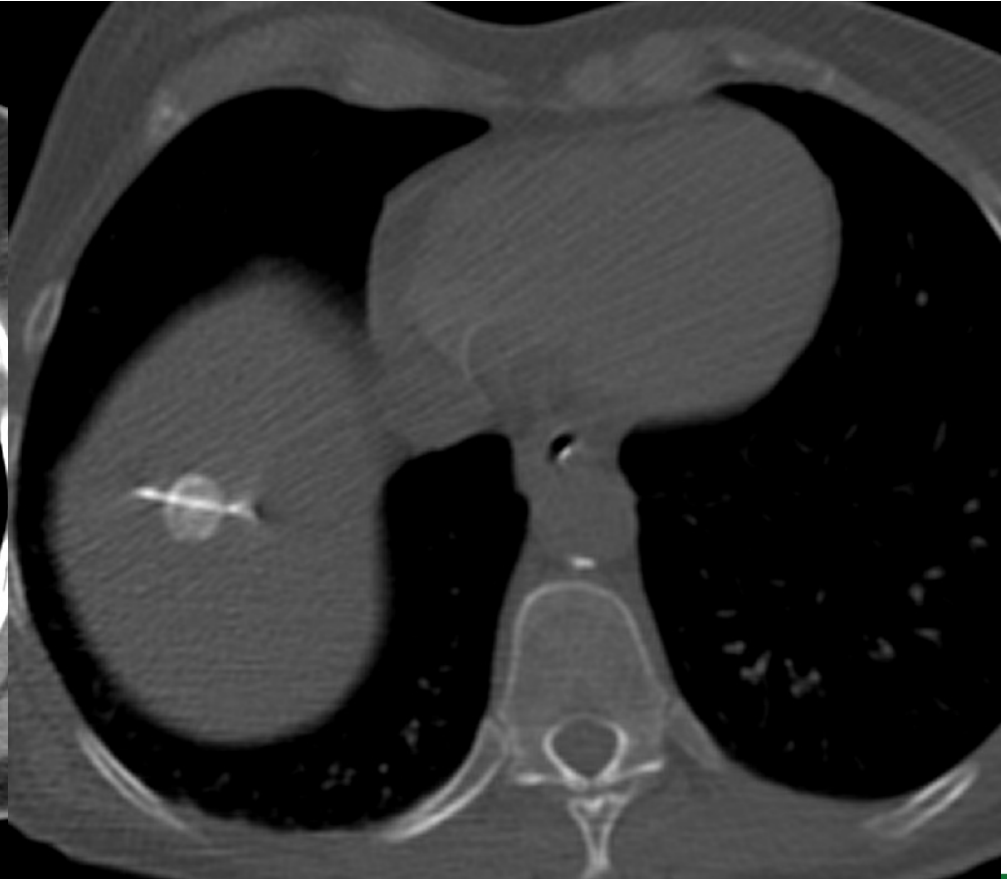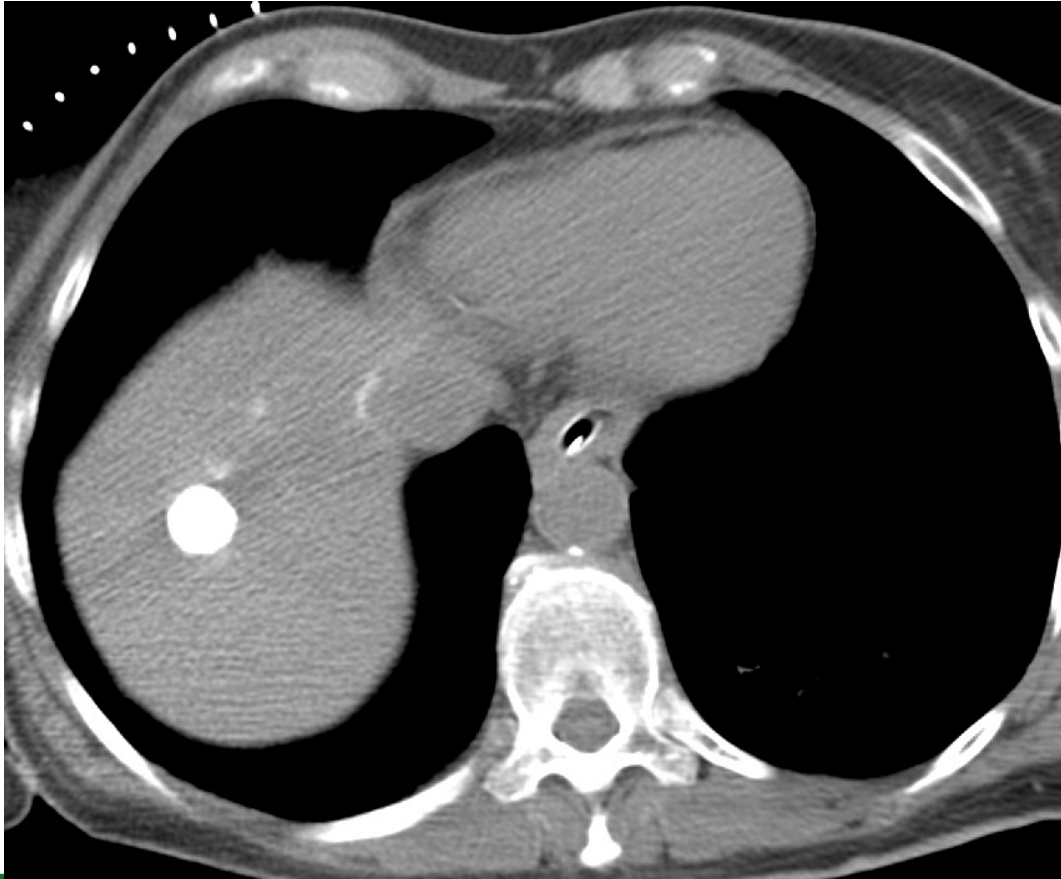


# Immediate Post-Embolization CT and Biopsy 2.9.16

**#2: You can see what you bland embolize!!**

CT with marker grid

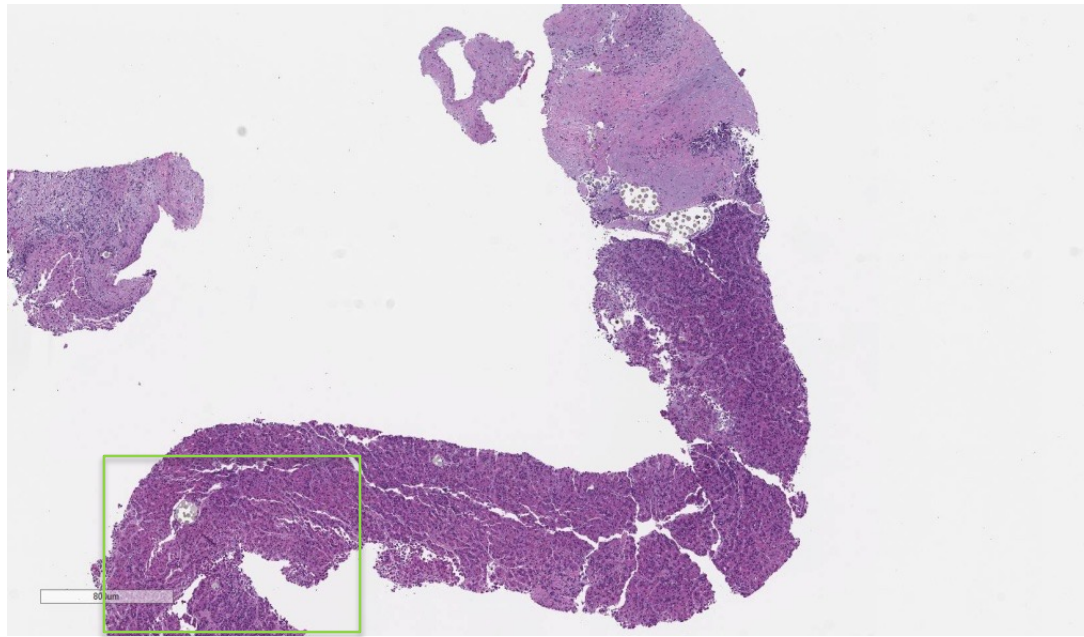
Biopsy



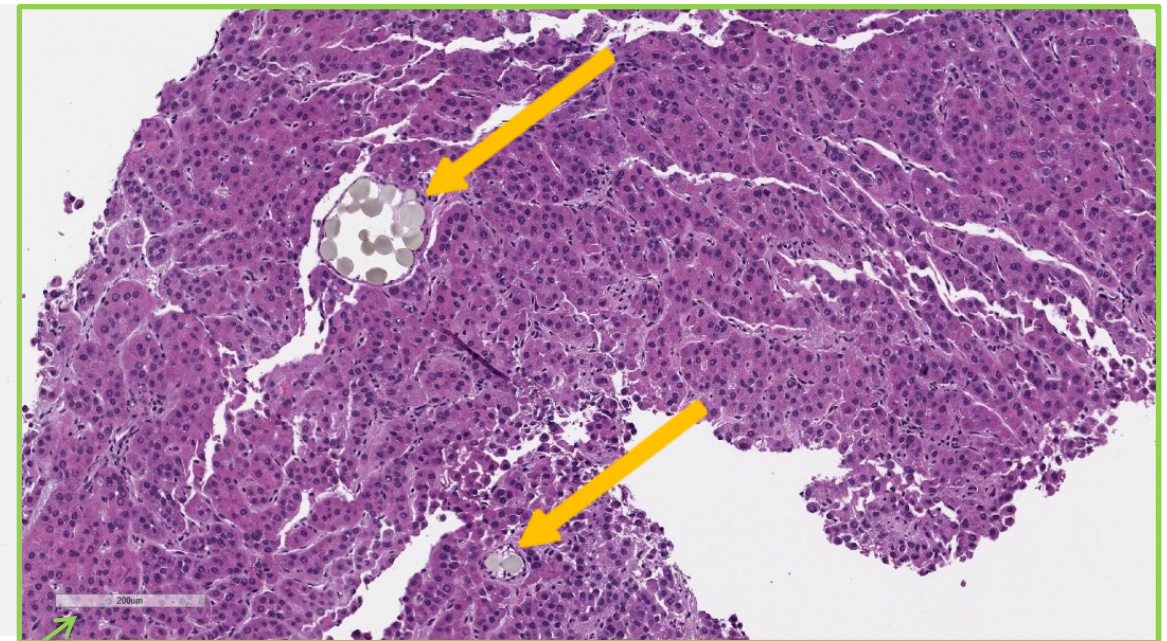
# Histopathology from the Biopsy

## #3: Biopsy OK after embolization

Low power



High power

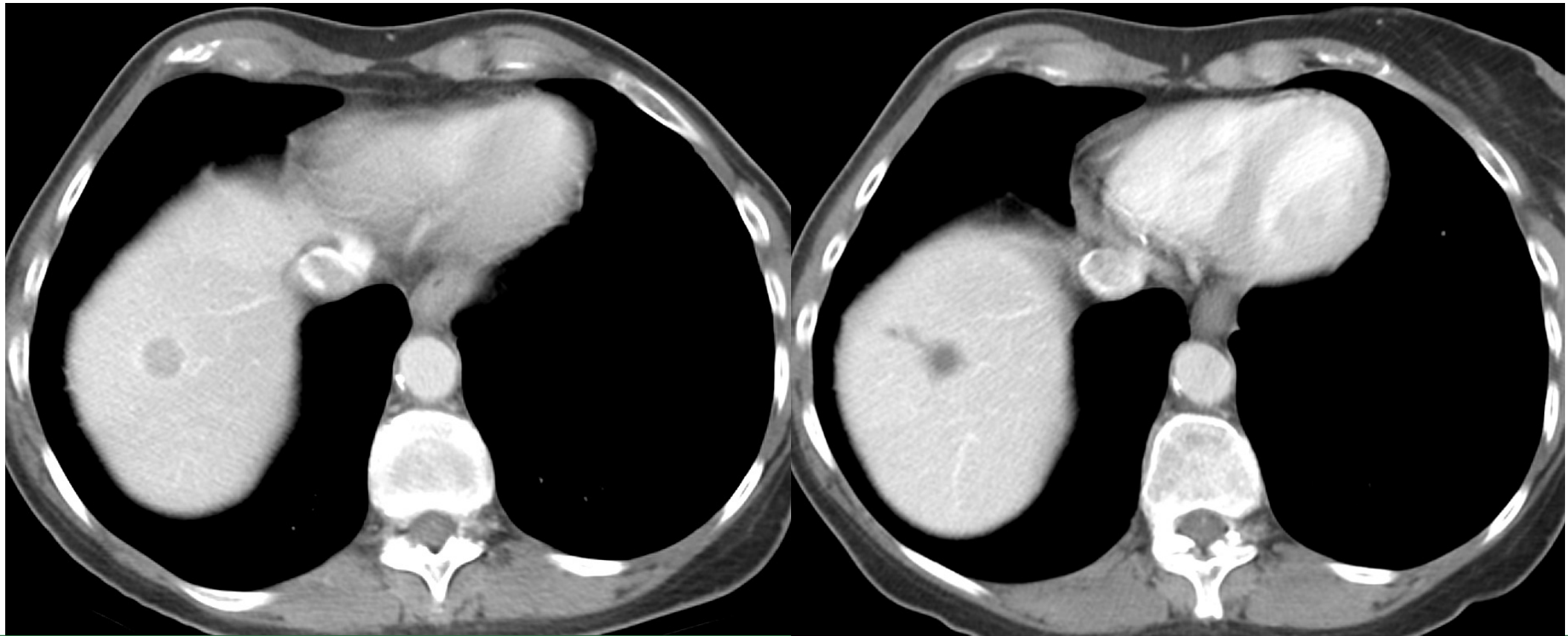


200 micron scale

# Pre-Treatment and One Month Post Treatment CT Portal Venous Phase Scans

1.31.16

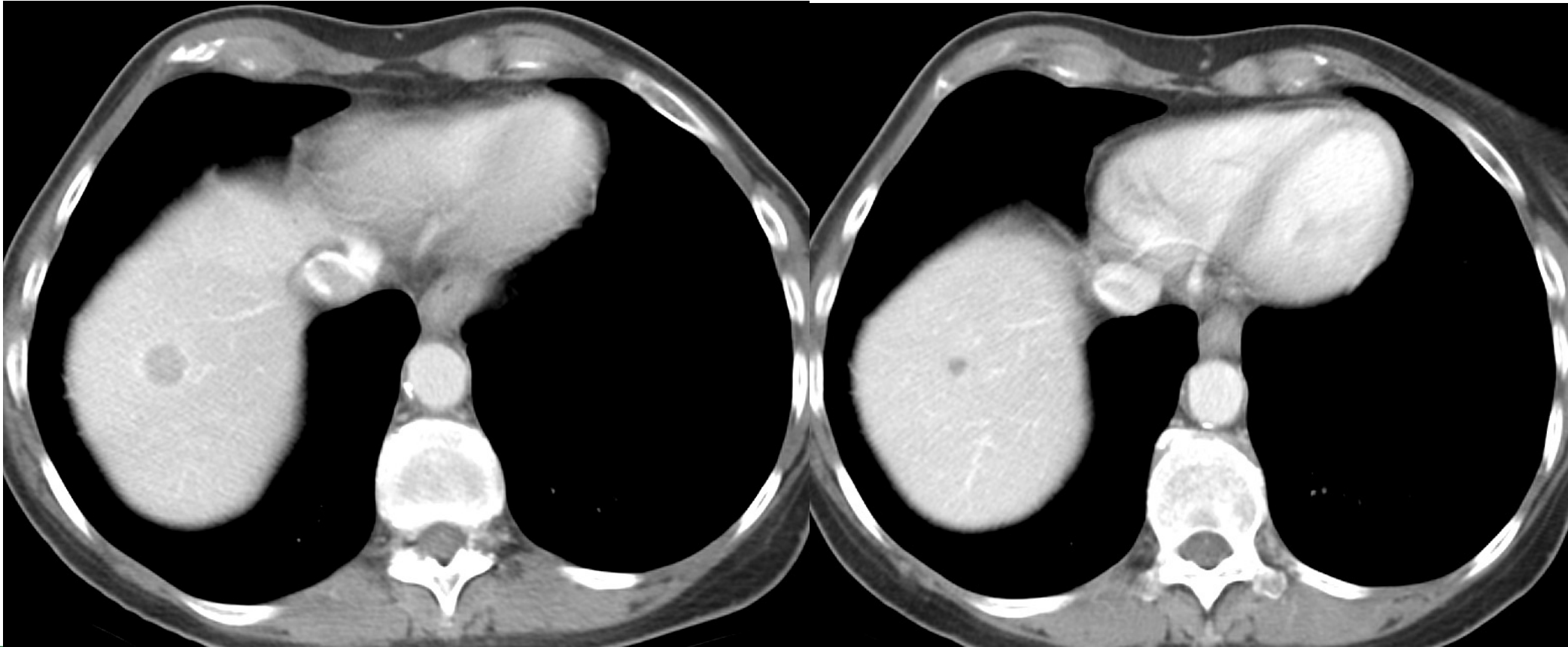
3.11.16



# Pre-Treatment and 8 Months Post Treatment CT Portal Venous Phase Scans

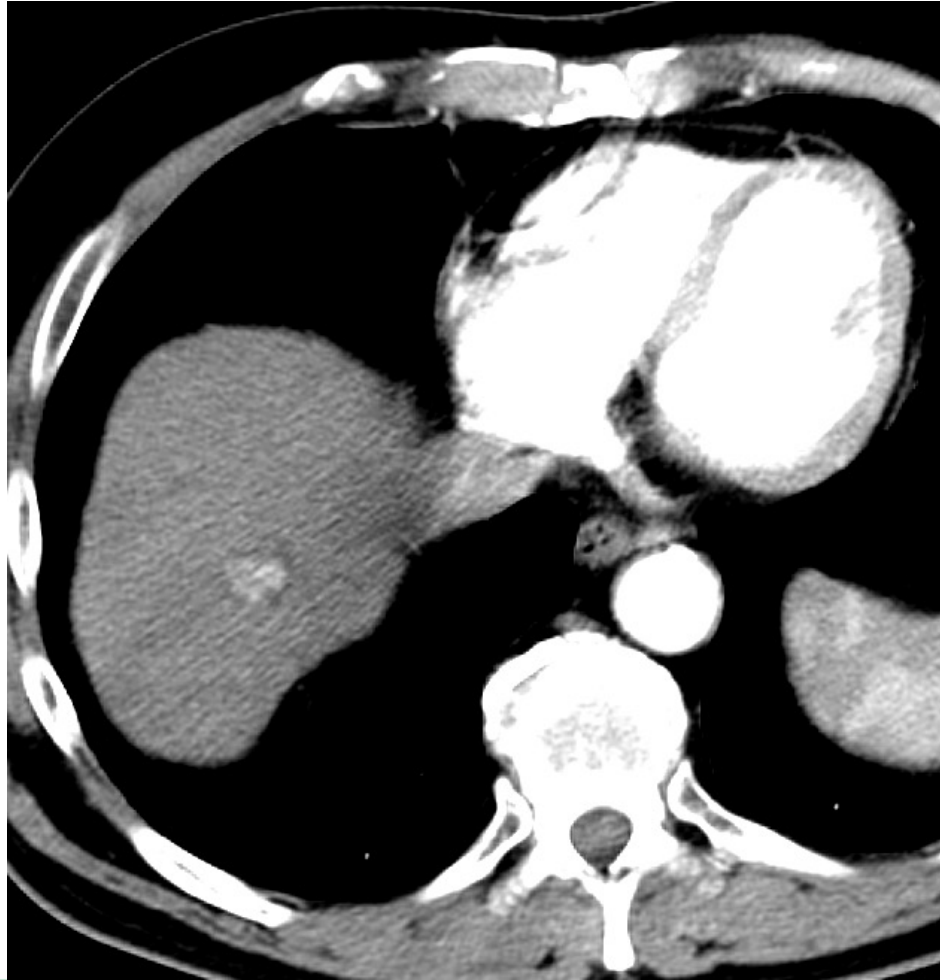
1.31.16

9.23.16

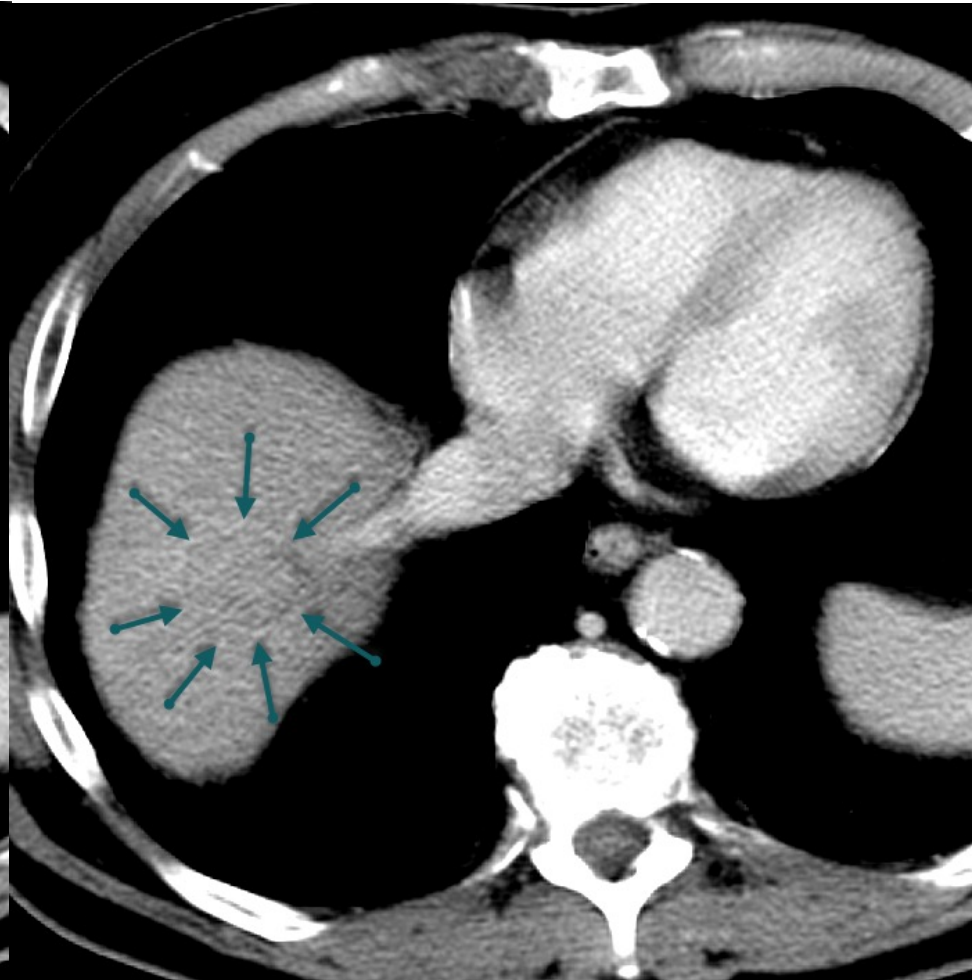


# Pre-Treatment CT 12.22.16

Arterial phase

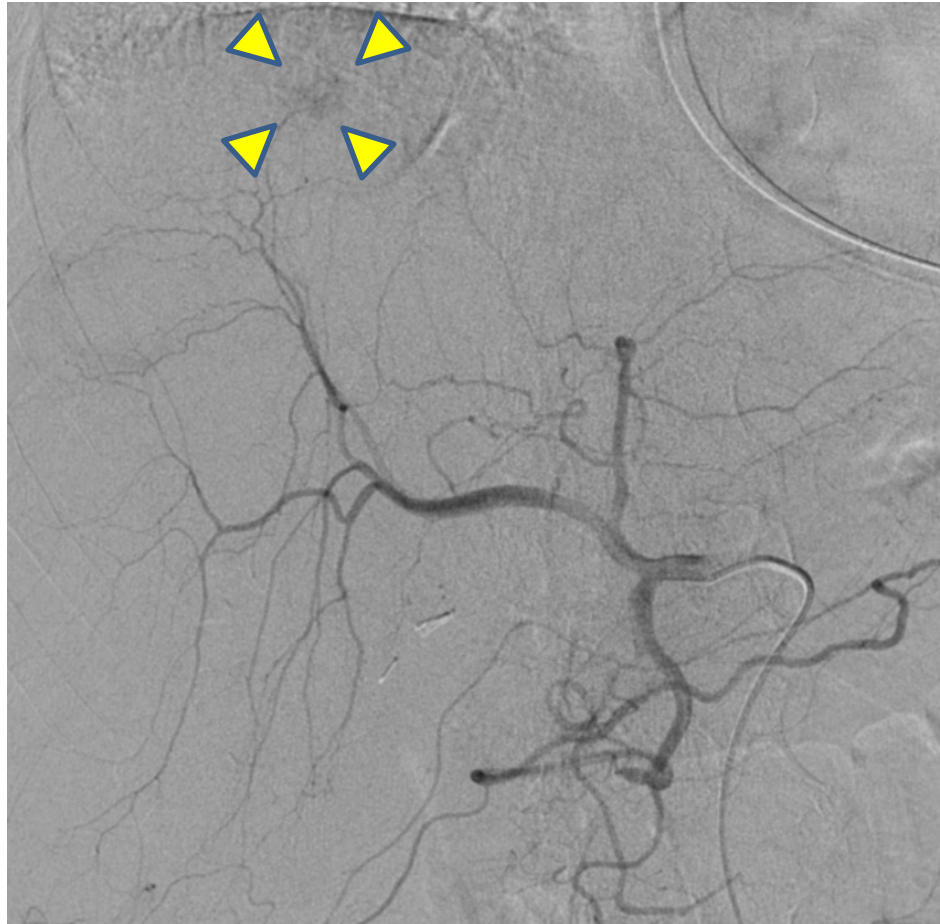


Portal venous phase

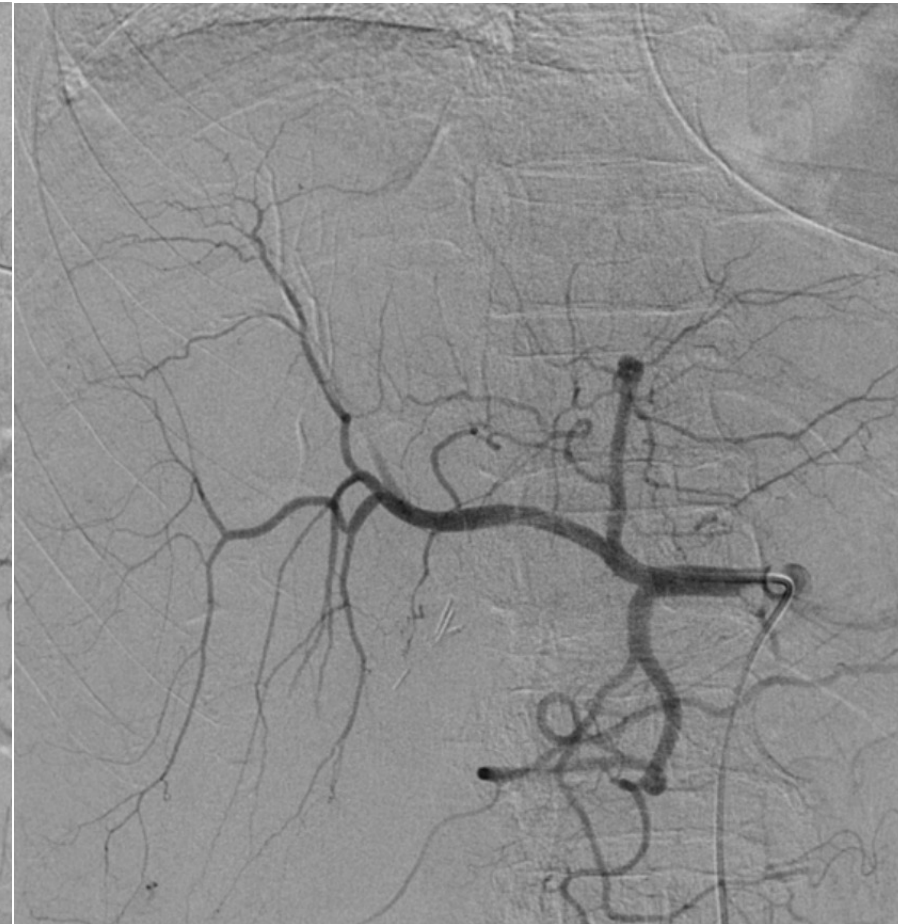

# CHA Angiography 1.17.17

**Pre-embolization**



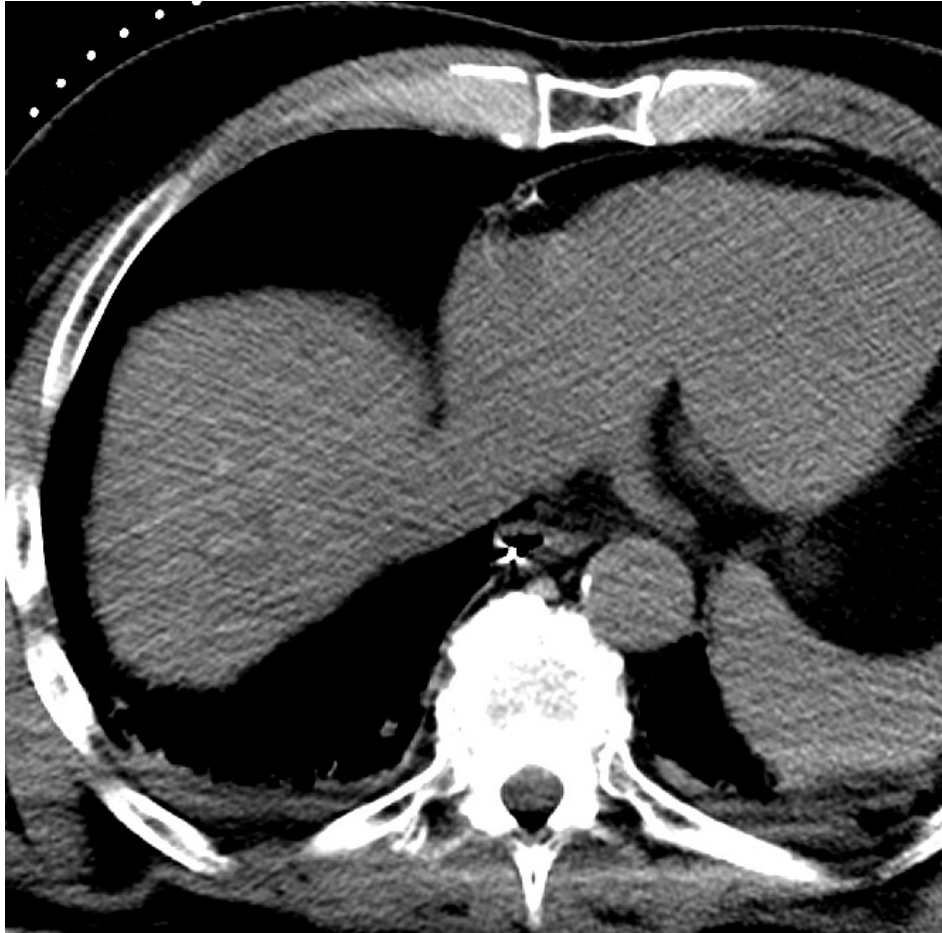
**Post-embolization**



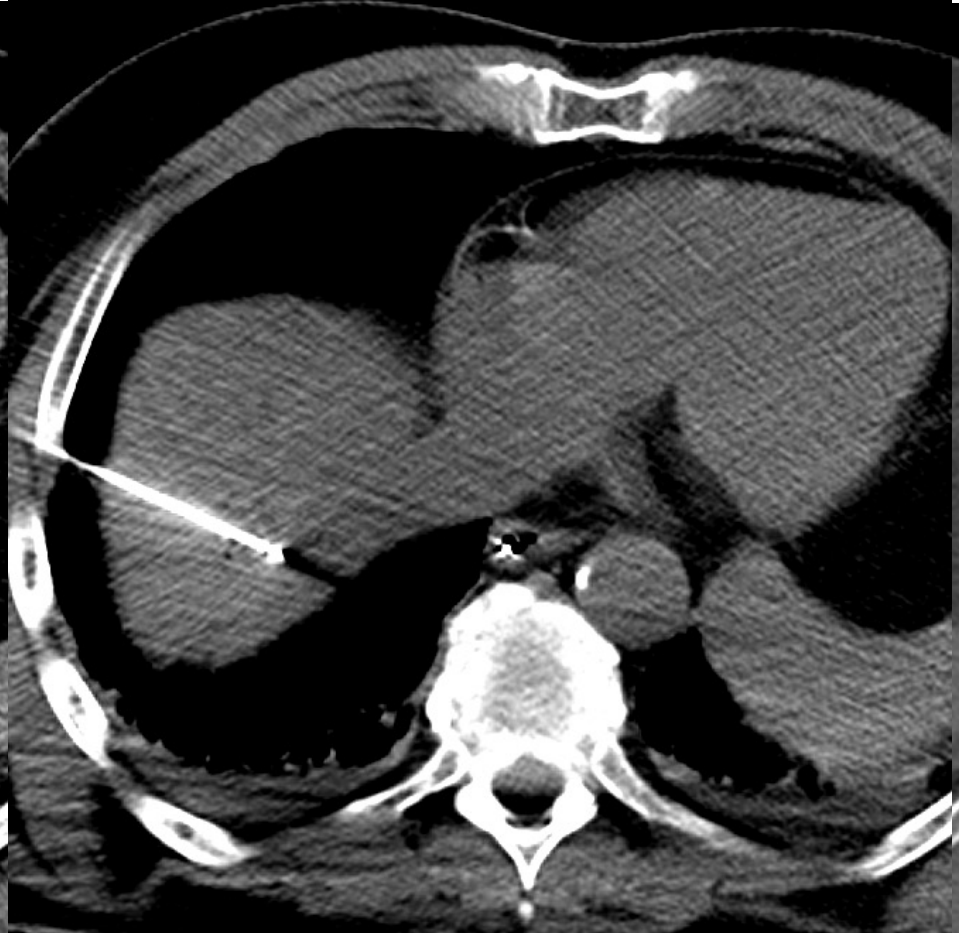# Post-embolization Biopsy & Ablation 1.17.17

## #4: Embo + Ablation

Immediate CT



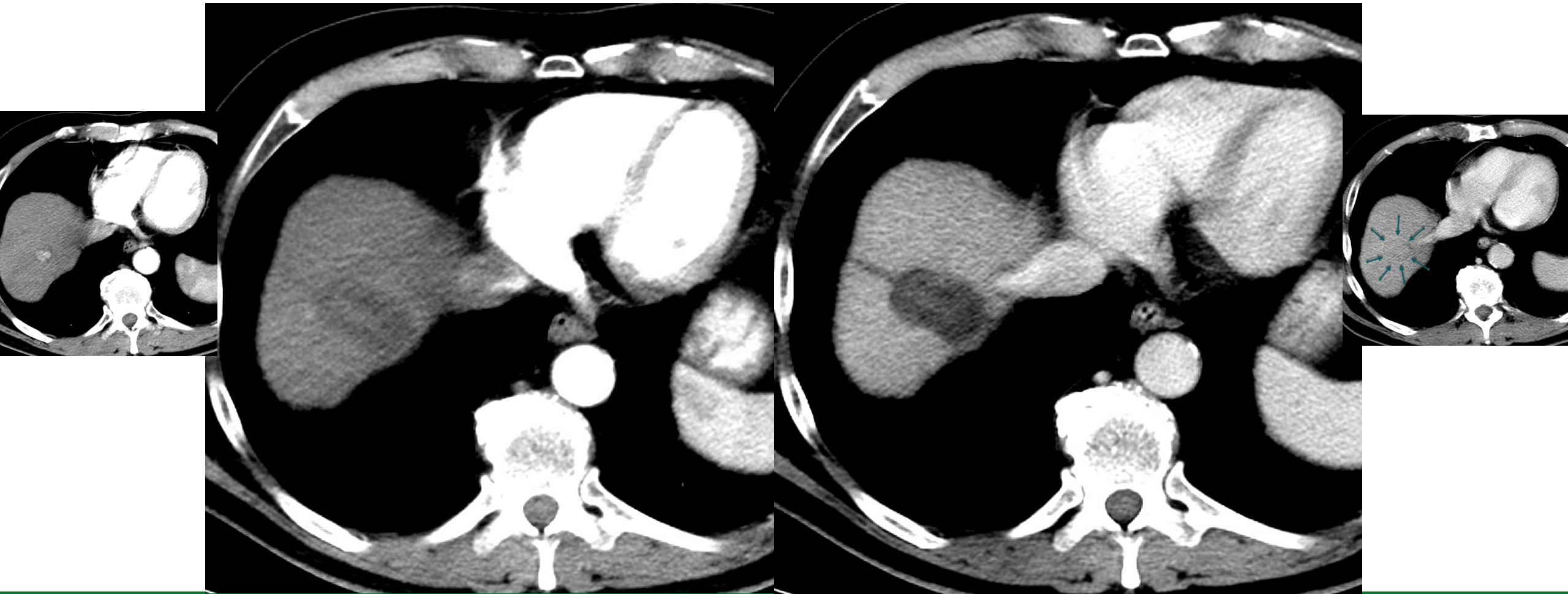
Ablation



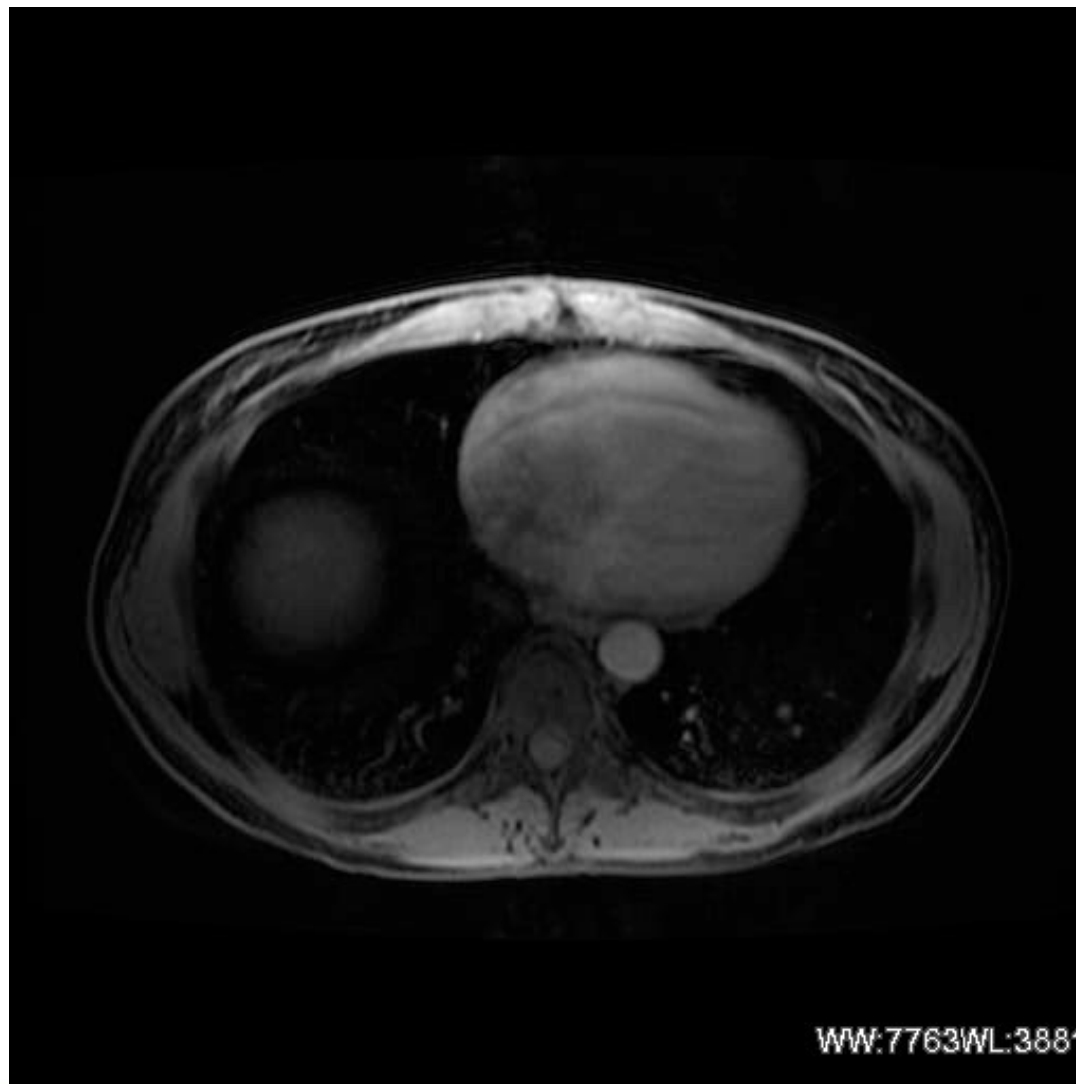# Multiphase CT 1 Week After Treatment 1.24.17

Arterial phase

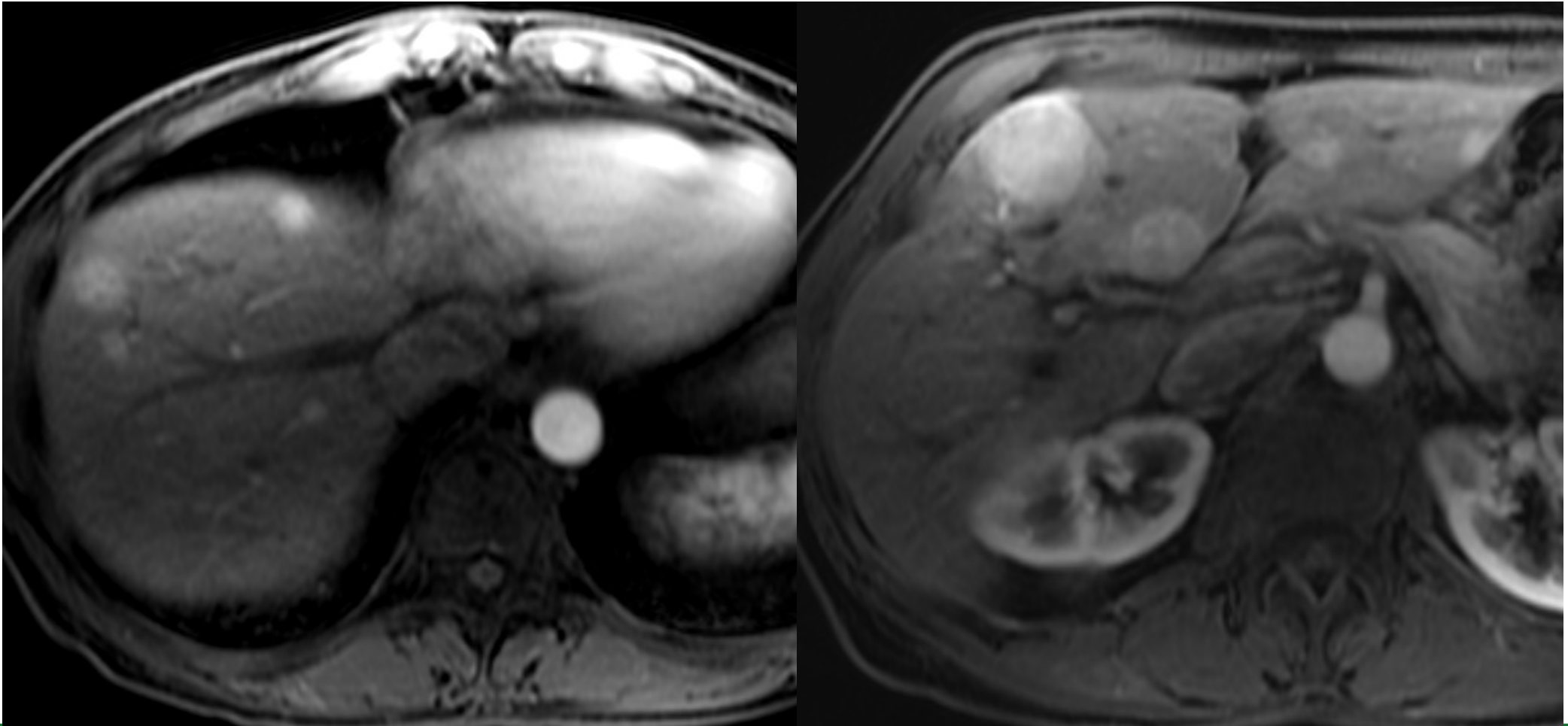
Portal venous phase



MR 10.18.2016

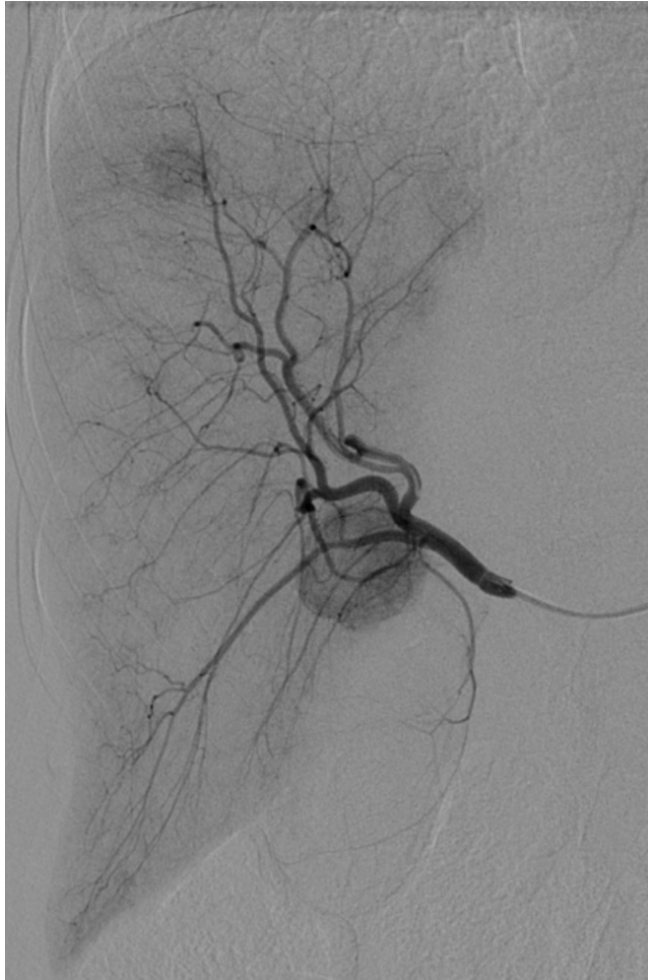

# Pre-Treatment MR 10.18.16

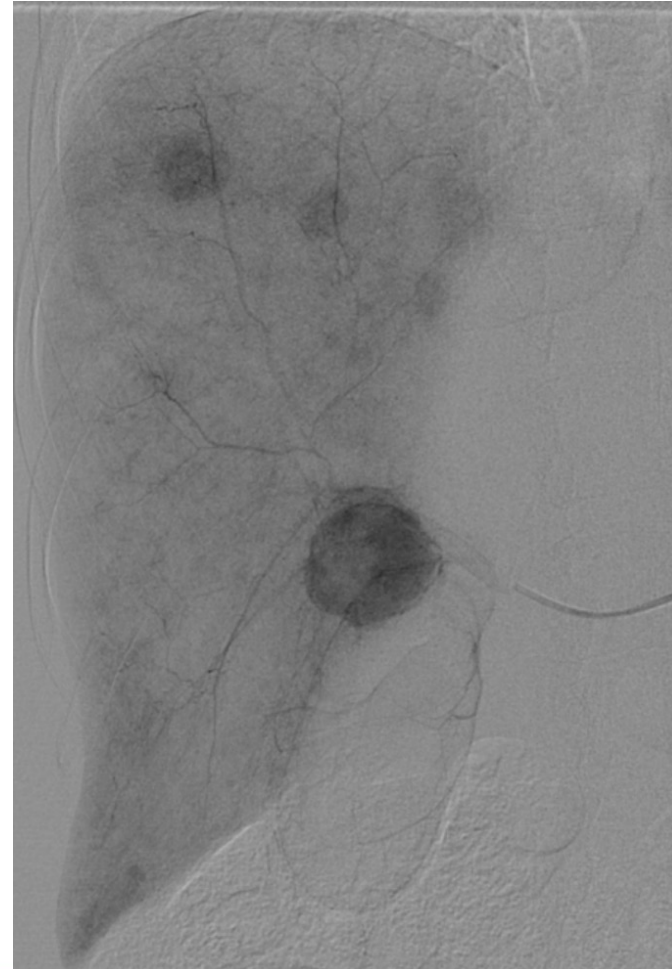


# Right Hepatic Angiogram 1.23.17

**Early arterial**

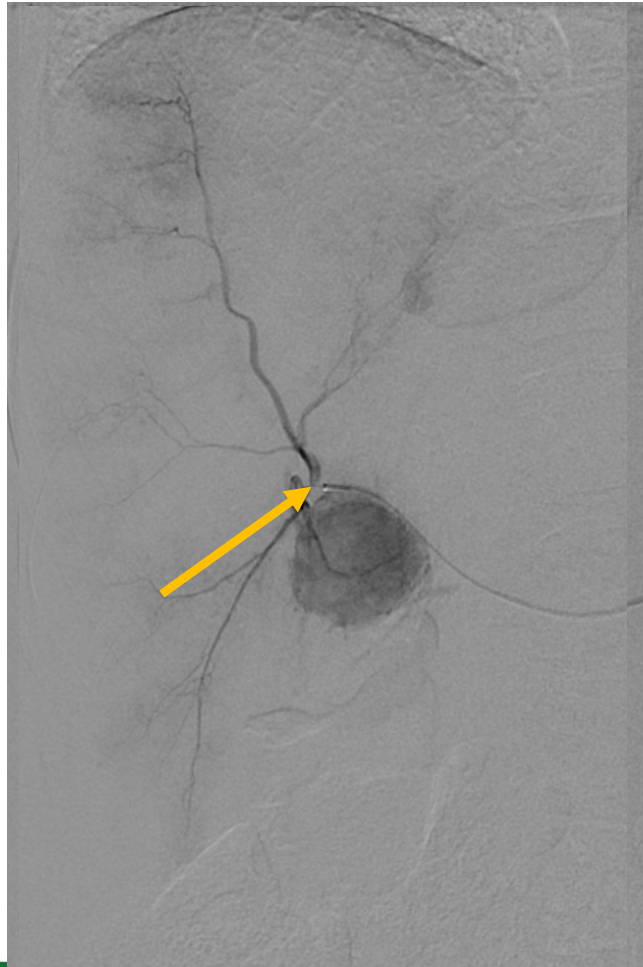


**Parenchymal phase**

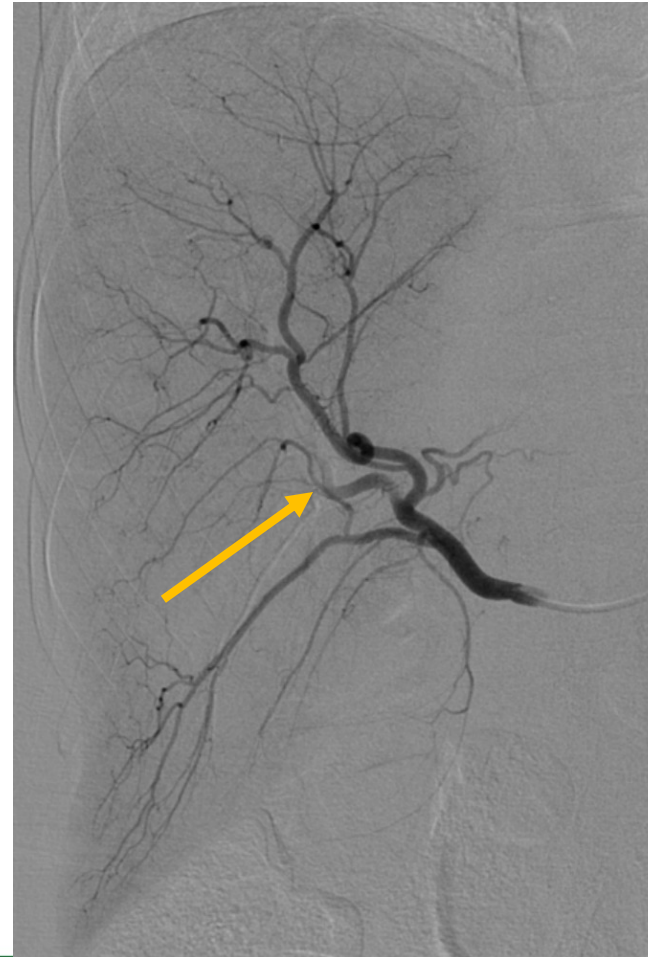

# RHA Angiography Pre/Post Embolization 1.23.17

Pre-embolization anterior RHA



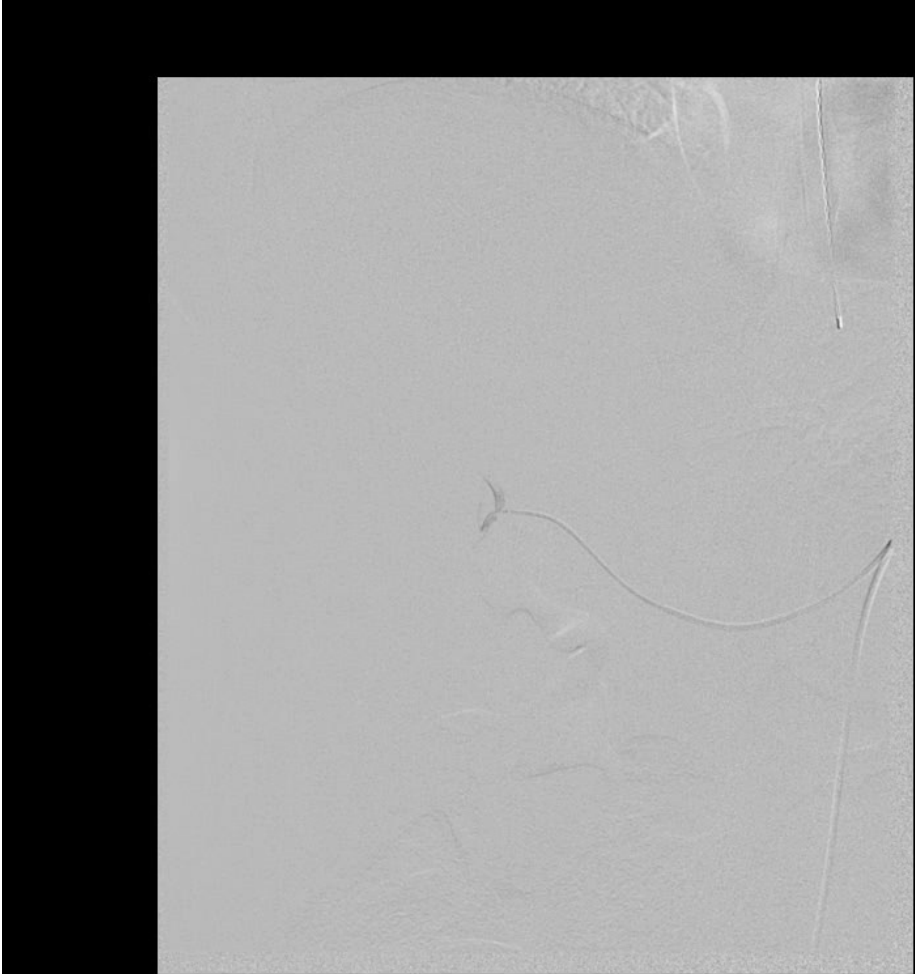
Post-embolization anterior RHA



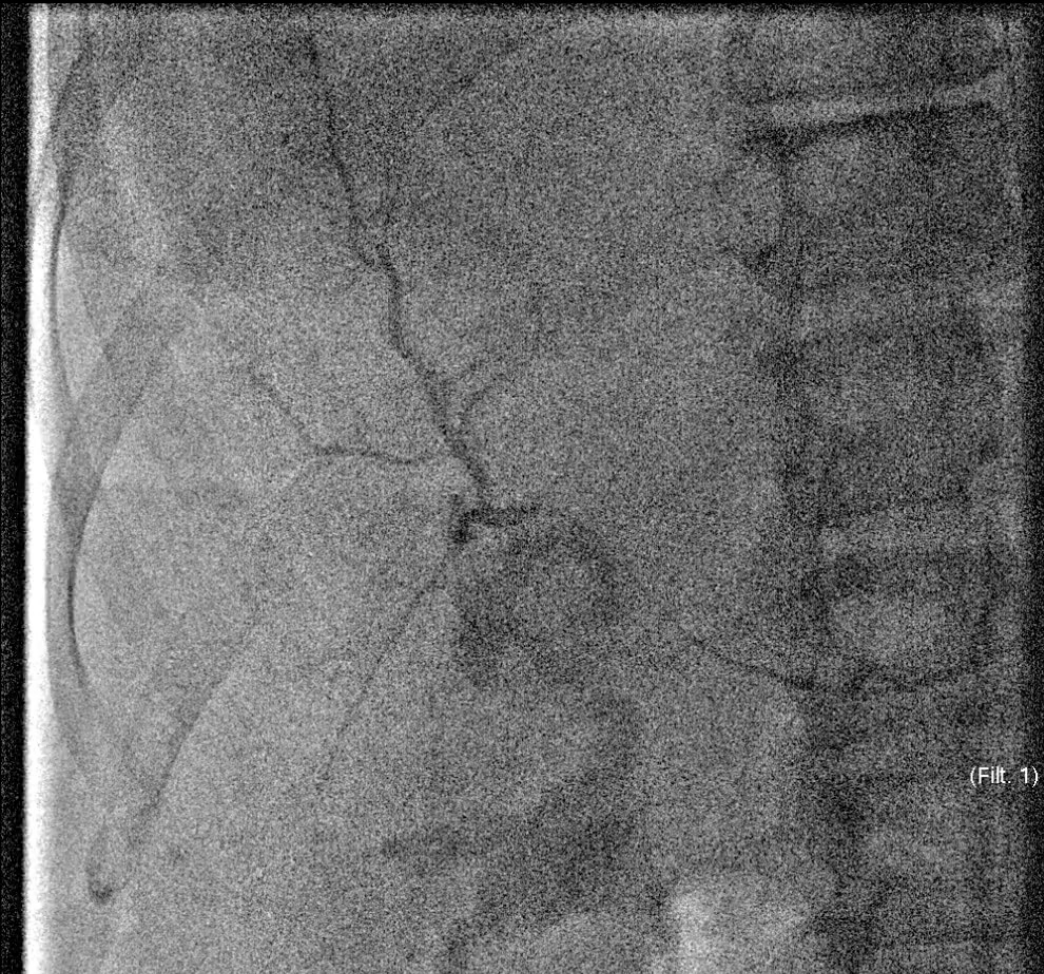
Used 1cc 75 micron  
Embozene

# #5: Patience & Stasis

## Embolize to Stasis



WW: 4096WL: 2048

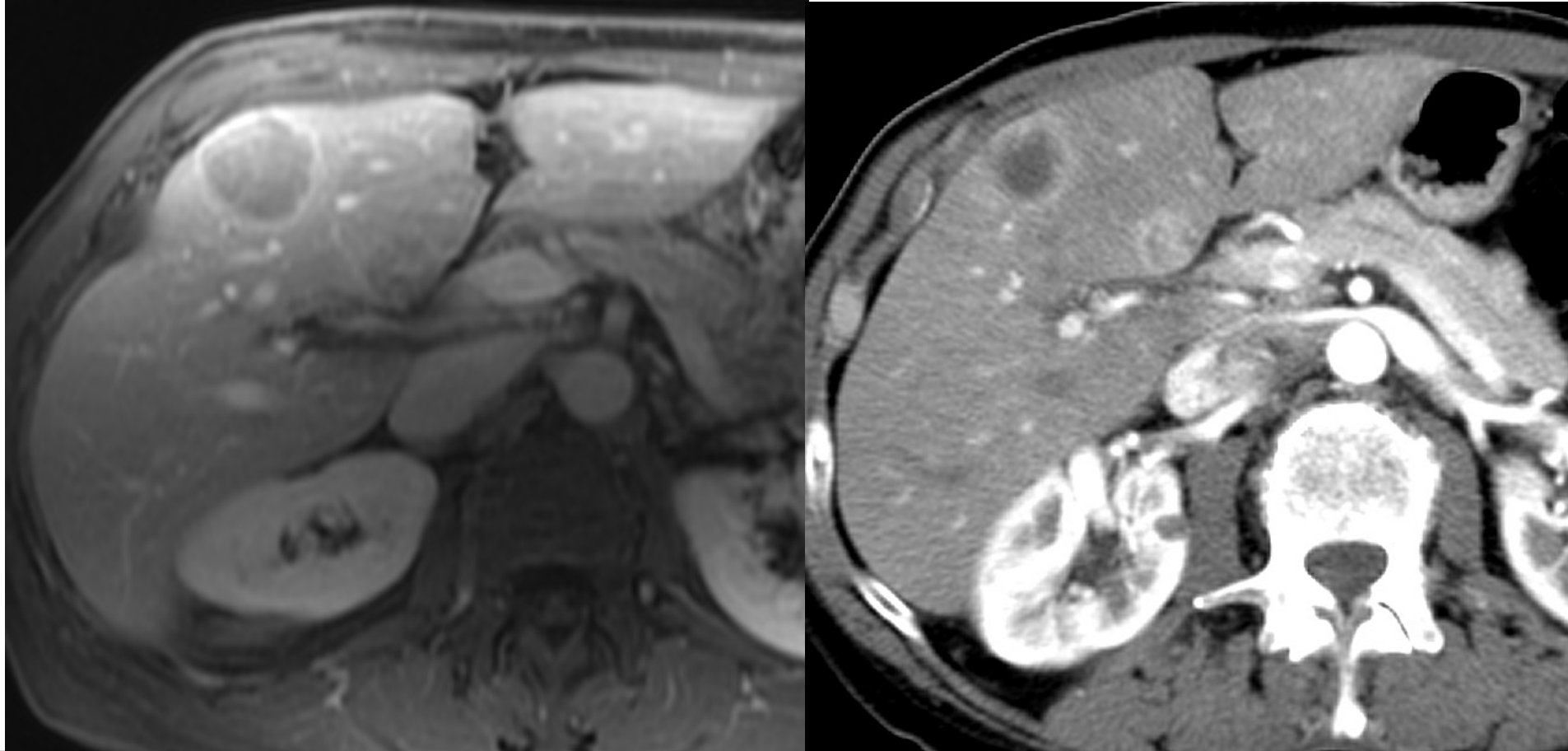


WW: 256WL: 128

# CT 1 Month After Embolization

MR 10.18.2016

CT 2.24.2017



# Take-Home Points

- Anesthesia
- Size particles for tumor
- Immediate post-embo CT
- Biopsy OK after embo
- Stasis/patience
- Ablation + Embo
- Dronabinol pre
- General anesthesia
- Steroids, ketorolac
- Dronabinol, ketorolac post-embolization

*Thanks!*

