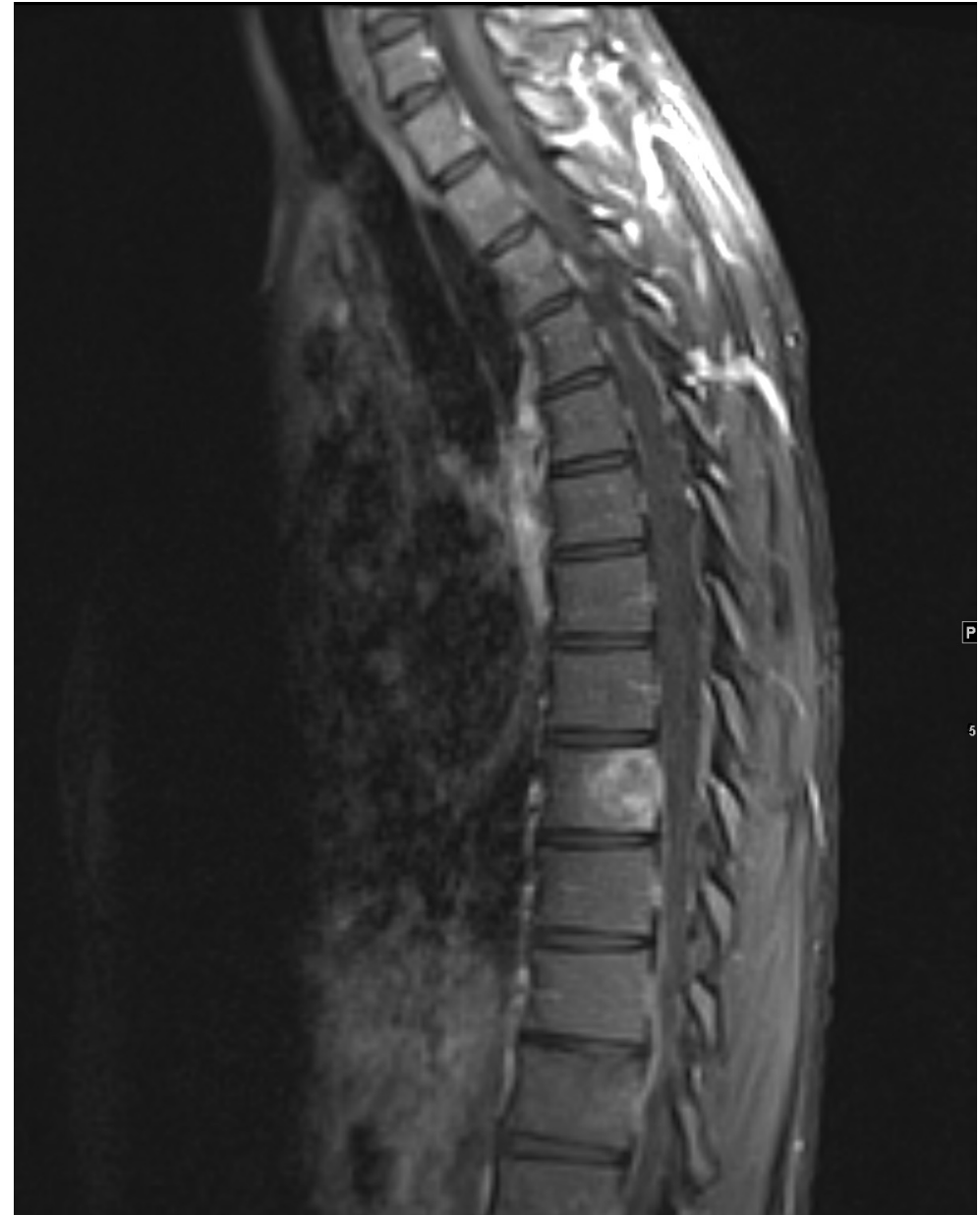

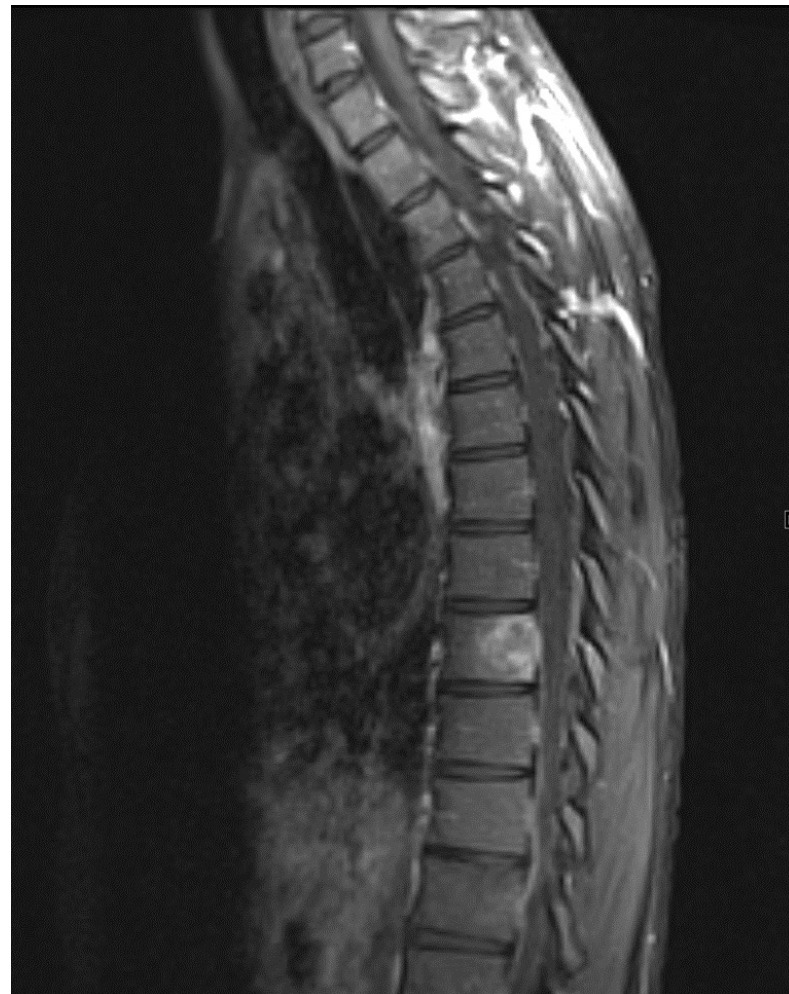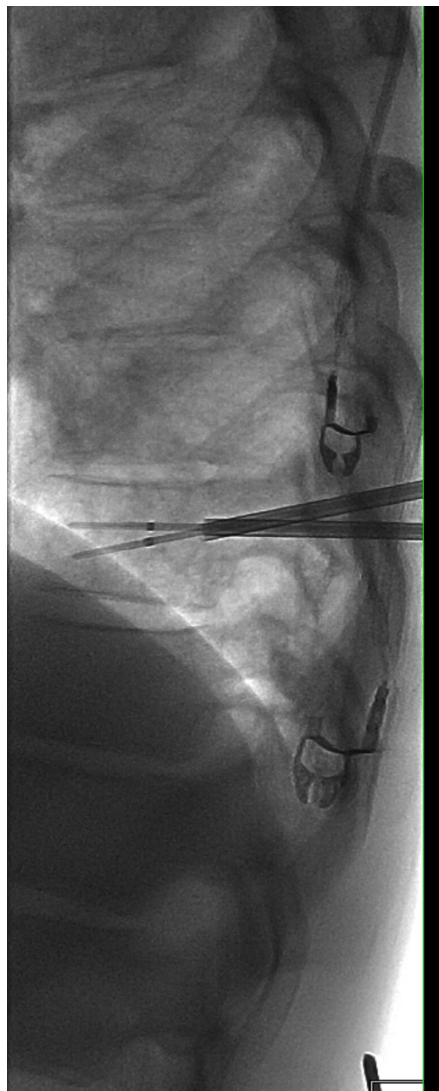
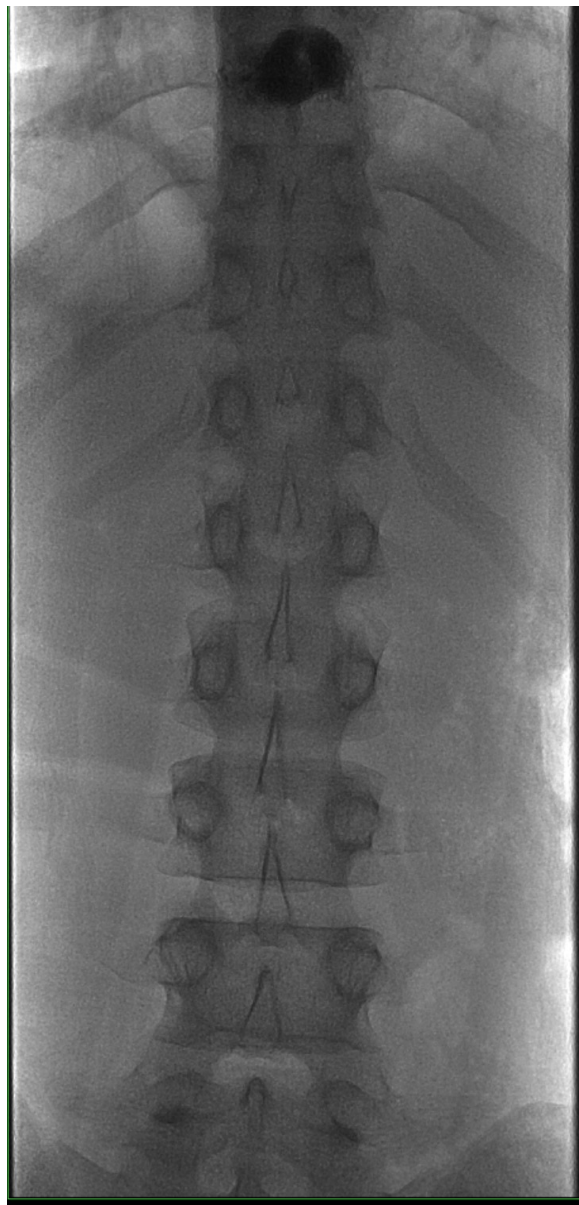
Case

J. David Prologo, MD, FSIR, ABOM-D
Emory IR

Disclosures

38-year-old male
with history of
Non-Hodgkin's
Lymphoma, pain
in mid-thoracic
region, and new
finding at T9

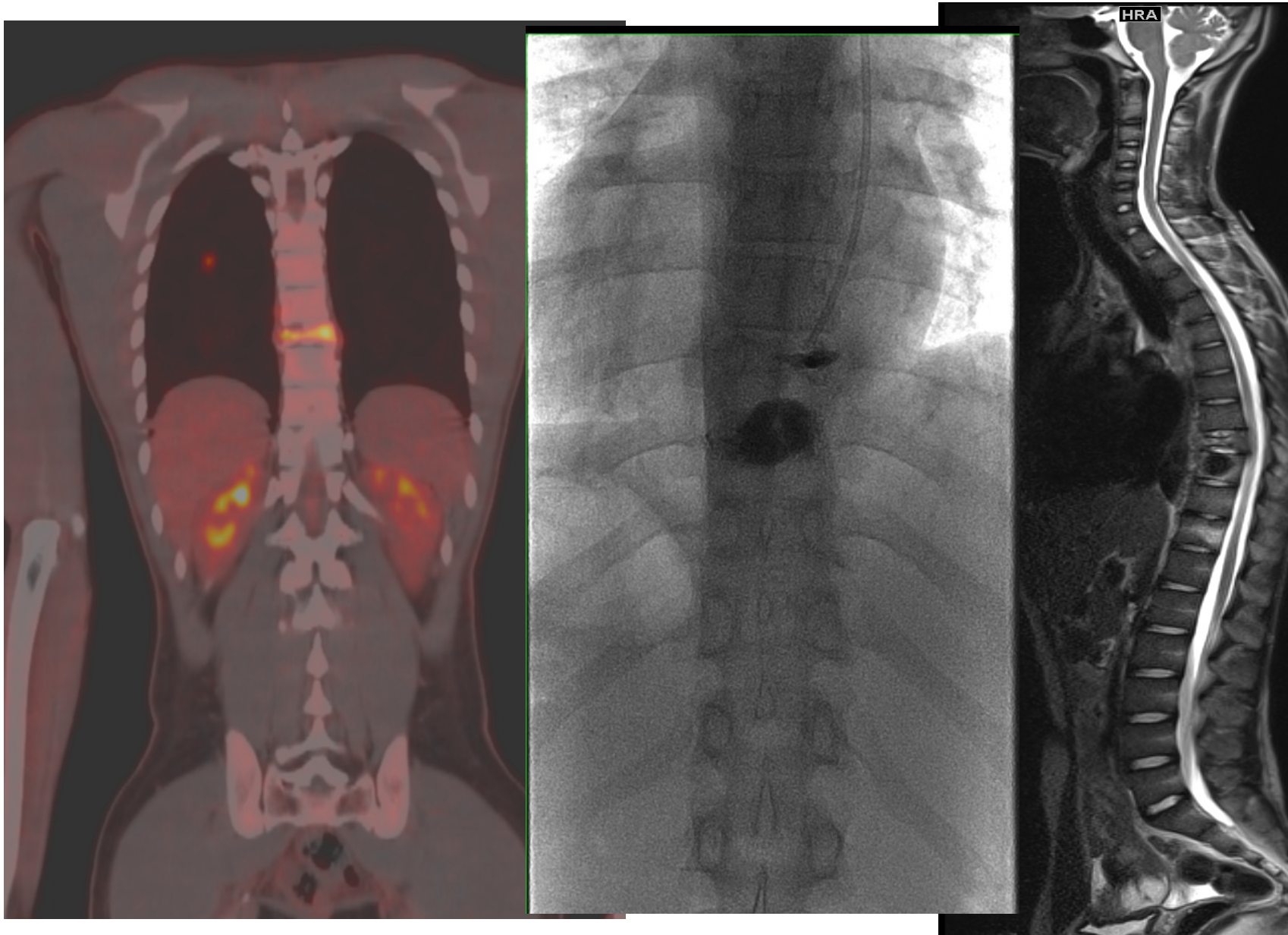




7-day follow-up

Not feeling much better

Follow-up PET describes
cement at level below
lesion



Take-Home Points

- Be very careful when no vertebral body deformation
- Never trust the ribs
- Have pre-procedure imaging that correlates with how you intend to count during the case

Questions?

