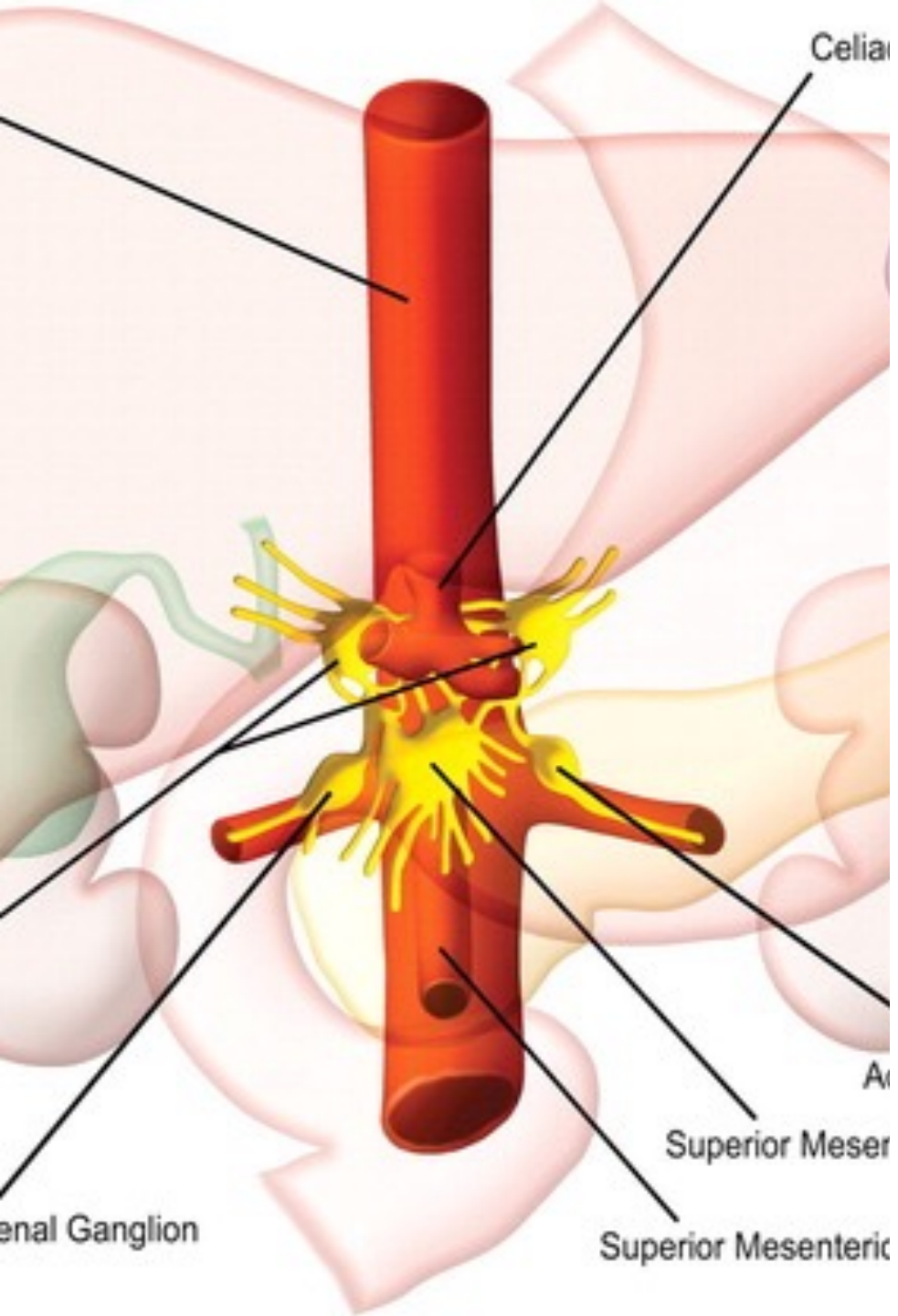


# Celiac Plexus Block and Cryoablation

J. David Prologo, MD, FSIR, ABOM-D  
Emory IR

# Disclosures

- Chief Medical Officer — Focused Cryo, Inc.



# Physiology

Reproducible pain score decreases and opioid requirements at 4 weeks and 8 weeks

Positive trends at 3 months and 6 months\*

\* Majority of studies are neoplasm, primarily pancreatic

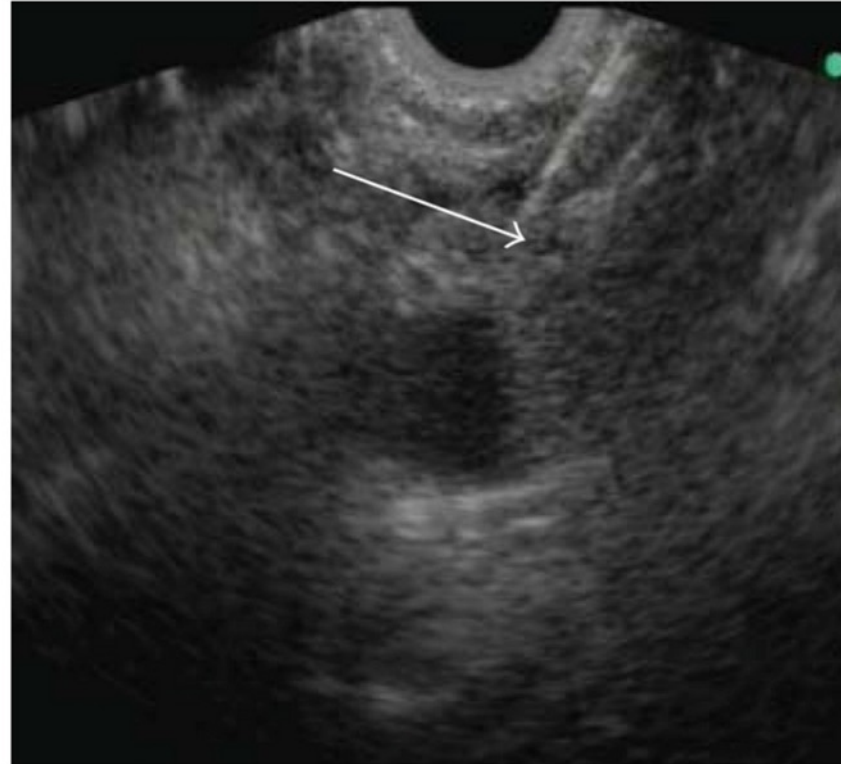
Kambadakone A. Published Online: October 04, 2011

<https://doi.org/10.1148/rq.316115526>

kambadakone A, et al. *Radiographics*. 2011;31(6):1599-621.

# Evolution of Approach

A single  
needle  
and c  
aspirate  
plexus  
about  
advar  
level  
exten  
\*Merc

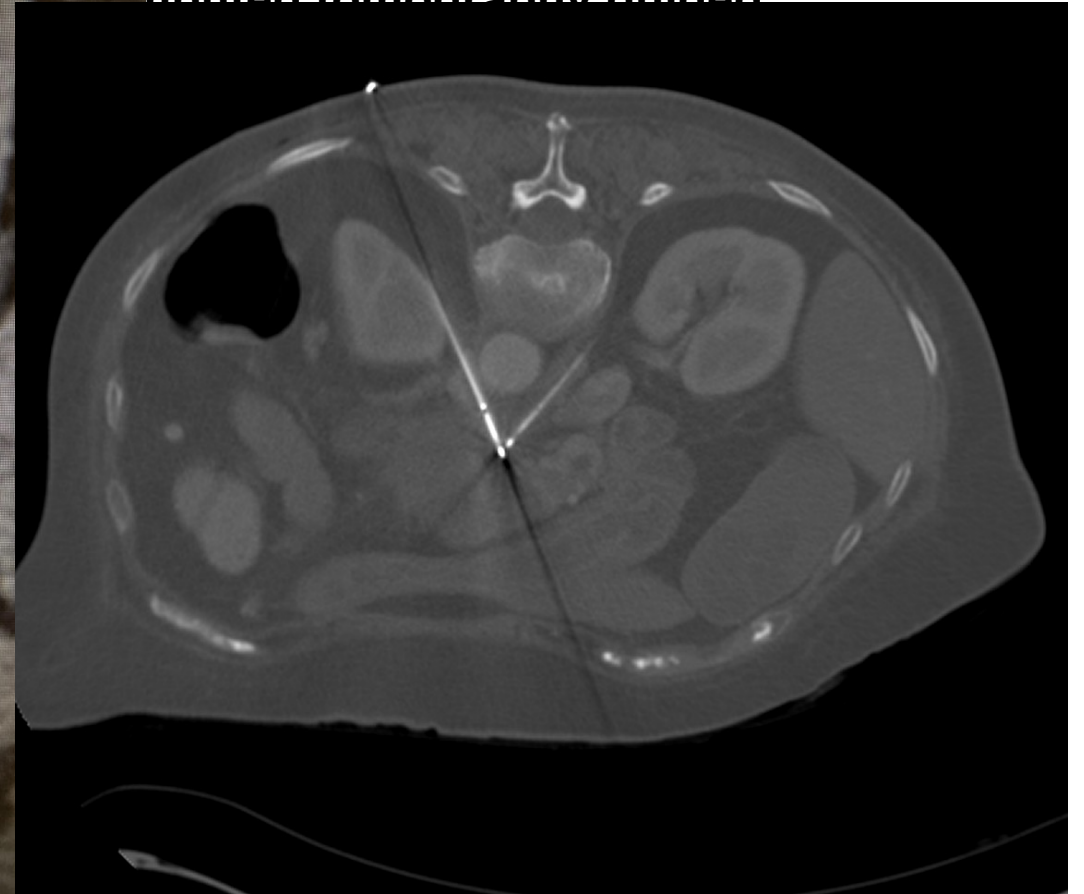
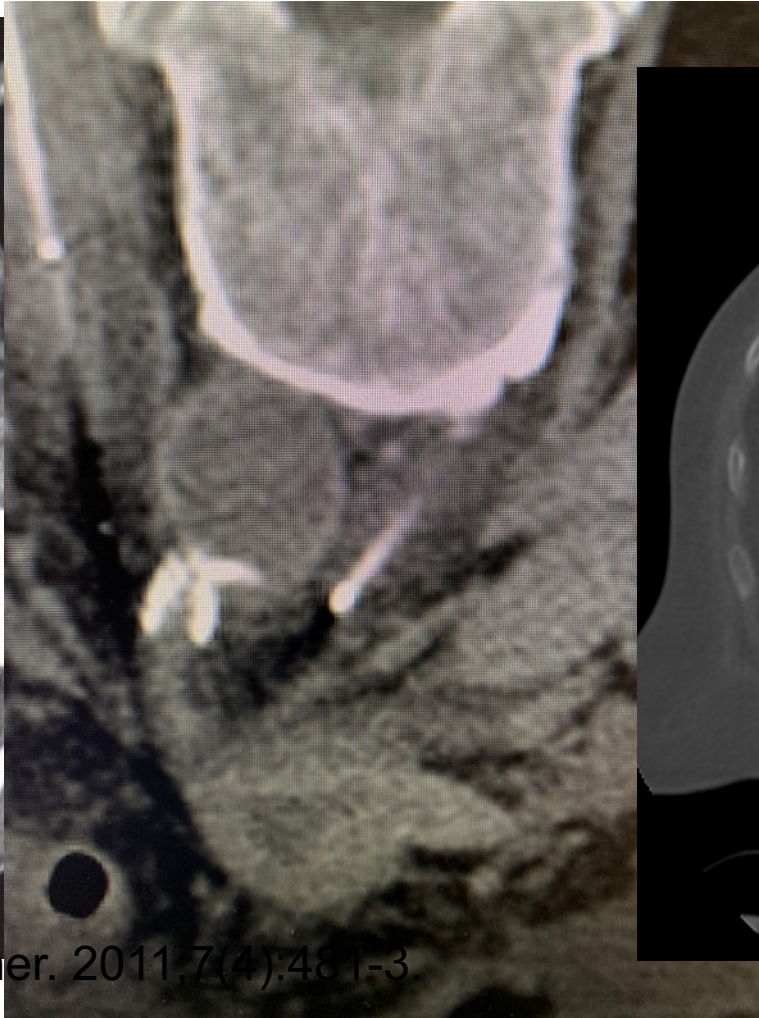
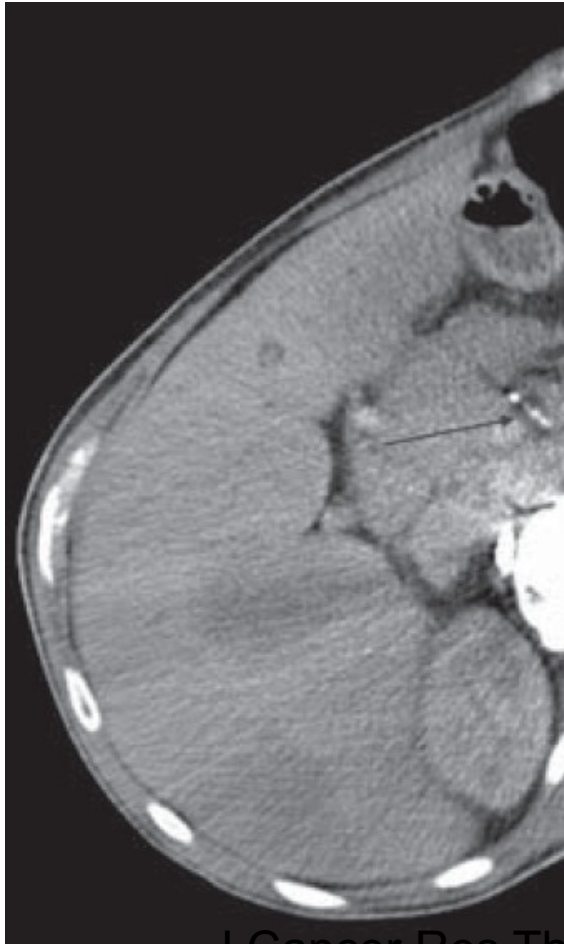


s the  
the aorta  
e  
e celiac  
h rib,  
dle is  
ne exact  
read

Weichowska. Feb 2012

kambadakone A, et al. *Radiographics*. 2011;31(6):1599-621.

# Modality Evolution



Computed tomography guided

J Cancer Res Ther. 2011;7(4):481-3.

# Modality Evolution

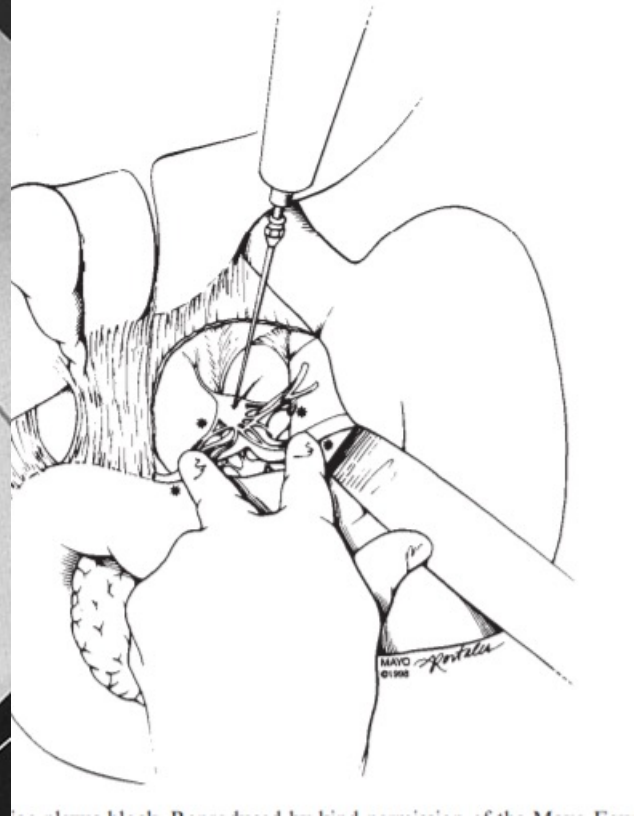
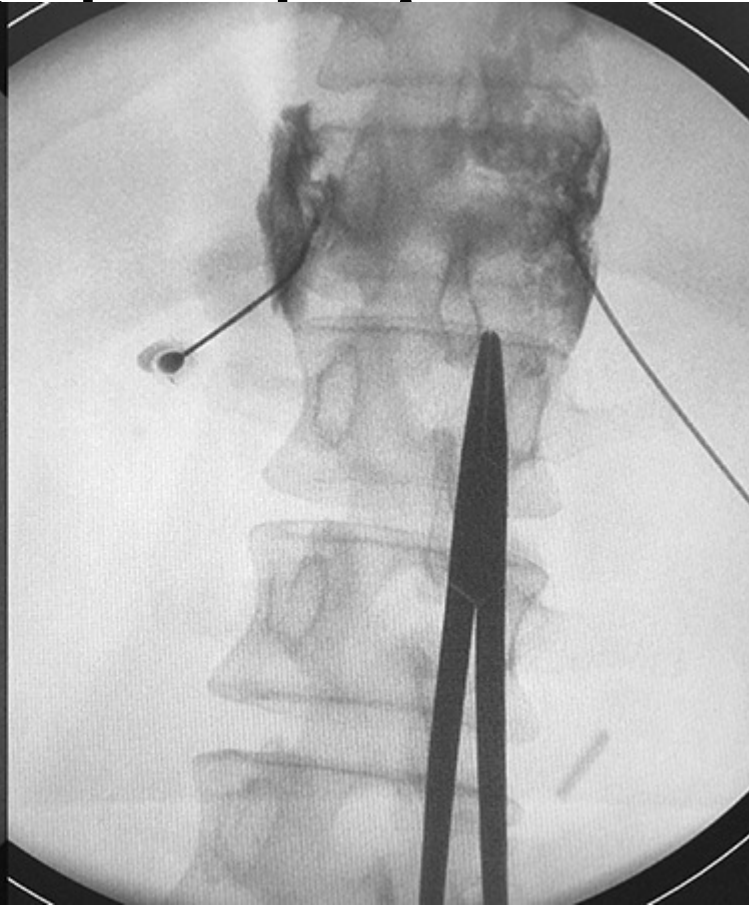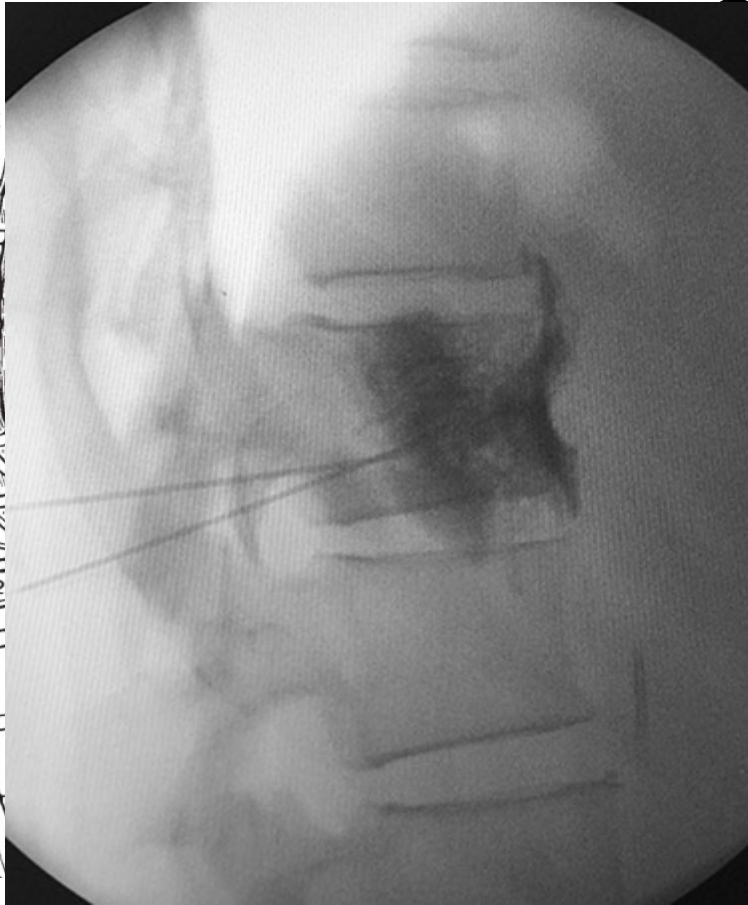
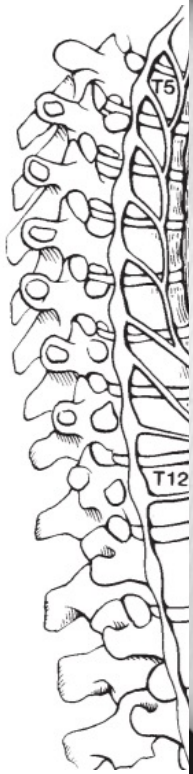## Percutaneous CT-Guided Cryoablation of the Celiac Plexus: A Retrospective Cohort Comparison with Ethanol

Keywan Behbahani<sup>1</sup>, Aron Chary<sup>2</sup>, Sajal Patel<sup>3</sup>, Jason W Mitchell<sup>4</sup>, Howard Fleishon<sup>2</sup>, J David Prologo<sup>2</sup>

	Cryo	Etoh
N	39	44
GI Sx	4 (2 n/v, 2 diarrhea)	12 (4 n/v, 9 diarrhea)

J Vasc Interv Radiol. 2020;31(8):1216-1220.

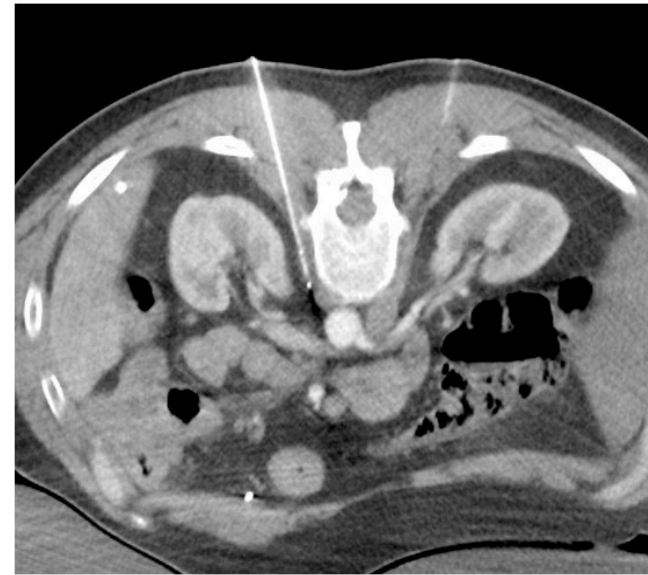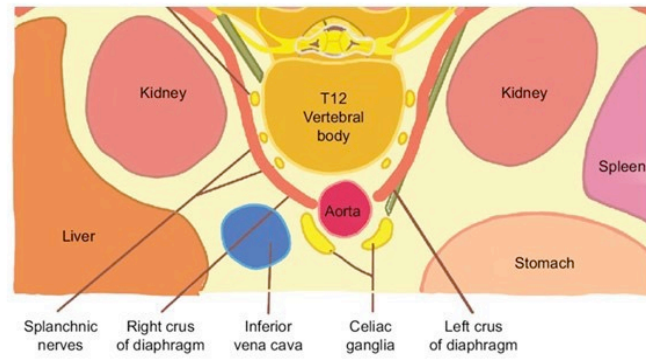




Sakorafas GH, et al. European Journal of Surgical  
Oncology 1999; 25: 427–431

# Splanchnics

10  
3  
3  
3





# Questions?

